

Supplementary Figure 1

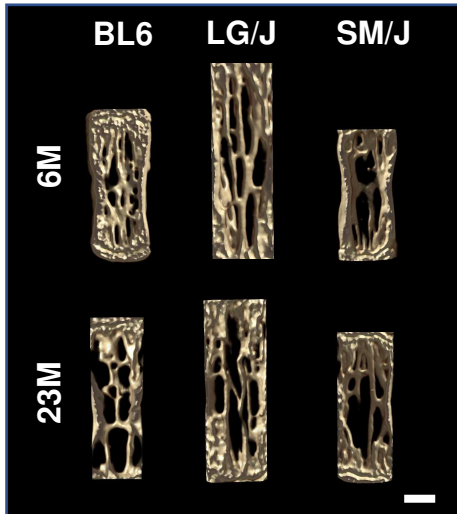
A

23-Month-old Mice

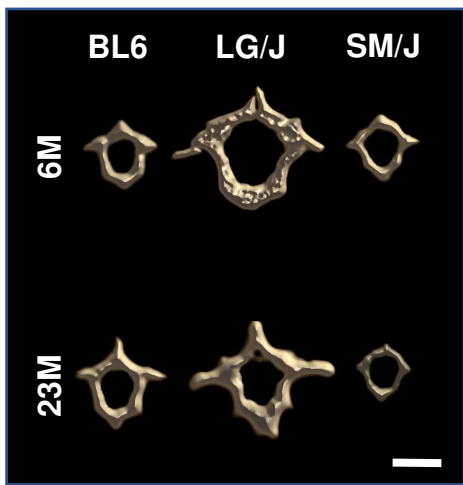
BL6 LG/J SM/J



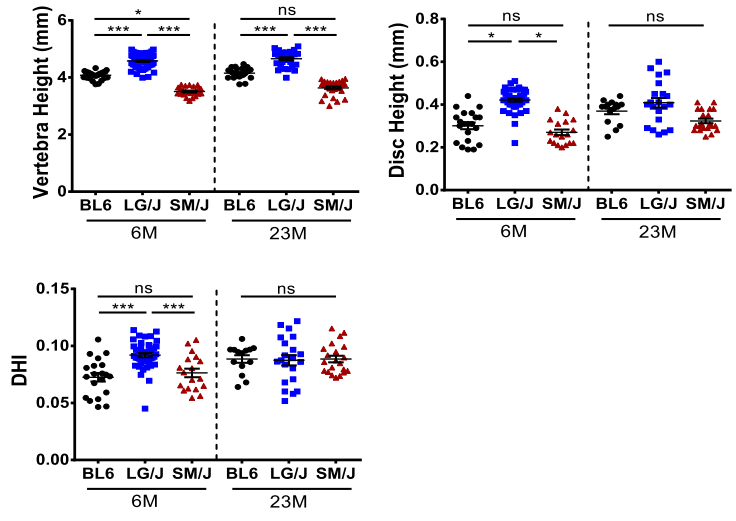
C



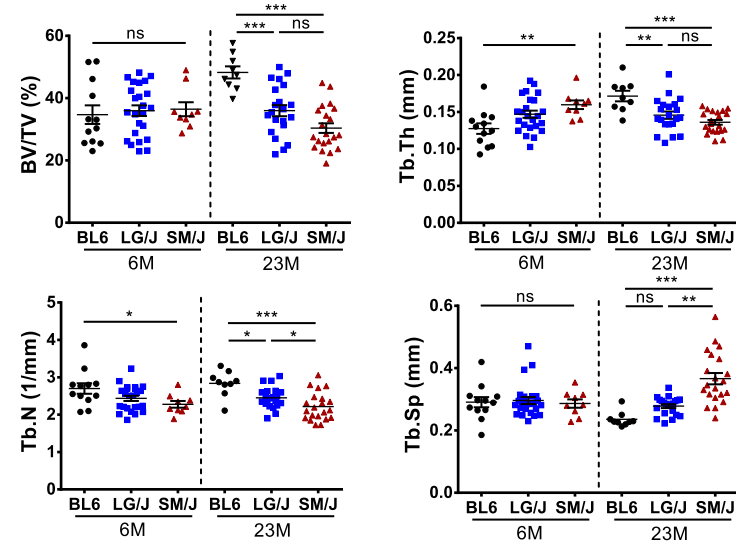
E



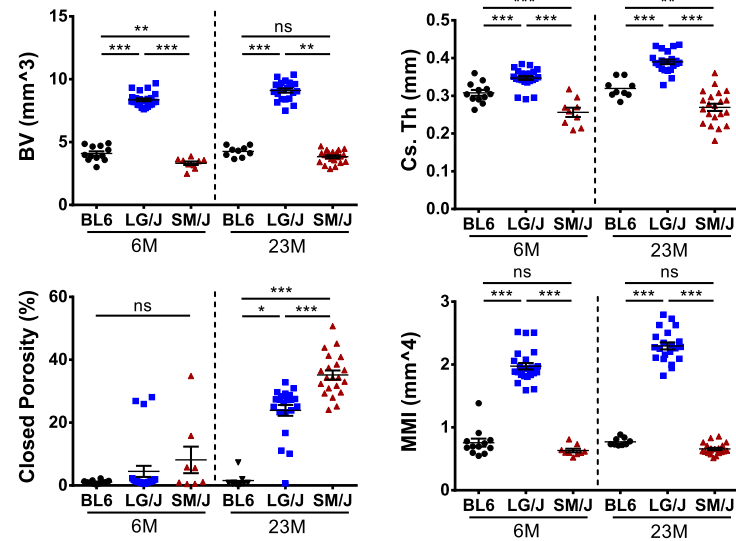
B



D

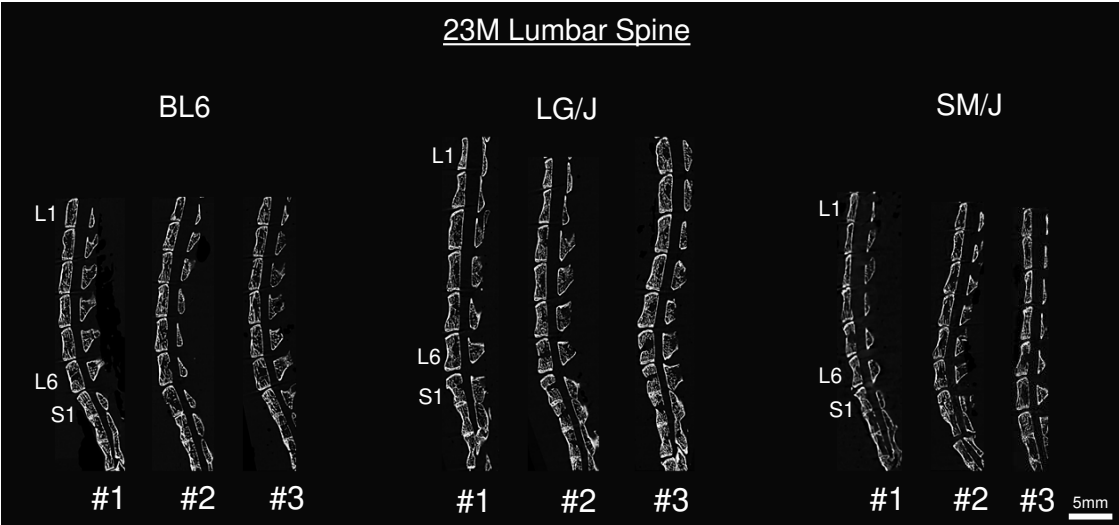


F

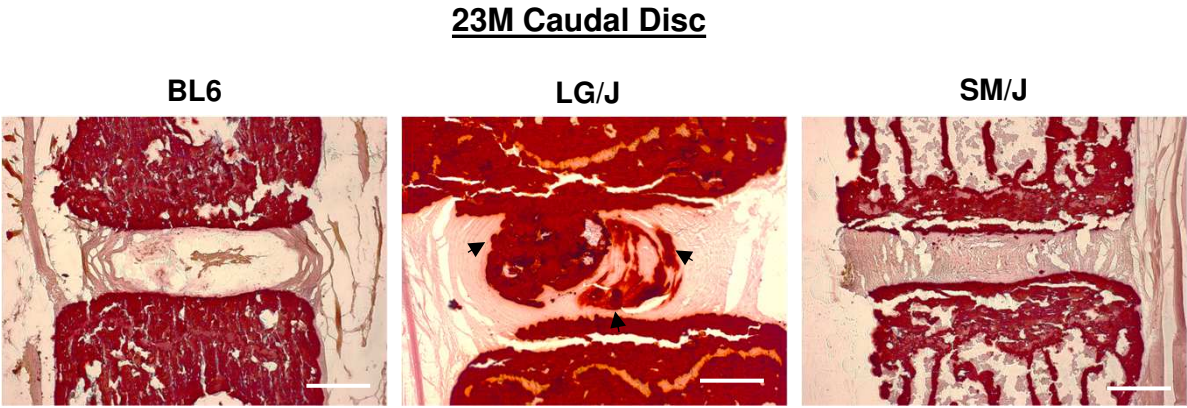


Supplementary Figure 2

A



B



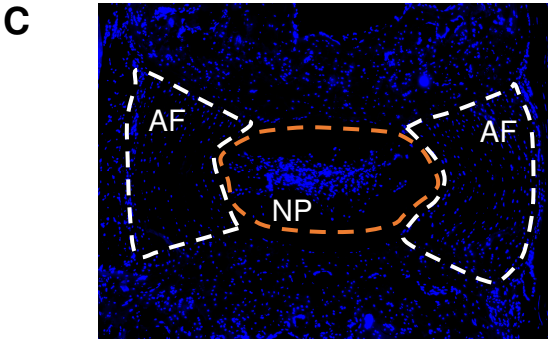
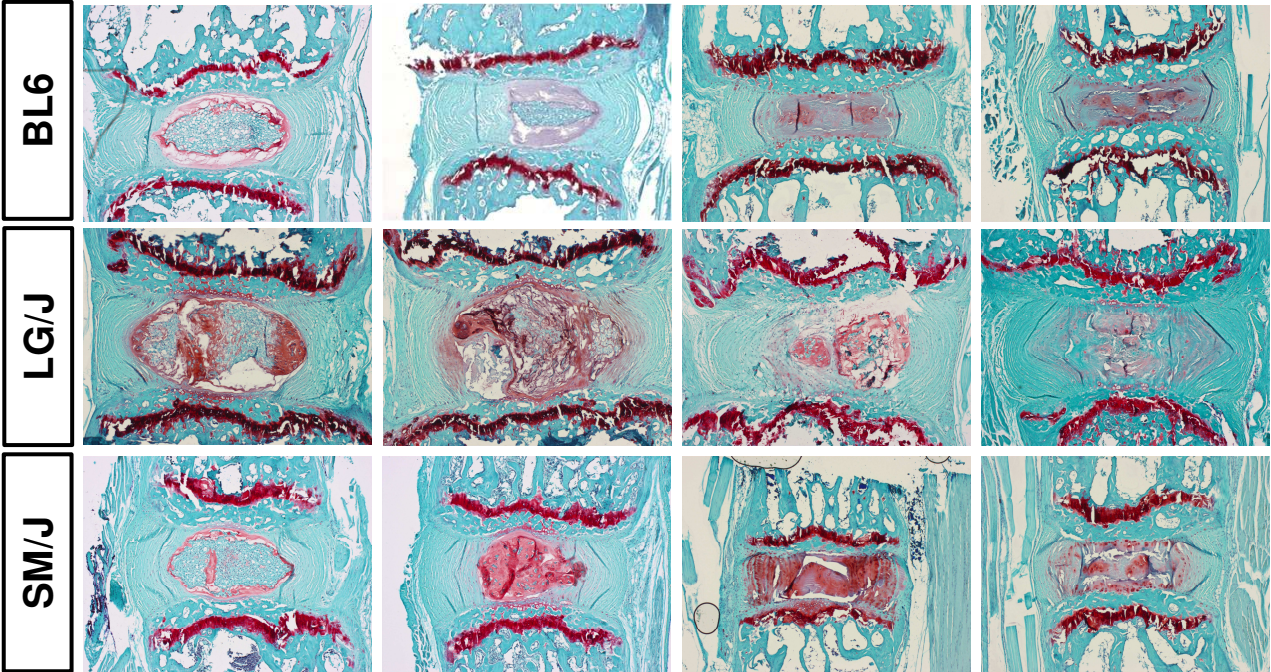
A Modified Thompson Grading

- NP Grading:**
- 1. Aggrecan-rich bulging tissue
 - 2. Peripheral fibrous tissue
 - 3. Consolidated fibrous tissue
 - 4. Horizontal clefts parallel to endplate
 - 5. Clefts through NP and AF (herniation)

- AF Grading:**
- 1. Discrete fibrous lamellae
 - 2. Mucinous material between lamellae
 - 3. Extensive mucinous material and/or loss of NP-AF demarcation
 - 4. Focal clefts
 - 5. Clefts through NP and AF (herniation)

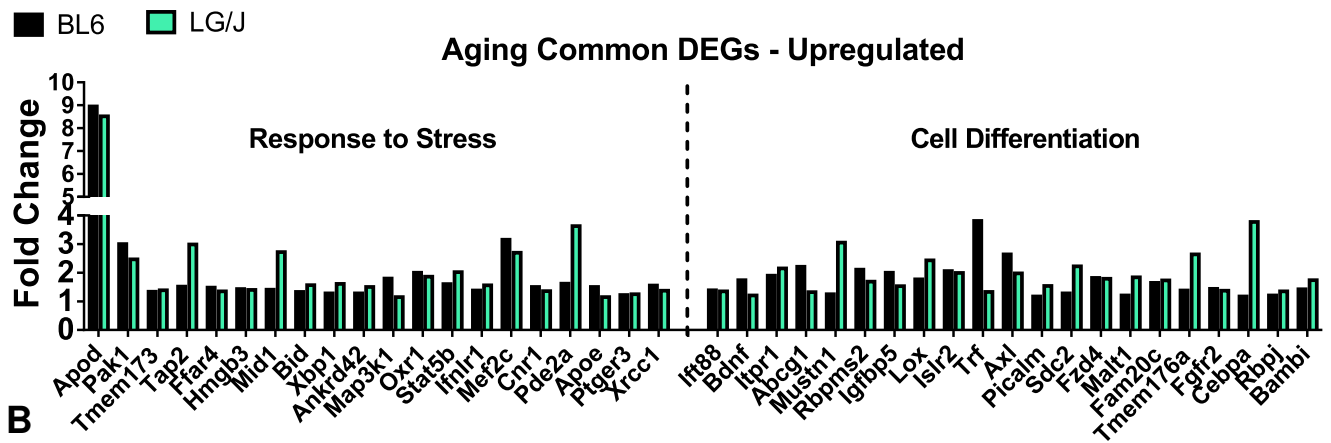
B 23 MONTH HISTOLOGY

IVD Degeneration

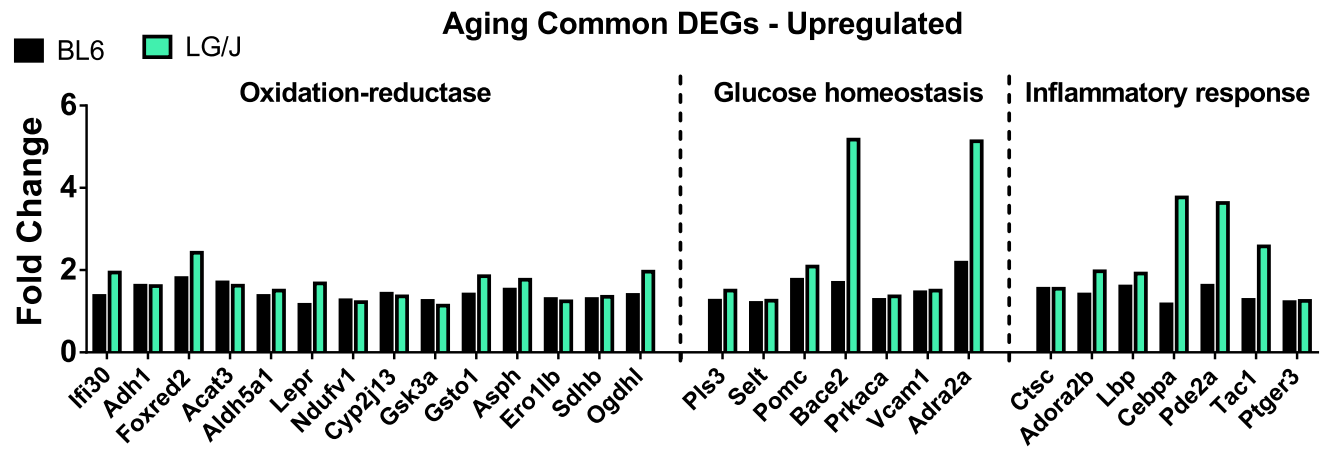


Supplementary Figure 4

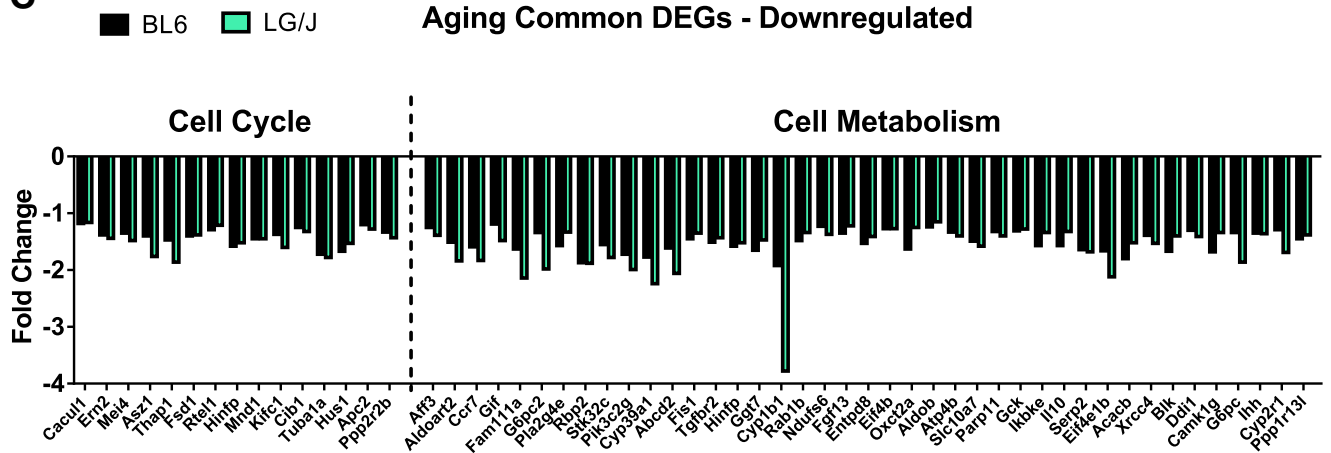
A



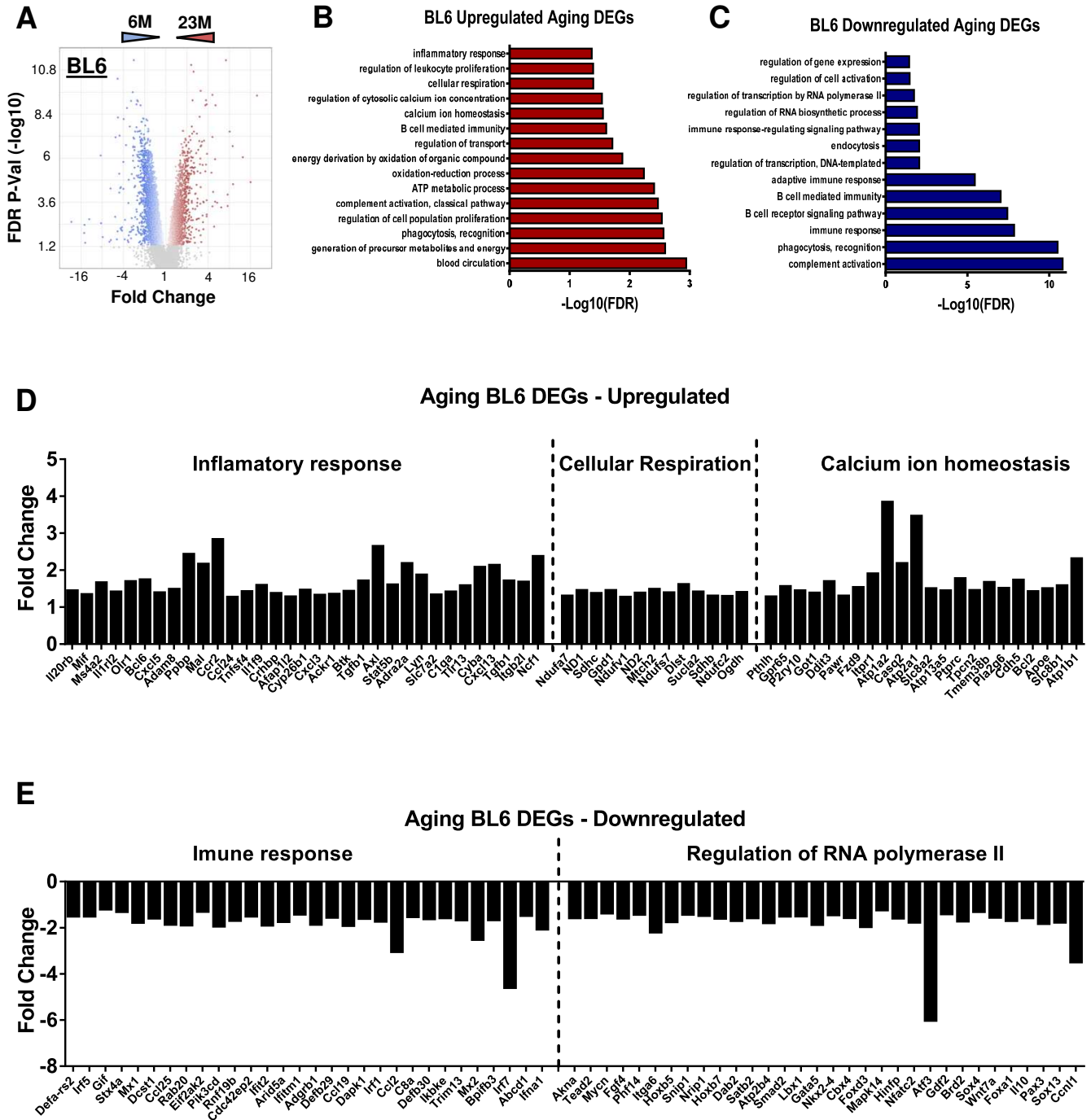
B



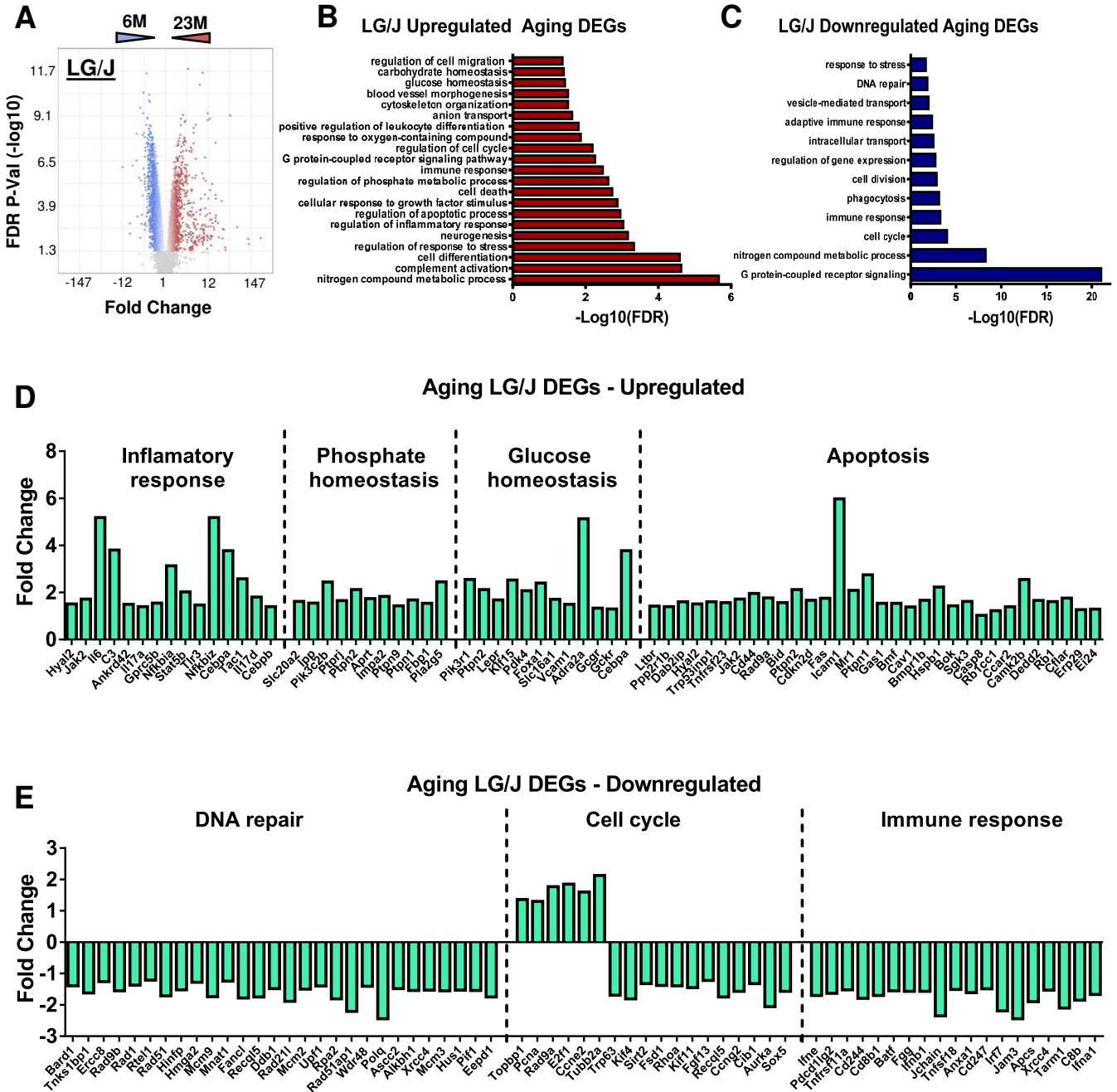
C



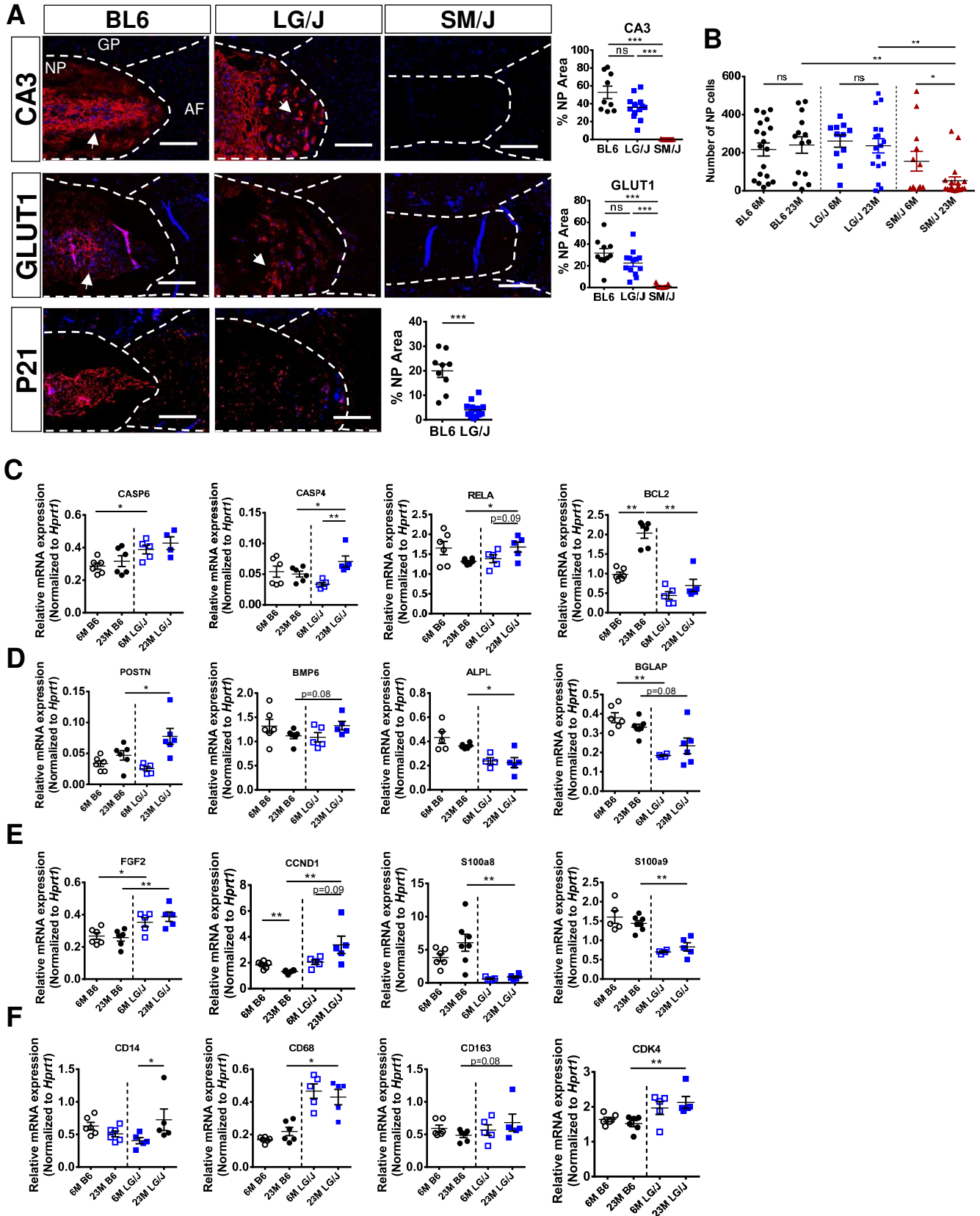
Supplementary Figure 5



Supplementary Figure 6

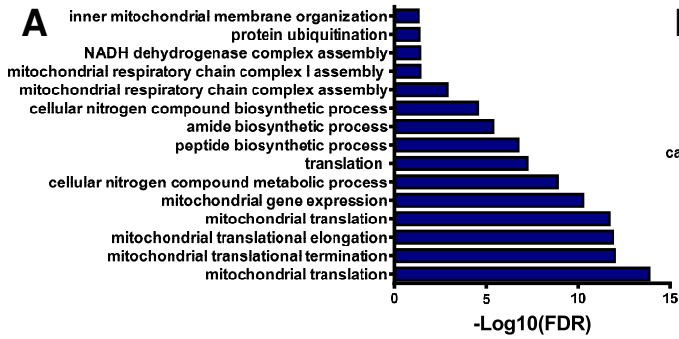


Supplementary Figure 7

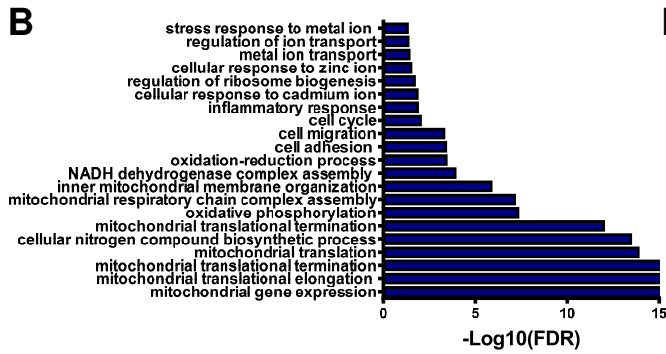


Supplementary Figure 8

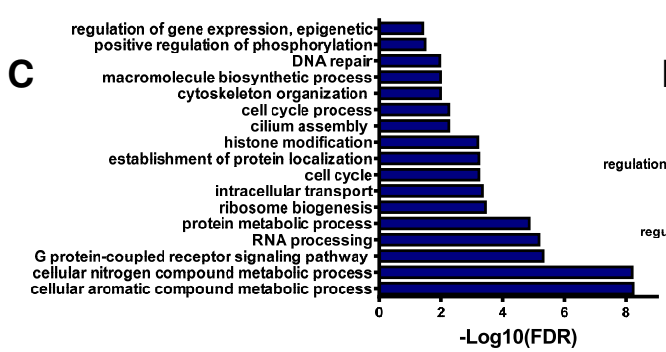
Downregulated GO Human Cluster 4



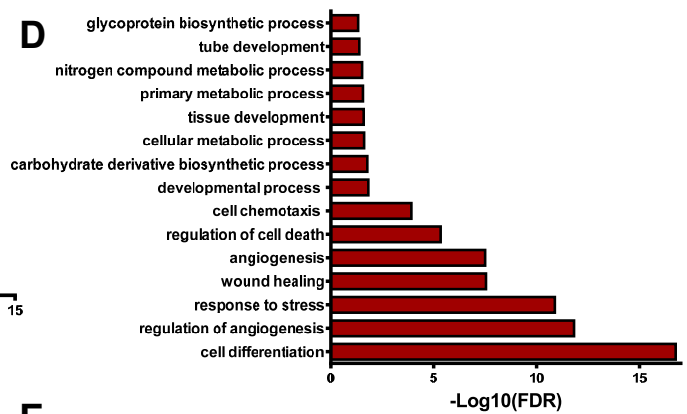
Downregulated GO Human Cluster 5



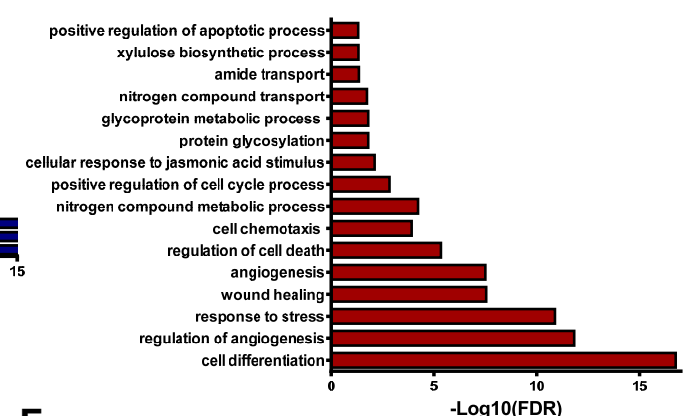
Downregulated GO Human Cluster 6



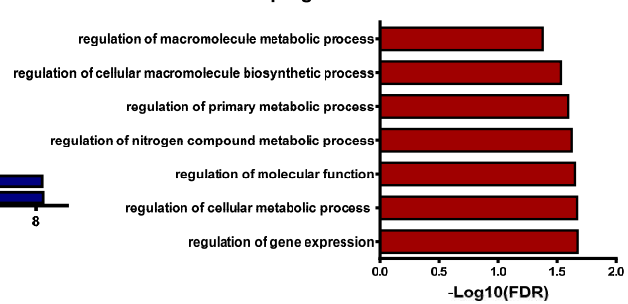
Upregulated GO Human Cluster 2



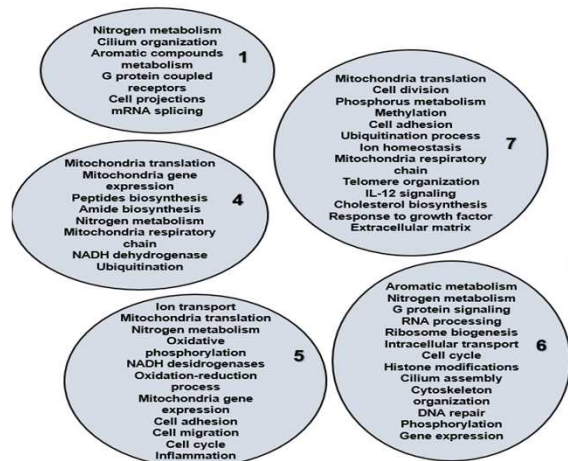
Upregulated GO Human Cluster 3



Upregulated GO Human Cluster 5



G Downregulated Clusters



Upregulated Clusters

