

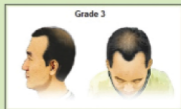


After remove X100 light delivery cap from Camera and take the whole of head like a right picture.

Alopecia

Hair Loss Type

- No Alopecia
 Typical Alopecia Alopecia in Crown Area Alopecia in Frontal Area



more hairy stage is genetic, anagenetic, anaplastic hair regrowth.
 Two sides of the triangular hairlines between the frontal and temporal areas have receded deeper, exceeding 2 cm ahead of coronal plane between the external auditory

Description



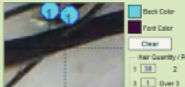
Install X100 cap in Camera (Installed X100 lens)

Scalp Analysis

Hair Intensity Analysis

Unit Size: [3.7mm X 2.8mm]

Zoom 200%



Number of Normal Hair: More than 5.

Image 1: 0

Image 2: 57

Image 3: 0

Image 4: 0

The average number of your hairs 57 Number

Reference Images for Hair Scalp Type

Reference

Reference Images for Pore Status

- Very clean
 Clean but needs some cares
 Needs a regular treatment
 Needs an intensive treatment
 Needs a professional advice and treatment

Save

Total Results

Close



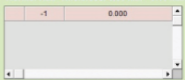Install X400 cap in Camera (Installed X400 lens)

Hair Analysis

Hair Thickness Measurement

 400x 600x

Normal Hair Thickness: 0.05 mm - 0.15 mm



Average Hair Thickness: 0 mm

Reference Images for Hair Type

Reference

Reference Images for Cuticle Status

- Very healthy
 Healthy but needs some cares
 Needs a regular treatment
 Needs an intensive treatment
 Needs a professional advice and treatment

Save

Total Results

Close

