

THE LANCET

Supplementary appendix

This appendix formed part of the original submission. We post it as supplied by the authors.

Supplement to: Kirschenbaum D, Imbach LL, Ulrich S, et al. Inflammatory olfactory neuropathy in two patients with COVID-19. *Lancet* 2020; published online July 10. [http://dx.doi.org/10.1016/S0140-6736\(20\)31525-7](http://dx.doi.org/10.1016/S0140-6736(20)31525-7).

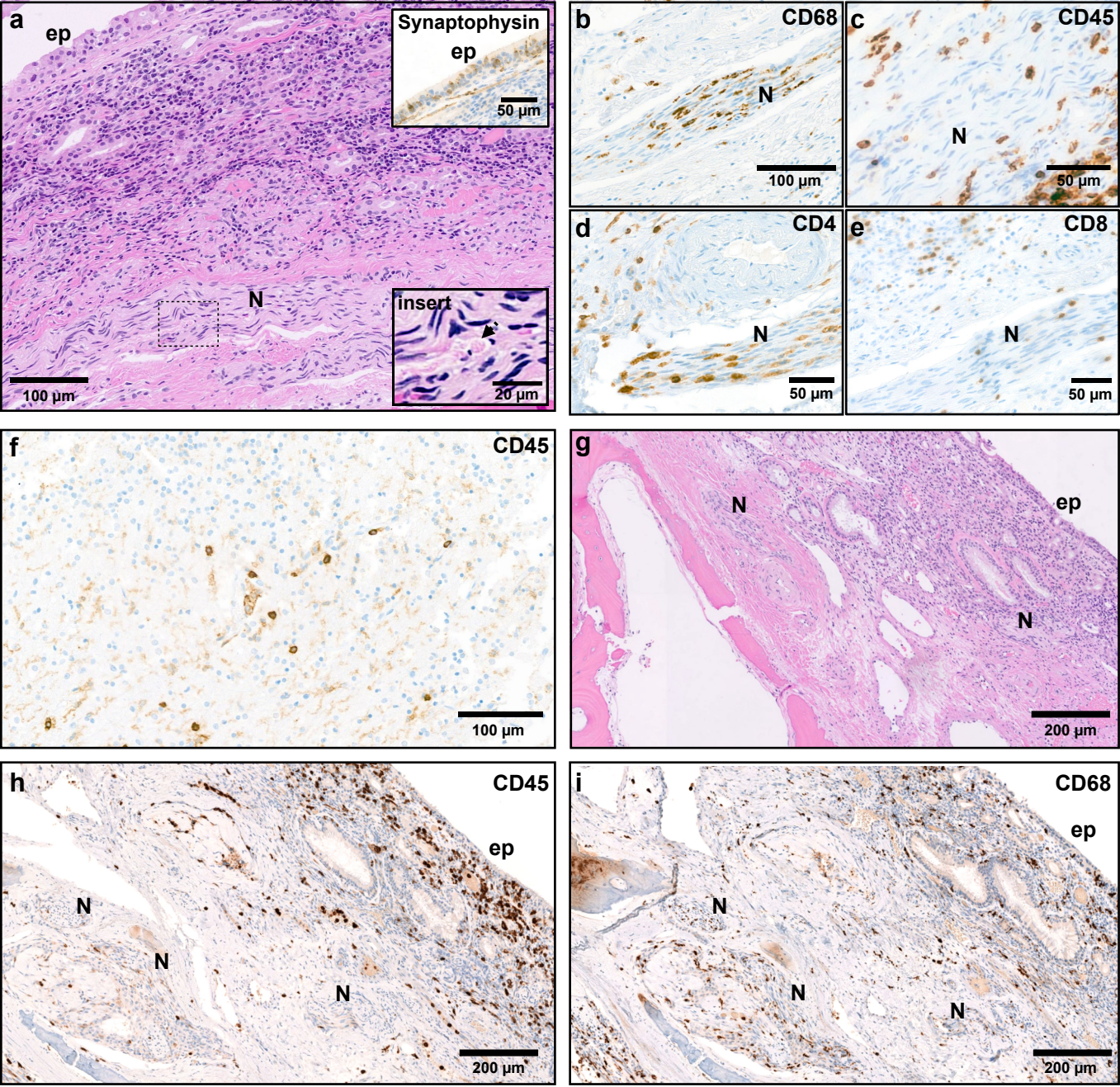


Figure 1. The histological workup of olfactory epithelium from patient 1 (panels a-f) and patient 2 (panels g-i). Olfactory epithelium is depicted in all panels except (f) = olfactory tract. Close up of olfactory fila from patient 1 is shown in subpanels (b-e). ep = epithelium of olfactory mucosa, N = nerve, arrow in Figure 1a (insert) = digestion chamber.