

Supplemental Figure for:
Successful Treatment of Cytokine Release Syndrome with IL-6 Blockade in a Patient Transitioning from Immune-Checkpoint to MEK/BRAF Inhibition: A Case Report and Review of Literature
Clare Barber et al.

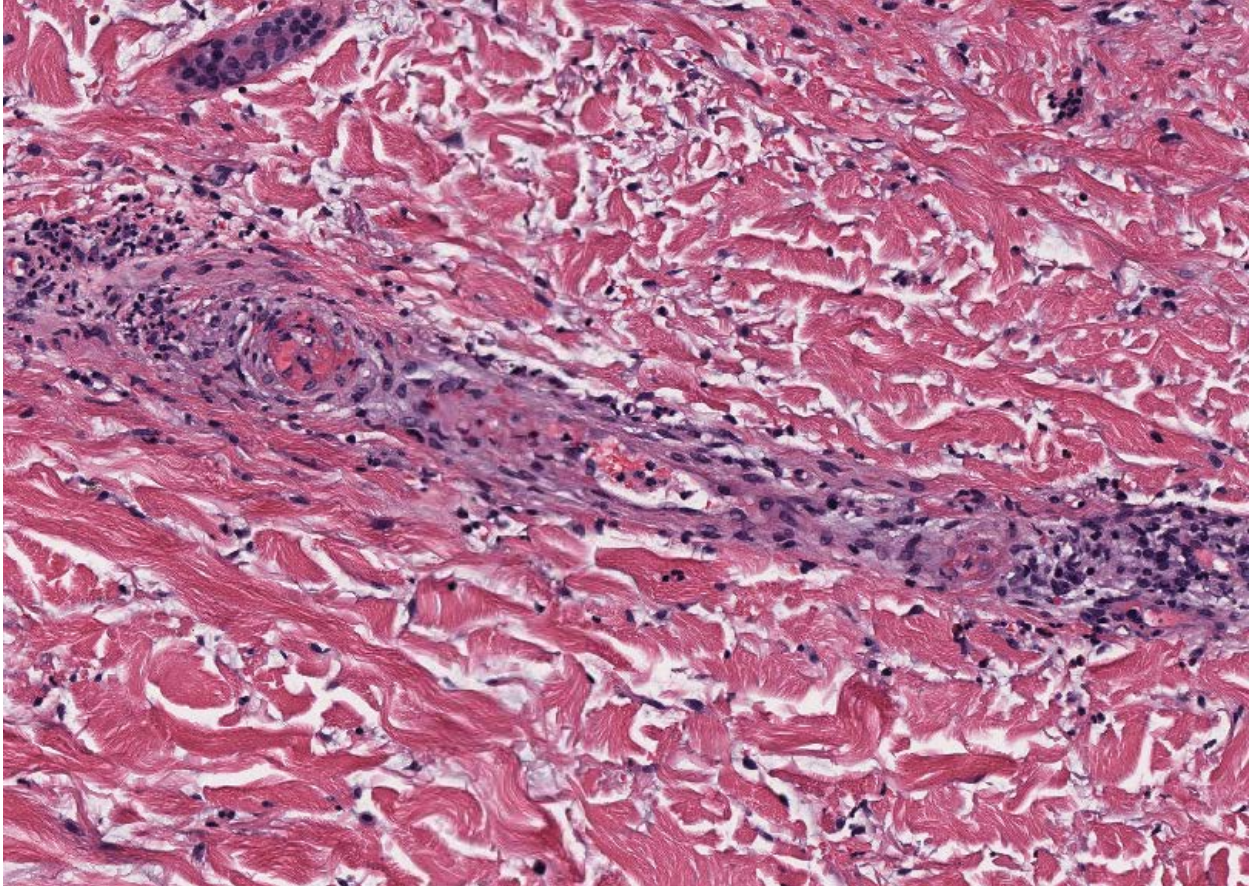


Figure S1. Skin biopsy, Hematoxylin & eosin @ 100x magnification. Mid- dermal, small, thin-walled vessels demonstrate fibrinoid necrosis of their walls with occasional intraluminal fibrin thrombi. These changes are in keeping with vascular damage and coagulopathy.