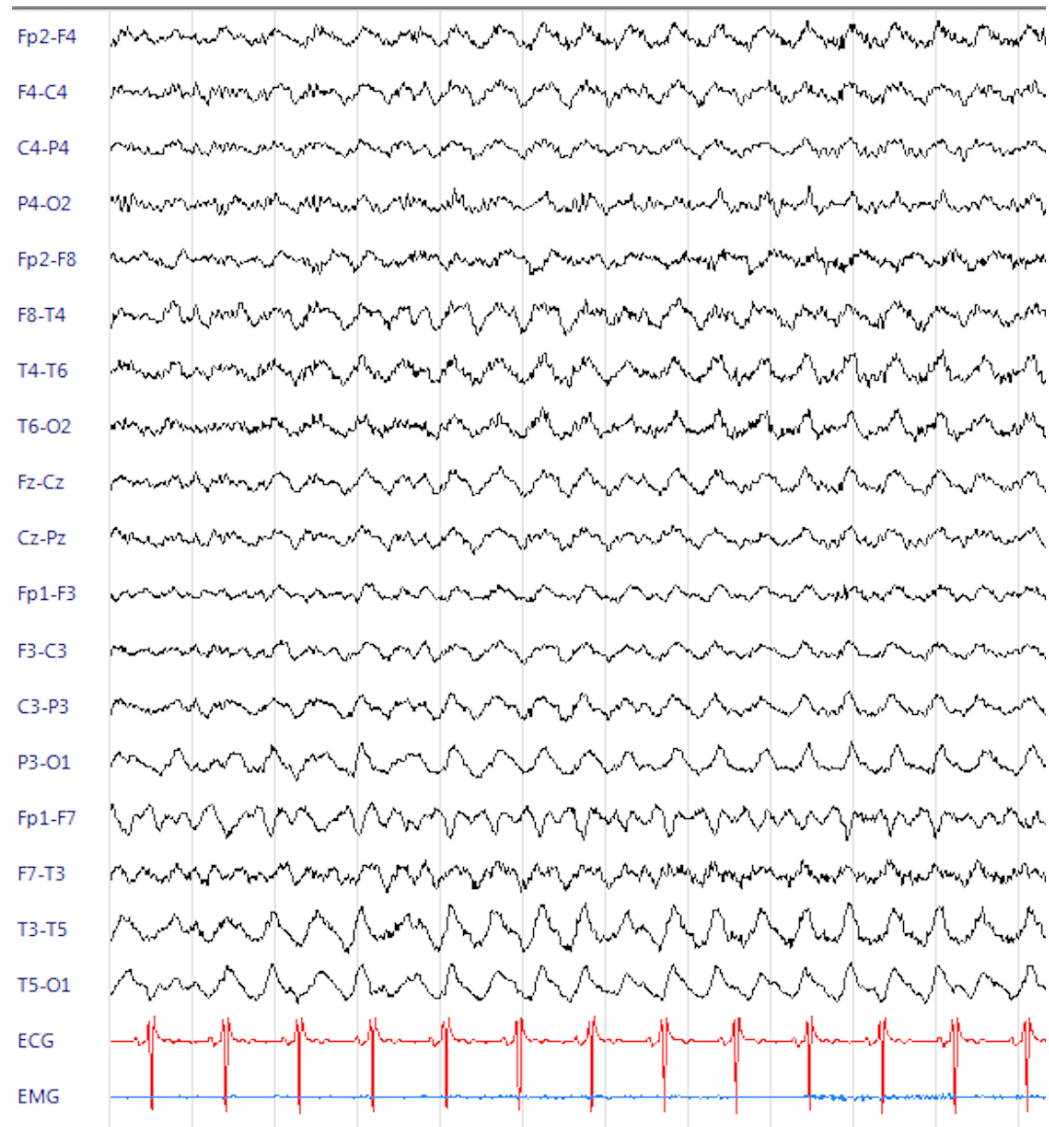
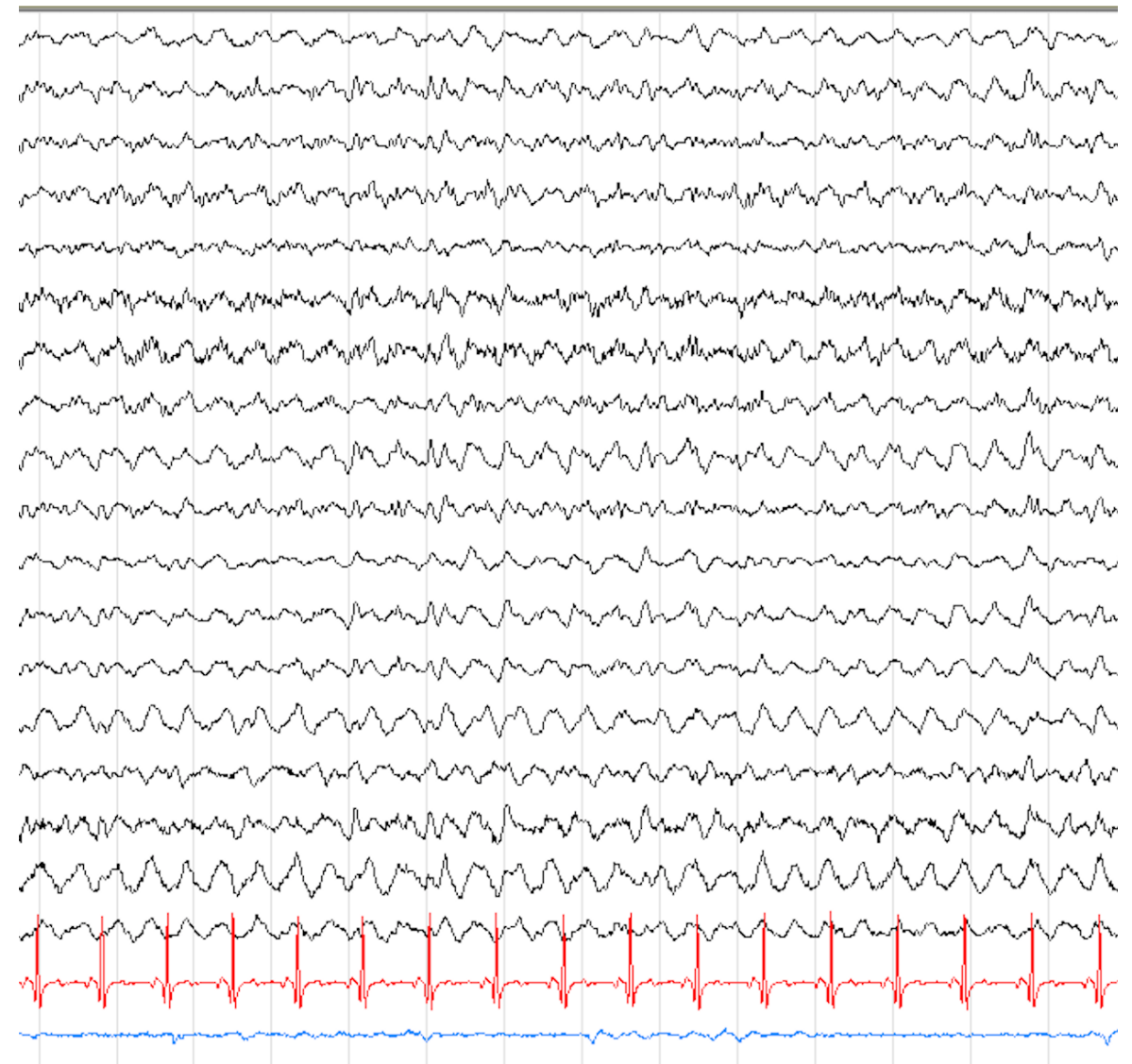


A

Day 10 from clinical onset

**B**

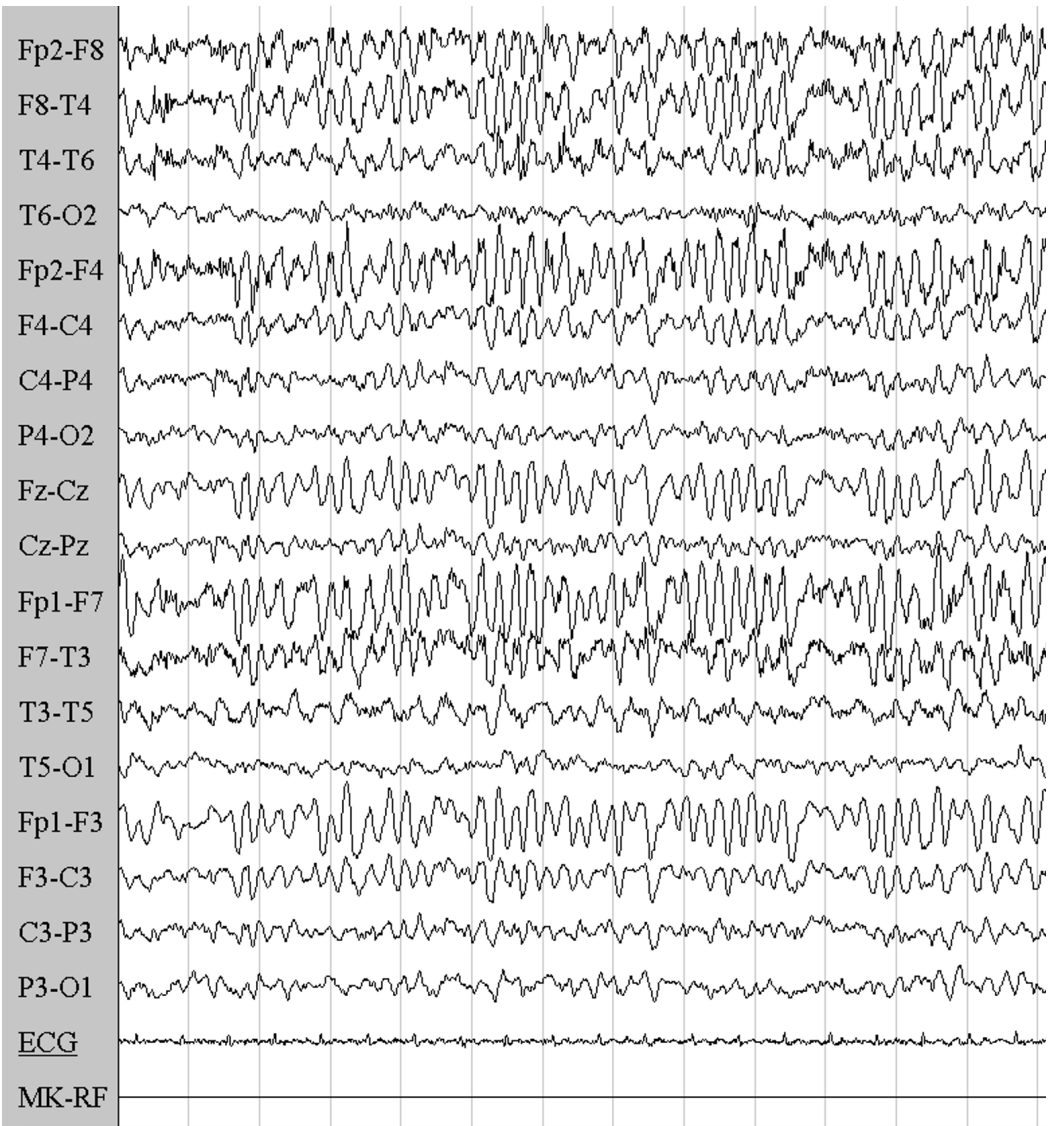
Day 20 from clinical onset



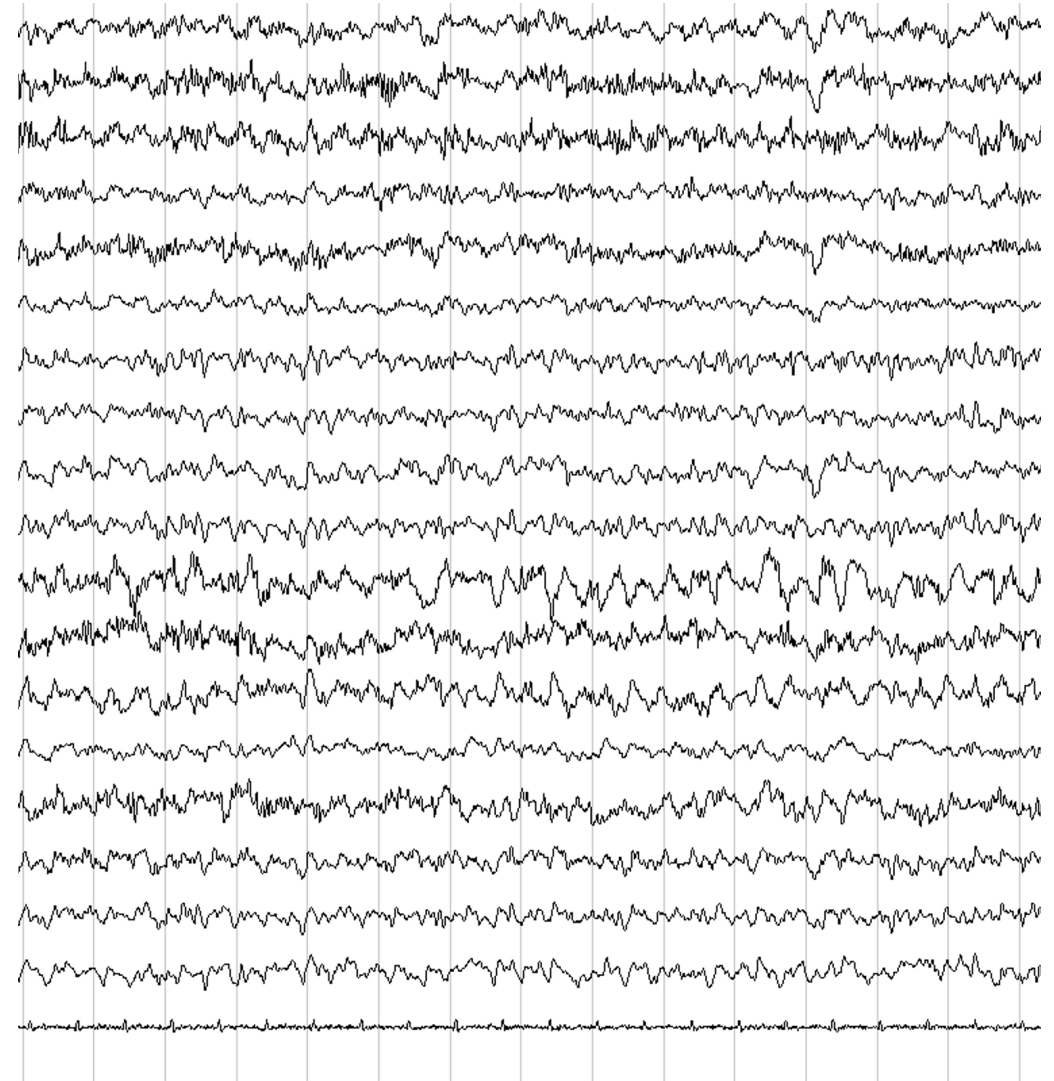
TC= 0.3; 5 uv/mm; low-pass filter= 30 Hz

C

Day 39 from clinical onset

**D**

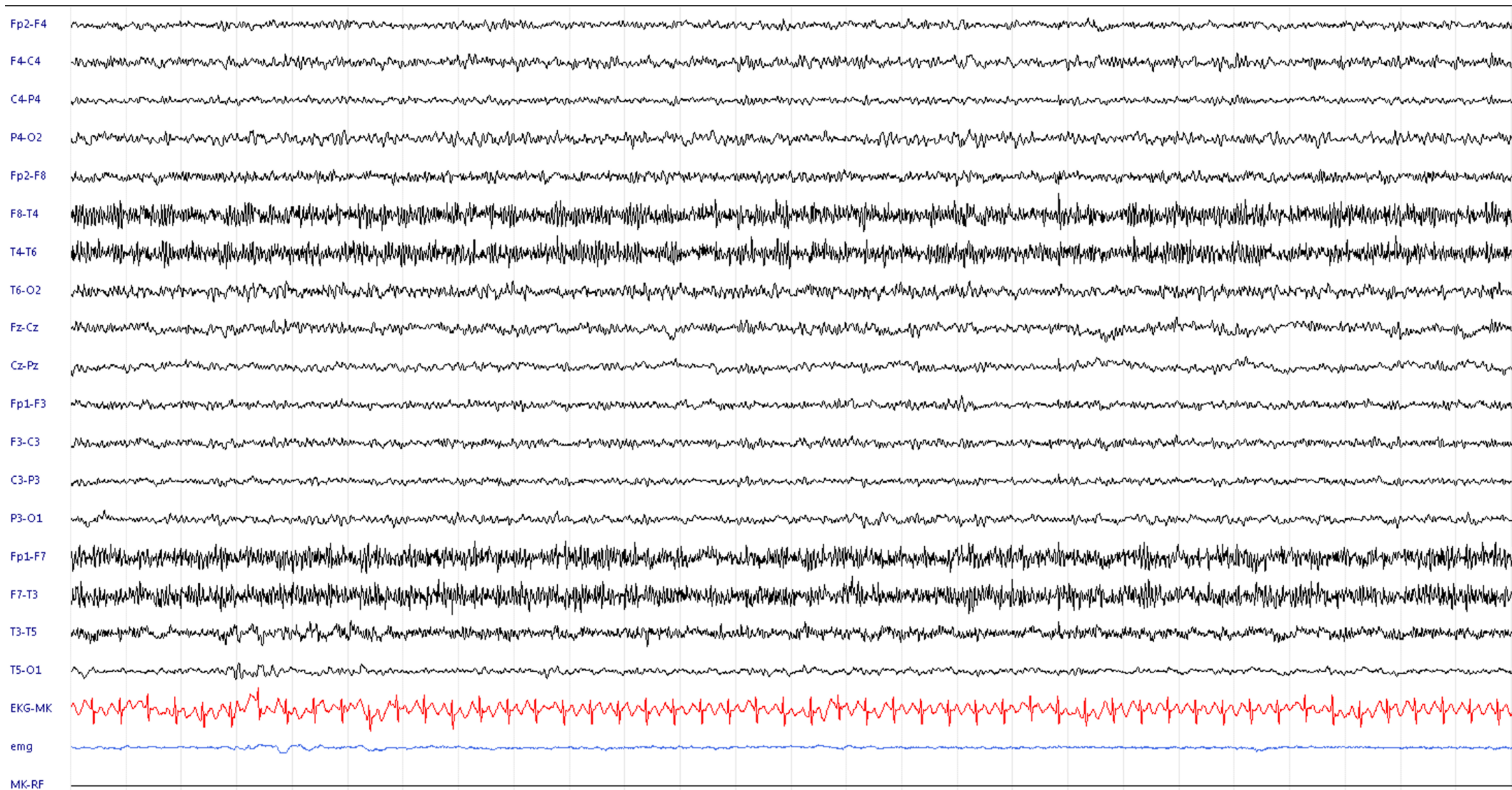
Day 43 from clinical onset



TC= 0.3; 5 uv/mm; low-pass filter= 30 Hz

E

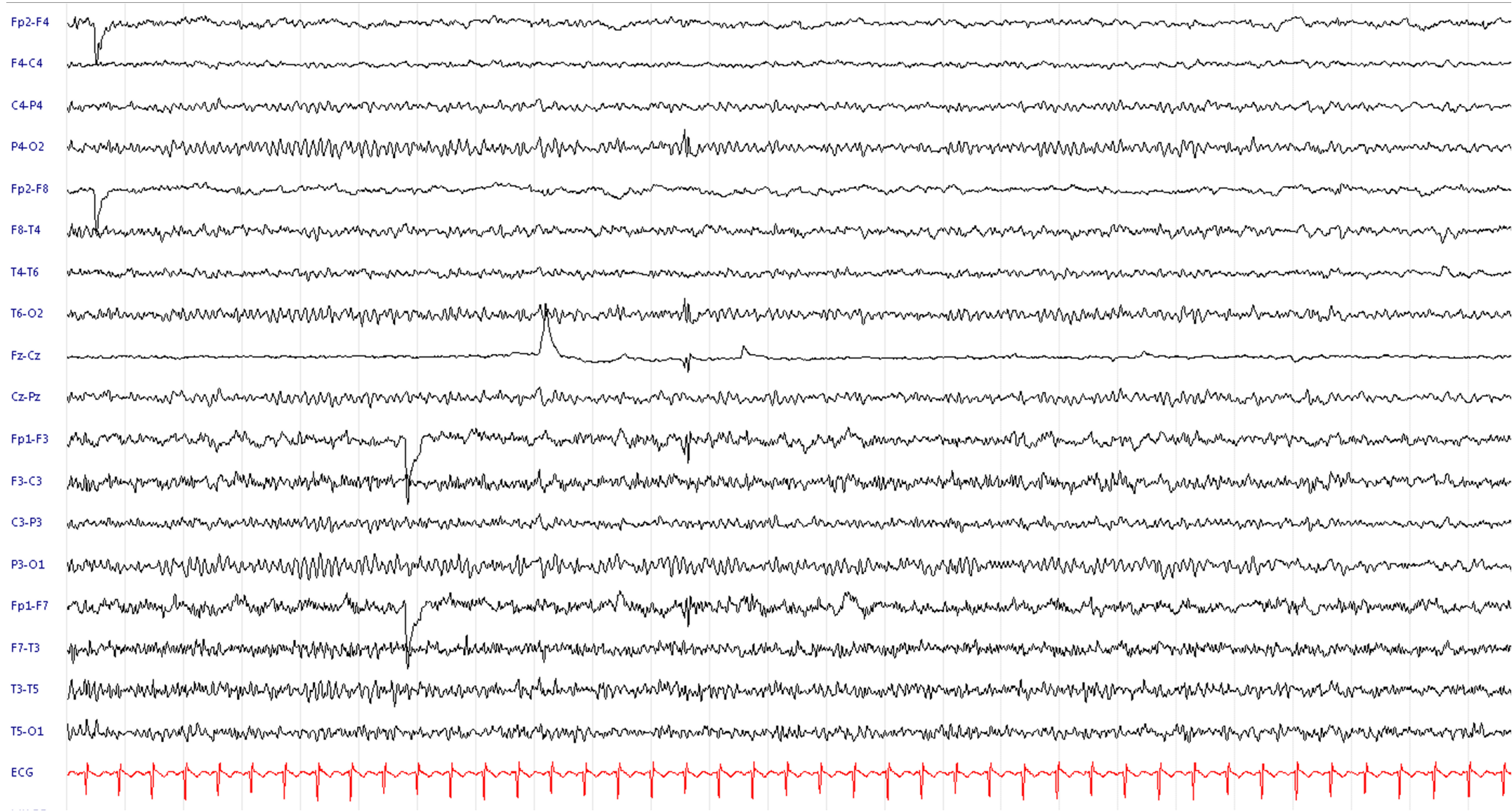
Day 51 from clinical onset



TC= 0.3; 5 uv/mm; low-pass filter= 30 Hz

F

Day 51 from clinical onset



TC= 0.3; 5 uv/mm; low-pass filter= 30 Hz

EEG evolution

Figure legend:

The EEG evolution of the condition is reported starting from diffuse delta activity (**A** and **B**) featuring a “delta brush pattern”. In **C** anterior sub-continuous periodic theta activity is observed. Then an irregular non periodic EEG slowing is reported in **D**, an organized EEG is reappearing (**E**) with 7-8 posterior dominant rhythm in the right hemisphere, **F** symmetric posterior alpha rhythm reappeared.