

Incomplete Kawasaki Disease in a Child with COVID-19

We report a case of incomplete Kawasaki disease in a child who also tested positive for COVID-19. This case brings attention to the diverse presentation of coronavirus disease (COVID-19) disease in children.

A 5-year-old previously healthy African American male was admitted to the Pediatric inpatient floor with daily fever up to 39.4°C for 8 days. He had a history of rash, swelling (palms and soles), conjunctivitis, decreased appetite, diarrhea, dysuria, and abdominal pain. He had been treated with cefdinir for positive rapid streptococcal antigen test four days before, without clinical improvement. Physical examination showed dry, cracked, erythematous lips, non-exudative conjunctivitis, and bilateral shotty cervical lymphadenopathy but no rash. He had right scrotal edema and hydrocele suggestive of epididymo-orchitis on ultrasound. Clinically, he met the criteria for incomplete Kawasaki disease (KD).

Initial laboratory workup was significant for leukocytosis (white blood cells 40,000/cumm), anemia

(hemoglobin 8 g/dL), thrombocytopenia (platelet count 104,000/cumm), elevated inflammatory markers (ESR 72 mm, CRP 25.6 mg/dL, procalcitonin 27 ng/mL, ferritin 1030 ng/mL), hyponatremia (serum sodium 121 meq/L), pyuria, hypoalbuminemia (2 g/dL), elevated liver enzymes (ALT 55 U/L), elevated troponins (0.06 ng/mL) and negative rapid influenza A/B antigens. Chest X-ray showed an enlarged cardiac silhouette (**Fig. 1**). Severe acute respiratory syndrome coronavirus 2 (SARS-CoV-2) RNA was detected on RT-PCR from his nasopharyngeal swab. Echocardiogram showed a small global pericardial effusion but no ectasia, dilation, or aneurysm formation of coronary arteries (**Fig. 2**).

He was transferred to the pediatric intensive care unit because of hypotension. He received fluid boluses and intravenous immunoglobulin (IVIG) therapy was begun, which had to be discontinued because of recurring hypotension. He was briefly supported with high flow nasal cannula up to 10 liter for tachypnea and increased work of breathing, which was weaned-off. Once he was hemodynamically stable, IVIG infusion was resumed slowly at 5 grams over 10 hours (2-5 mL/minute) for 6 doses for a total dose of 30 grams (1.8 g/kg) [1] with a

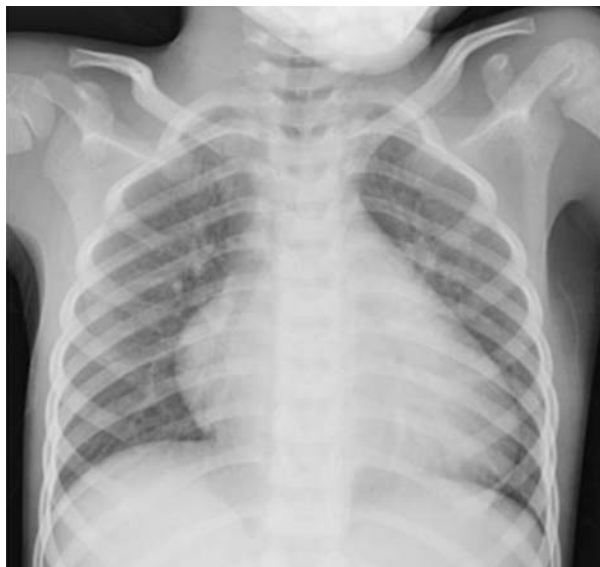

Fig.1 Chest radiograph showing enlarged cardiac silhouette.

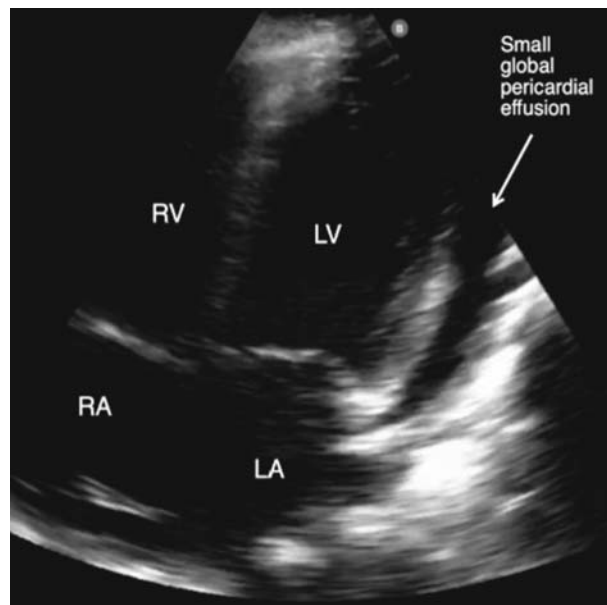


Fig. 2 Apical four chamber view of a two dimensional echocardiogram of the patient showing a small global pericardial effusion. LA-Left Atrium; LV-Left ventricle; RA-Right atrium; RV-Right ventricle.

different formulation, after pre-medicating with diphenhydramine and methylprednisolone (only for the first dose) and started on medium-dose aspirin (~39 g/kg/day).

The patient recovered on the pediatric floor with supportive therapy for COVID-19 [3] and was discharged after 6 days in the hospital. Hypotension with elevated inflammatory markers in patients with KD are the manifestations of KD shock syndrome (KDSS) [4]. Association between COVID-19 and KDSS [5] has been speculated, but warrants further investigation.

Adverse effects to IVIG infusion commonly include hypotension and anaphylactic reactions. This can be treated with steroids and antihistamines as pre-medication. However, there is a weak recommendation regarding avoidance of steroids in patients with COVID-19, with some indirect evidence of disease worsening [2]. Readers need to be aware of co-occurrence of Kawasaki disease with COVID-19, and the associated management issues.

Contributors- ER-drafted the manuscript; RS-supervised ER and edited the manuscript; SS-helped with the echocardiographic images and their labeling; PG-conceived the idea of case report, supervised, edited and finalized the manuscript.

Funding: none; *Competing interests:* None stated.

Published online: May 09, 2020; *PII:* S097475591600179.

ELVIA I RIVERA-FIGUEROA¹, ROBERTO SANTOS²,
SCOTT SIMPSON³ AND PADMA GARG^{1*}

¹*Division of Pediatric Critical Care Medicine,*
²*Division of Pediatric Infectious Disease, and* ³*Division of Pediatric Cardiology, University of Mississippi Medical Center, Jackson, Mississippi, USA.*
*ppgarg@umc.edu

REFERENCES

1. Son MBF, Newburger JW. Kawasaki disease. *Pediatr Rev.* 2018;39:78-90.
2. COVID-19 Treatment Guidelines Panel. Coronavirus Diseases 2019 (COVID-19) Treatment Guidelines. National Institutes of Health. Available from: <https://www.covid19treatmentguidelines.nih.gov/>. Accessed May 8, 2020.
3. Chiotos K, Hayes M, Kimberlin DW, Jones SB, James SH, Pinninti SG, *et al.* Multicenter Initial Guidance on Use of Antivirals for Children With COVID-19/SARS-CoV-2. *J Pediatric Infect Dis Soc.* 2020. Apr 22 [published online ahead of print]. Available from: <https://academic.oup.com/jpids/advance-article/doi/10.1093/jpids/piaa045>. Accessed May 8, 2020.
4. Kanegaye JT, Wilder MS, Molkara D, Frazer JR, Pancheri J, Tremoulet AH, *et al.* Recognition of a Kawasaki disease shock syndrome. *Pediatrics.* 2009;123: e783-9.
5. Jones VG, Mills M, Suarez D, Hogan CA, Yeh D, Bradley Segal J, *et al.* COVID-19 and Kawasaki disease: Novel virus and novel case. *Hosp Pediatr.* 2020 Apr 7. <https://hosppeds.aappublications.org/content/early/2020/04/06/hosppeds.2020-0123.long>. Accessed May 8, 2020.

Hyper-inflammatory Syndrome in a Child With COVID-19 Treated Successfully With Intravenous Immunoglobulin and Tocilizumab

Coronavirus disease (COVID-19) in children appears to be largely a benign condition. However, there are reports of children presenting significantly unwell across Europe and USA in the last couple of weeks with a new multisystem inflammatory syndrome [1]. We report a child with COVID-19 who had overlapping features of Toxic Shock Syndrome (TSS) and Kawasaki disease (KD).

A previously well, eight-year-old boy presented with fever, cough and throat pain. He was admitted to a local hospital on day 4 of illness in view of high-grade fever spikes. Investigations showed neutrophilic leukocytosis (total white blood cell count 23,000/ μ L, Neutrophils 89%) with raised acute phase reactants (C-reactive protein, CRP 120 mg/L). Chest X-ray showed right upper and middle lobe infiltrates. Reverse transcriptase polymerase chain reaction (RT-PCR) for severe acute respiratory illness novel coronavirus 2 (SARS-CoV-2) was negative. Treatment was empirically started with ceftriaxone and azithromycin. Despite treatment for three days, he continued to have high fever, worsening respiratory symptoms and was referred to our hospital.

On arrival, he was alert, had respiratory rate of 50/min, intercostal retractions and was maintaining SpO₂ in room air. He was febrile with tachycardia (HR 160/min), hypotension (80/31 mm Hg), warm extremities and a capillary refill time of 3 seconds. He was also noted to