

a

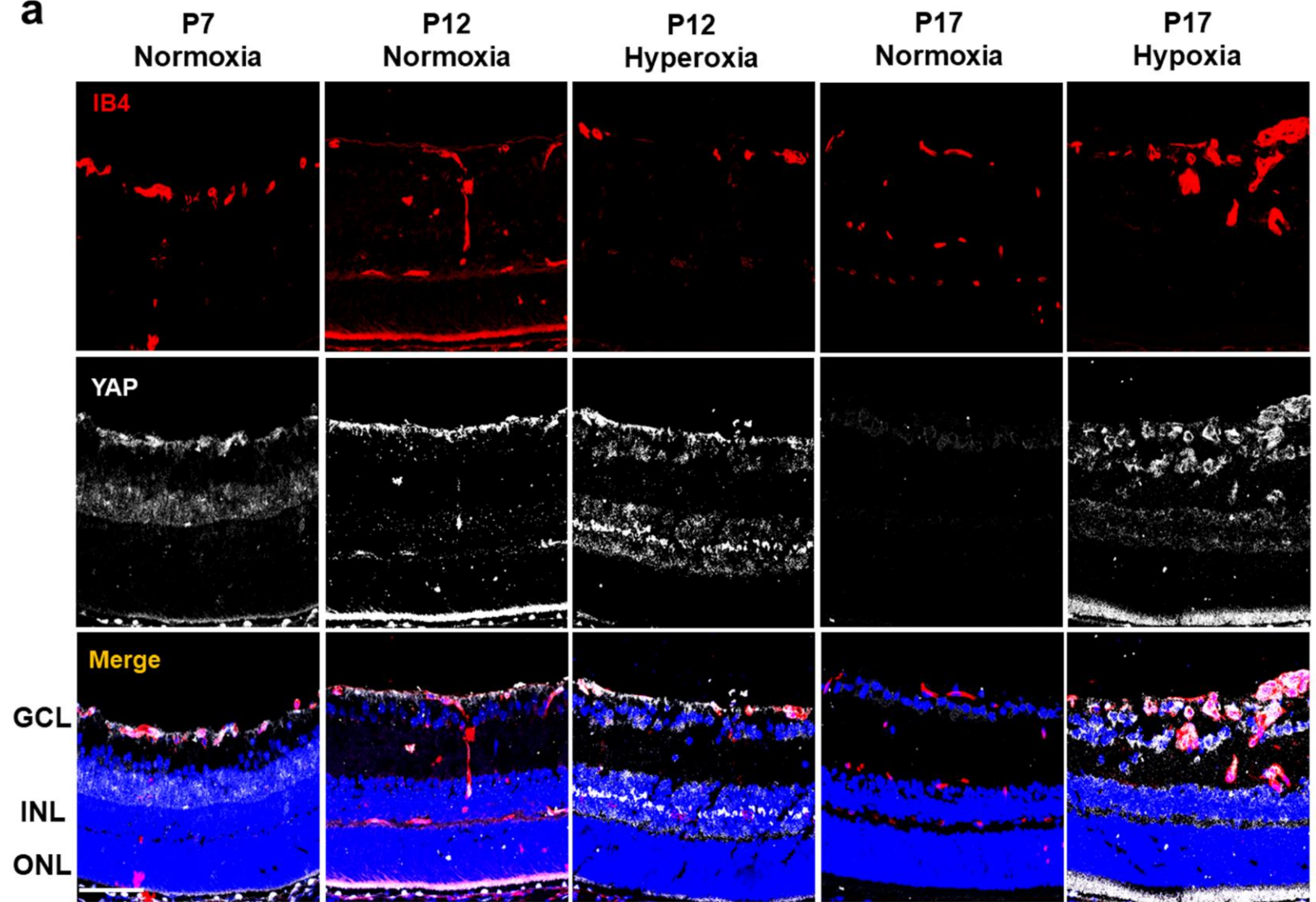


Figure S1

(a) Confocal immunofluorescence images of retinal cross-sections stained for IB4 (red) and YAP (gray) during development and in oxygen-induced retinopathy. YAP was mainly colocalized with IB4 on the superficial vascular plexus and to a lesser extent in the inner nuclear layer in normoxia phases (P7, P12, P17) and in both the hyperoxia and hypoxia phases (n=3). Bar = 20 μm .