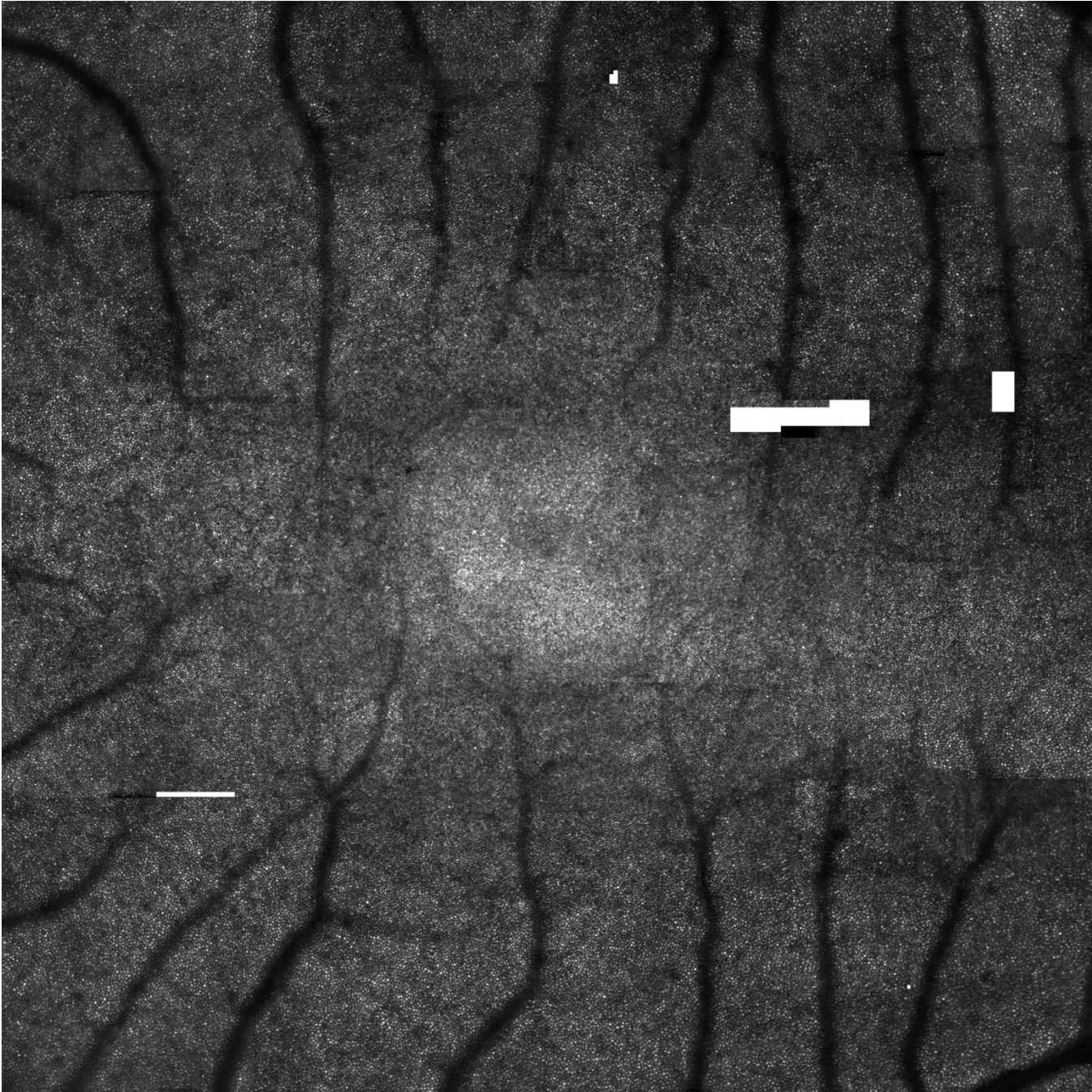
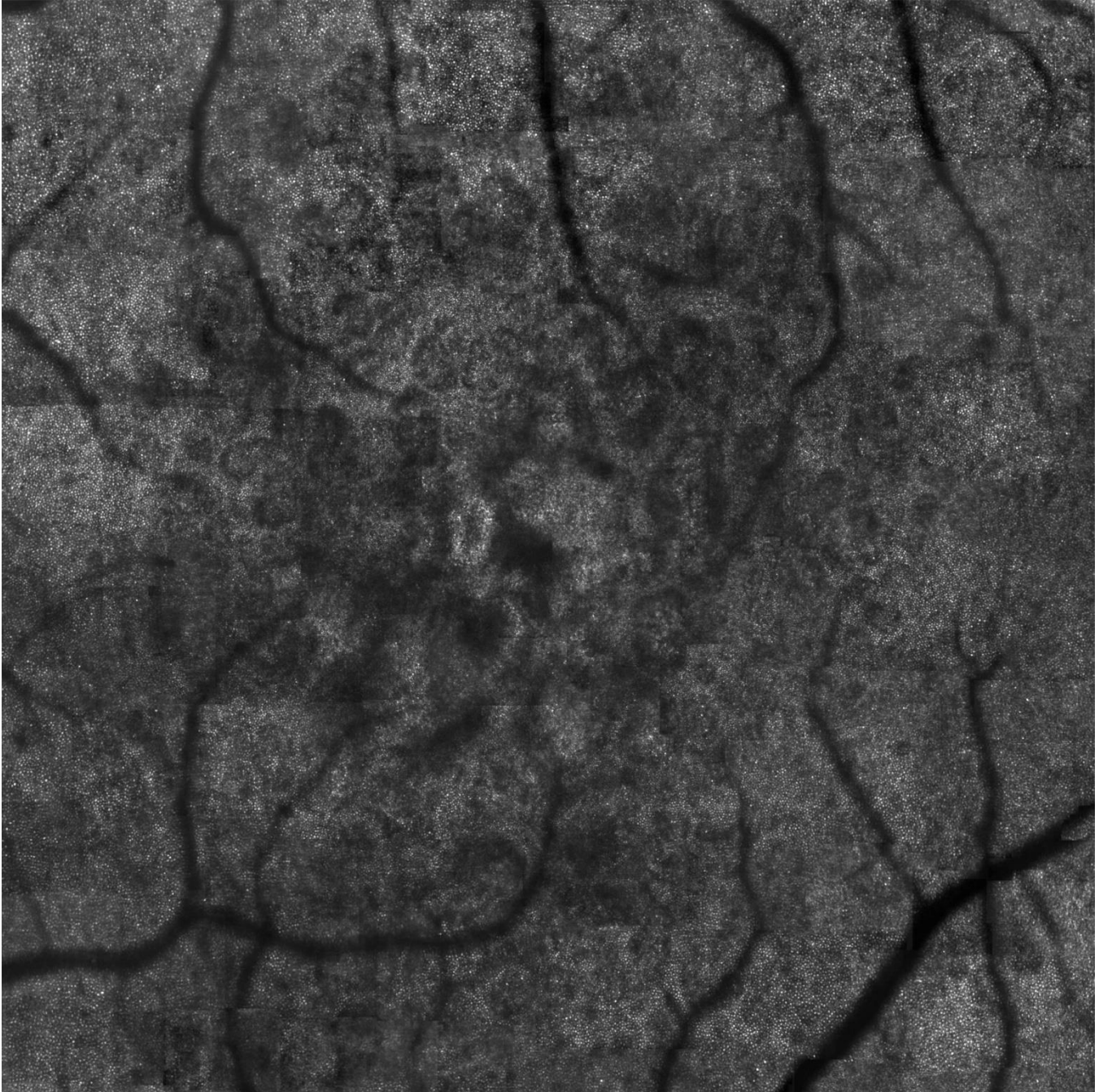


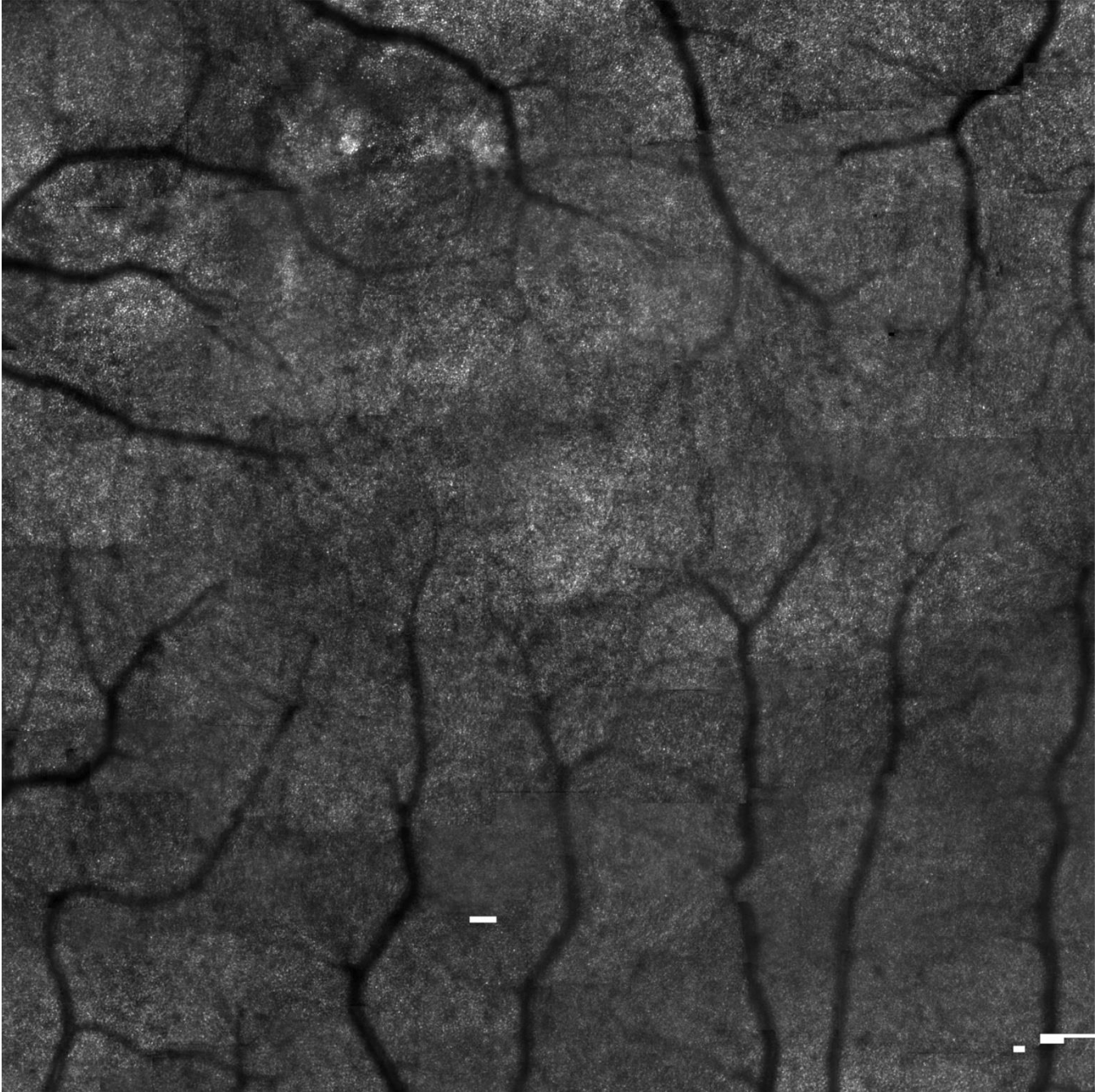
Supplemental materials:



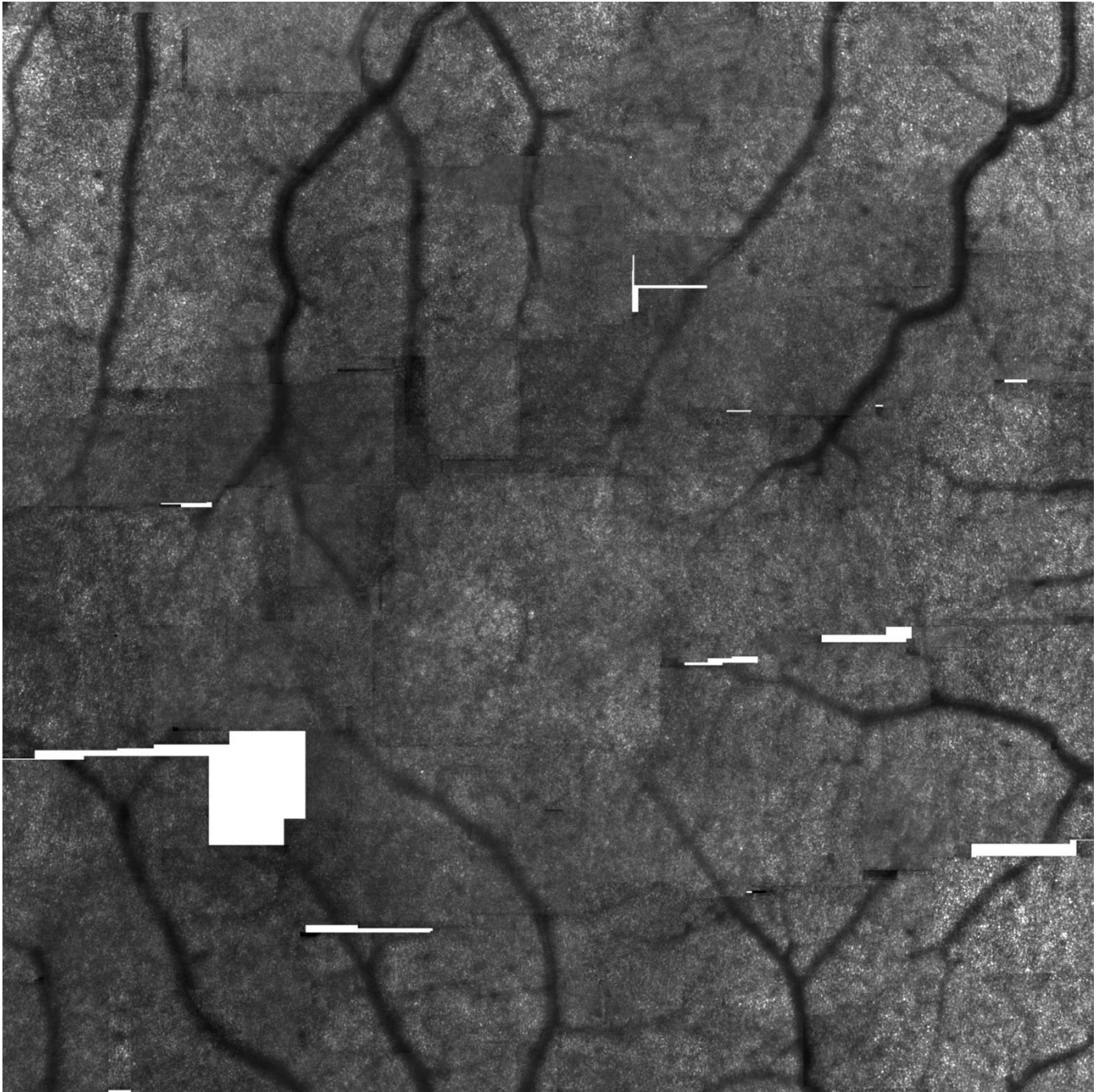
Supplemental Figure 1. An AOSLO montage of central macula in the eye of a normal subject (both eyes at AREDS grade 1) graded with 'Good' image quality. Cones are resolved in the entire montage. The opacity grade is 2. The images is approximately 10° X 10° inside the eye.



Supplemental Figure 2. An AOSLO montage of central macula in the eye of a patient with age-related macular degeneration (AREDS grade 7) graded with 'Good' image quality. Cones are resolved in the entire montage. Numerous hyporeflexive areas indicate drusen impact on overlying cones. The opacity grade is 1.5. The image is approximately 10° X 10° inside the eye.



Supplemental Figure 3. An AOSLO montage of central macula in the eye of a normal subject (both eyes at AREDS grade 1) graded with 'Adequate' image quality. Cones are resolved in 82% of the montage. The opacity grade is 4. The images is approximately 10° X 10° inside the eye.



Supplemental Figure 4. An AOSLO montage of central macula in the eye of a normal subject (both eyes at AREDS grade 1) graded with 'Inadequate' image quality. Cones are resolved in 55% of the montage. The opacity grade is 4.0. The images is approximately 10° X 10° inside the eye.