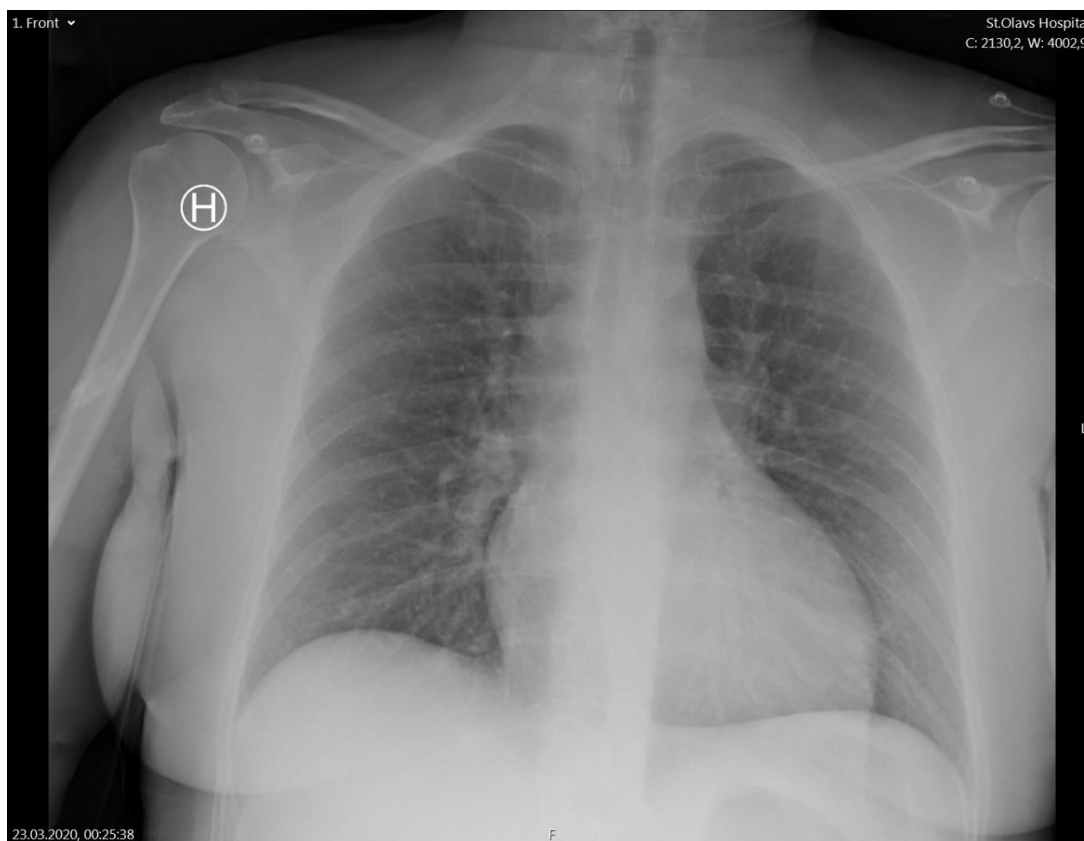


Supplementary figures

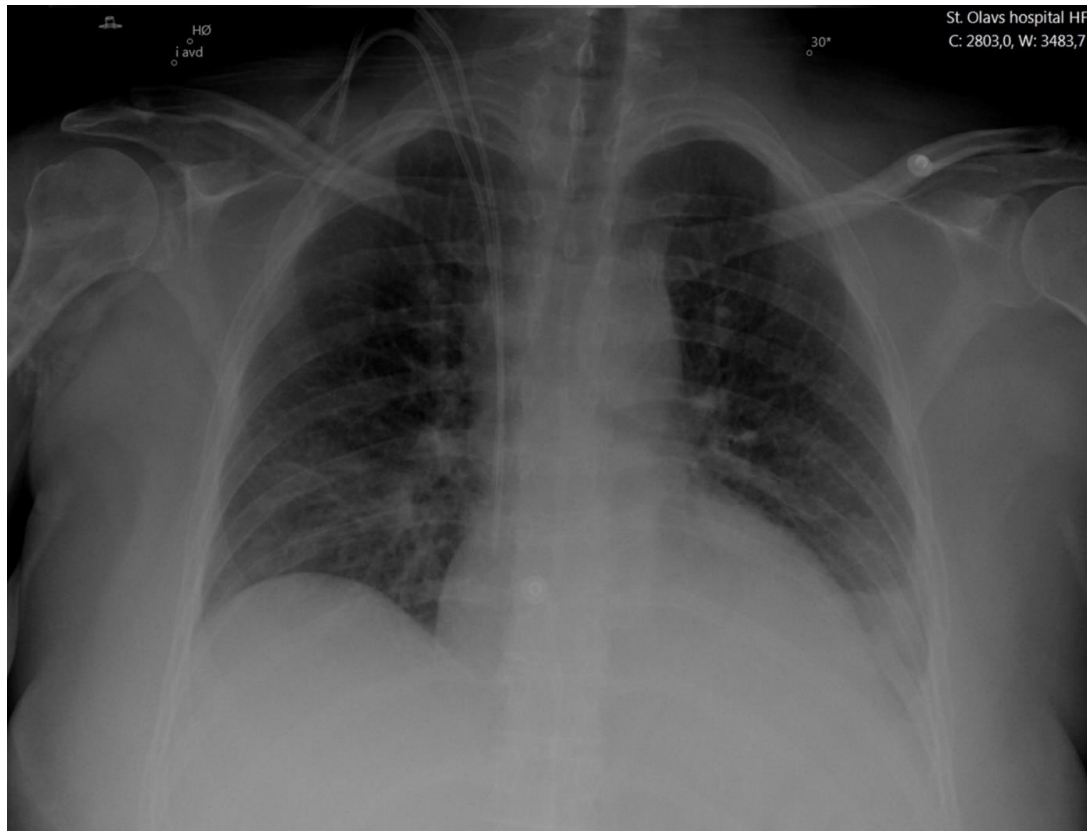
Page 1: Supplementary Figure 1. X-ray of patient at admission (day 7).

Page 2: Supplementary Figure 2. X-ray of patient at day 11.

Supplementary Figure 1. Chest X-ray of patient at admission (day 7).



Chest X-ray at admission with no pulmonary involvement.

Supplementary Figure 2. Chest X-ray of patient at day 11.

Chest x-ray at the intensive care unit showing minor amounts of bilateral pleural effusion and basal atelectasis in the left lung.