

Supplementary Material

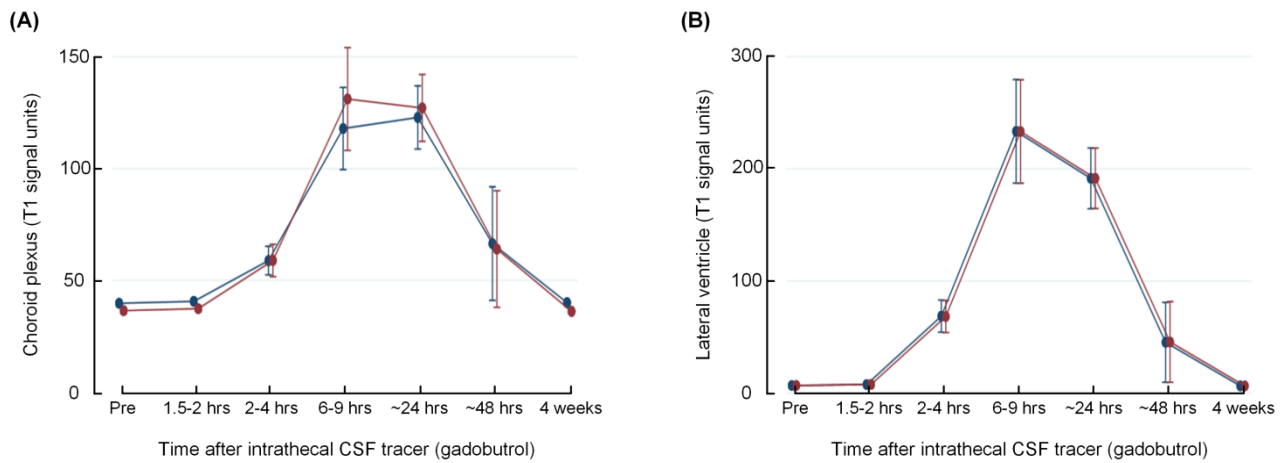
Delayed clearance of cerebrospinal fluid tracer from choroid plexus in idiopathic normal pressure hydrocephalus

Per Kristian Eide^{1,2}, Lars Magnus Valnes³, Are Hugo Pripp⁴, Kent-Andre Mardal^{3,5}, Geir Ringstad^{2,6}

¹*Department of Neurosurgery, Oslo University Hospital – Rikshospitalet;* ²*Institute of Clinical Medicine, Faculty of Medicine, University of Oslo, Oslo, Norway;* ³*Department of Mathematics, University of Oslo, Oslo, Norway;* ⁴*Oslo Centre of Biostatistics and Epidemiology, Research Support Services, Oslo University Hospital, Oslo, Norway;*

⁵*Center for Biomedical Computing, Simula Research Laboratory, Lysaker, Norway;* ⁶*Division of Radiology and Nuclear Medicine, Department of Radiology, Oslo University Hospital - Rikshospitalet, Oslo, Norway.*

Suppl Fig. 1



CSF tracer enrichment in choroid plexus (A) and CSF of lateral ventricle (B) in the two groups with different segmentation. Trend plots of T1 signal units are shown for the group with edited segmentation (blue lines) and the one with non-edited segmentation (red lines). The trend plots are shown as mean \pm standard error (SE). Mixed model analysis showed no differences between signals in choroid plexus ($P=0.135$; A) or CSF lateral ventricle ($P=0.725$; B).