

## Post COVID -19 Pneumonia Pulmonary Fibrosis

### Authors:

Dr. Sudheer Tale <sup>1</sup>

Dr. Soumitra Ghosh <sup>2</sup>

Dr. Soibam Pahel Meitei <sup>1</sup>

Dr. Mrudula Kolli <sup>3</sup>

Dr. Anil Kumar Garbhapu <sup>4</sup>

Dr. Sivaji Pudi <sup>5</sup>

1,5 – Senior Resident, All India Institute of Medical Sciences, Rishikesh

2 – Senior Resident, Post Graduate Institute of Medical Education and Research, Chandigarh.

3 – Senior Resident, Gandhi Medical College, Secunderabad

4 – Senior Resident, Dr.RML Medical College, Delhi.

### **Corresponding Author:**

Dr Sudheer Tale

Senior Resident

Department of Pulmonary Medicine,

All India Institute of Medical Sciences, Rishikesh

[drtalesudheer@gmail.com](mailto:drtalesudheer@gmail.com)

Ph no: 8872156777

## Case:

A 48-year old male patient with no prior co-morbidities presented to emergency department with complaints of dry cough, fever and throat pain for the preceding 5 days followed by shortness of breath for the past 2 days. He had no significant travel or contact history. His vitals were stable except for mild hypoxemia on room air (spo2 of 92%) On laboratory investigation he had lymphopenia, elevated LDH, raised C-reactive protein and elevated D-dimer levels. Initial chest radiograph revealed peripheral multiple inhomogeneous opacities in bilateral lung fields. His RT-PCR nasal and oropharyngeal swab for Covid-19 came out be positive and he was managed conservatively with supplemental oxygen, low molecular weight heparin, dexamethasone and antipyretics. He was symptomatically improved but continued to have hypoxemia even after 3 weeks of treatment, so a high resolution computed tomography of the chest was performed and it showed architectural distortion, interlobar septal thickening and traction bronchiectasis features (shown in figure 1A and 1B) suggestive of fibrotic lung disease. He was discharged on home oxygen therapy and planned to enroll him in antifibrotic therapy trail during the subsequent follow up.

## Discussion:

Clinical manifestations of COVID-19 have ranged from asymptomatic/mild symptoms to severe illness and mortality.(1) Most of the mild and moderate cases are recovered completely but a small proportion of severe cases with acute respiratory distress syndrome continued to remain hypoxemic despite adequate treatment. Chest imaging of this subset of patients revealed fibrotic changes in the form of traction bronchiectasis, architectural distortion and septal thickening similar to the changes seen in other fibrotic lung diseases.(2) The pathogenesis of post infective pulmonary fibrosis include dysregulated release of matrix metalloproteinases during the inflammatory phase of ARDS causing epithelial and endothelial injury with unchecked fibroproliferation. There is also a vascular dysfunction which is a key component of the switch from ARDS to fibrosis, with VEGF and cytokines such as IL-6 and TNF $\alpha$  being implicated.(3) Although the role of presently available antifibrotic drugs (pirfenidone and nintedanib) for fibrotic lung diseases beyond idiopathic pulmonary fibrosis have been evaluated by some

authors (4) their role in post COVID-19 pneumonia pulmonary fibrosis need further research in the present pandemic.

### References:

1).Guan WJ, Ni ZY, Hu Y, Liang WH, Ou CQ, He ZX, et al. Clinical Characteristics of Coronavirus Disease 2019 in China. *N Engl J Med*. 2020;382(18):1708-1720.

2).Kalchiem DO, Galvin JR, Burke AP, Atamas SP, Todd NW. Interstitial Lung Disease and Pulmonary Fibrosis: A Practical Approach for General Medicine Physicians with Focus on the Medical History. *J Clin Med*. 2018;7(12):476.

3).Bridget F. Collins and Ganesh Raghu. "Antifibrotic therapy for fibrotic lung disease beyond idiopathic pulmonary fibrosis." *Eur Respir Rev* 2019; 28: 190022. *Eur Respir Rev*. 2019;28(154):195022.

4).Burnham EL, Janssen WJ, Riches DW, Moss M, Downey GP. The fibroproliferative response in acute respiratory distress syndrome: mechanisms and clinical significance. *Eur Respir J* 2014; 43: 276–85.

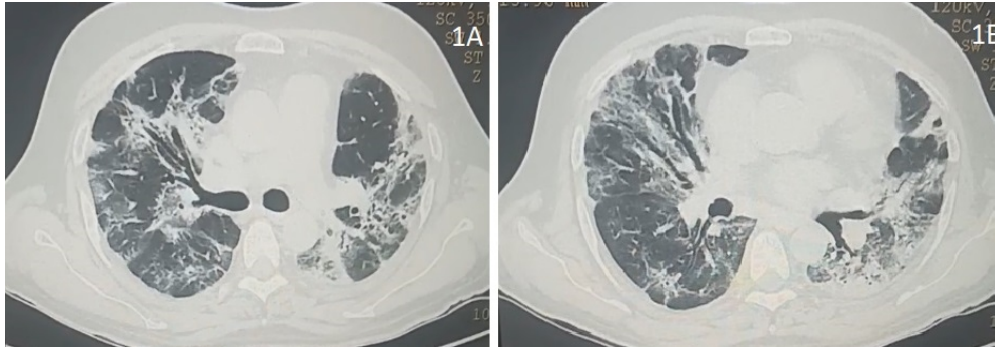


Figure 1A and 1B: showing traction bronchiectasis, architectural distortion and interlobar septal thickening suggestive of pulmonary fibrosis.

78x27mm (300 x 300 DPI)