

OMTO, Volume 18

Supplemental Information

Biodistribution Analysis of Oncolytic

Adenoviruses in Canine Patient Necropsy

Samples Treated with Cellular Virotherapy

Ana Gómez, David Sardón, Teresa Cejalvo, Fernando Vázquez, Javier García-Castro, and Ana Judith Perisé-Barrios

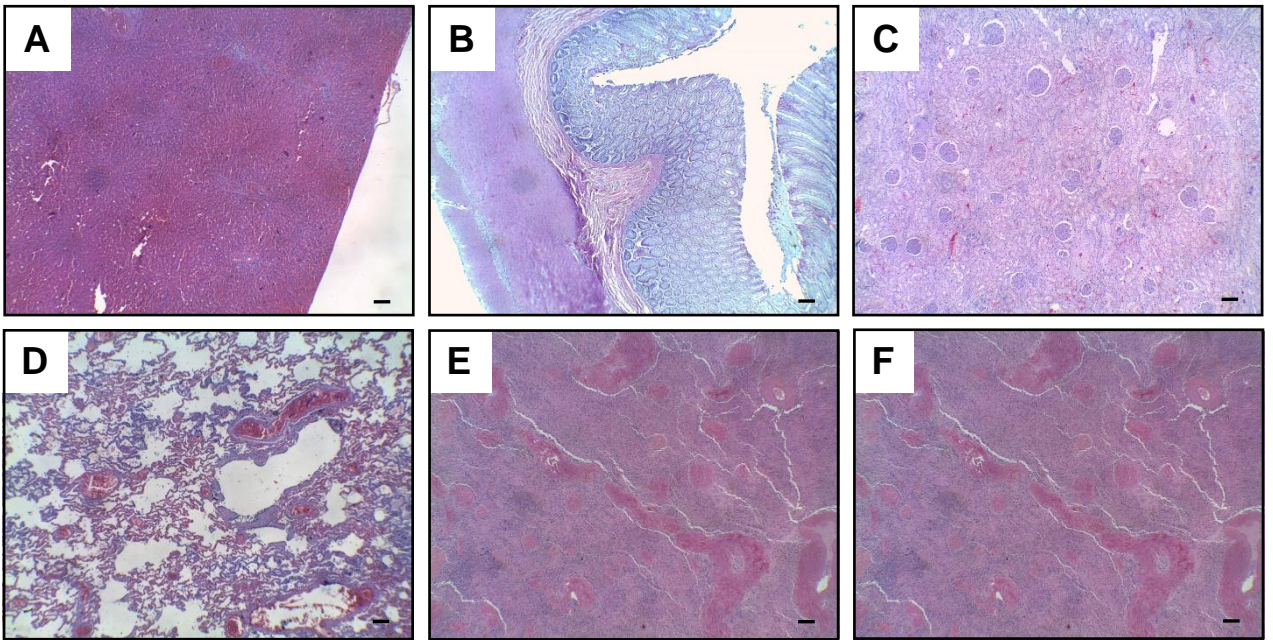


Figure S1. Tissues from oncologic patients treated with conventional treatment are shown. Representative images of hematoxylin and eosin stained necropsy samples from liver (A), gastrointestinal tract (B), kidney (C), lung (D), spleen (E) and pancreas (F) are shown. Scale bar: 100 μ m.