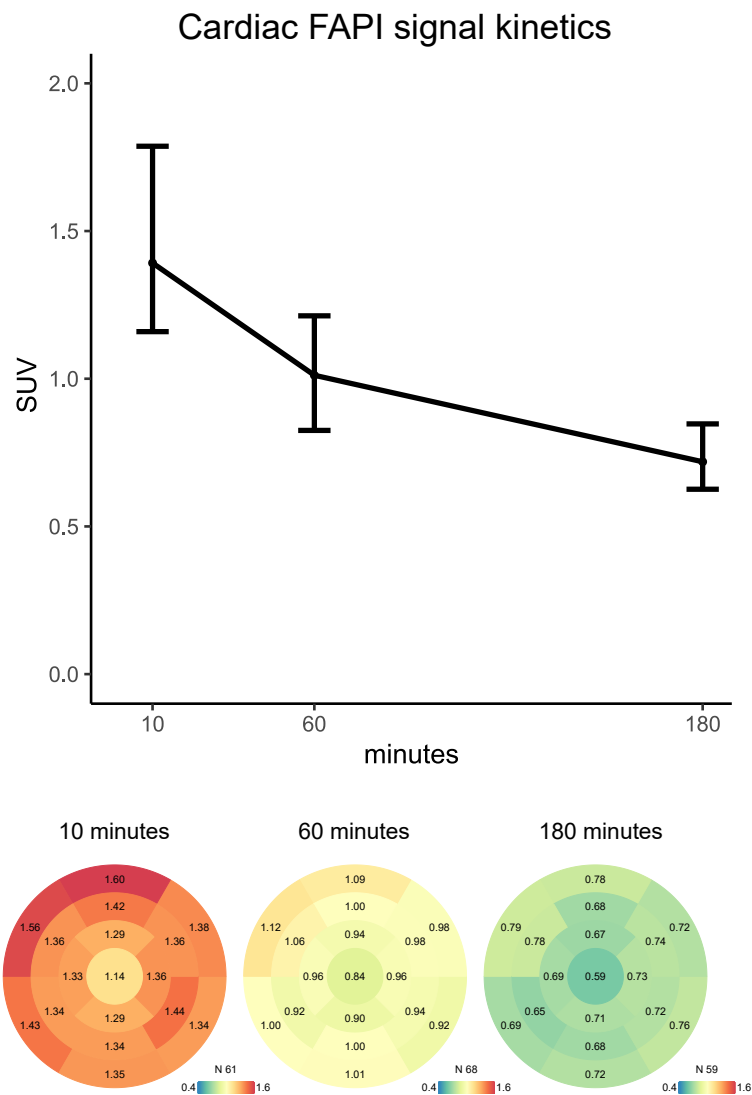


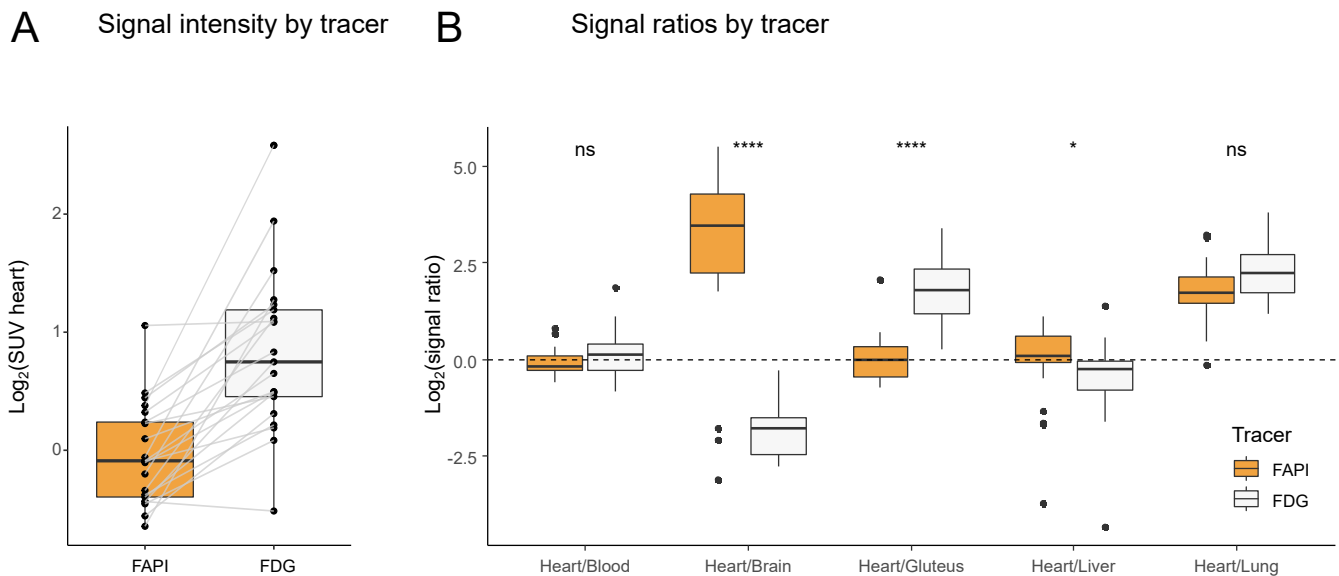
# SUPPLEMENTAL MATERIAL

## Supplementary Figure 1



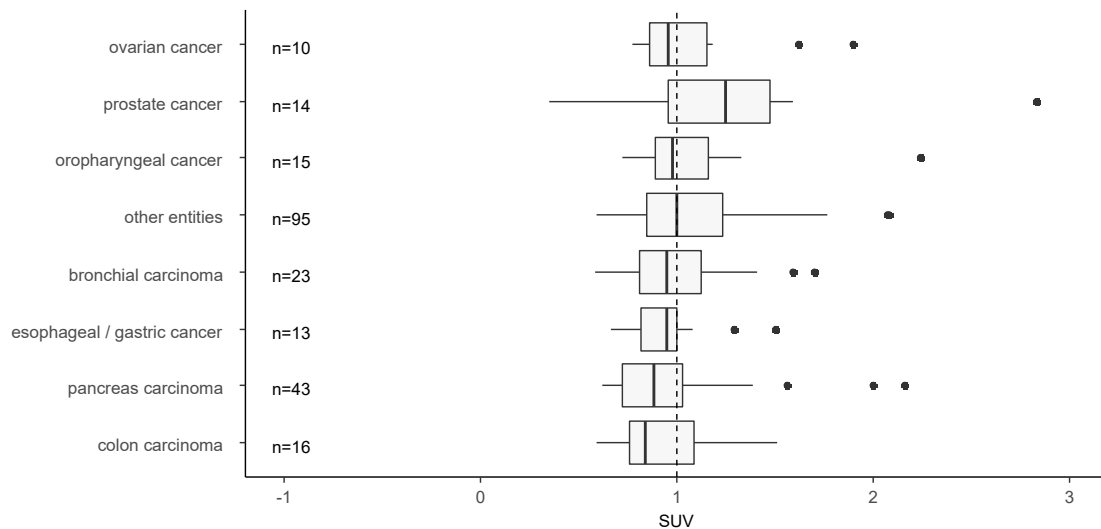
**Suppl. Figure 1: Cardiac FAPI signal kinetics.** FAPI signals were measured 10, 60 and 180 minutes after administration. The median SUVs and their respective interquartile ranges are depicted. Cardiac signals were highest 10 minutes after administration and decreased continuously in time. The median signal intensities for each segment and the number of patients scanned are reported in the corresponding bullseye.

## Supplementary Figure 2



**Suppl. Figure 2. FAPI and FDG signals and signal ratios.** FAPI and FDG signals in all patients who had FDG and FAPI PET-CT examinations within 12 months (n=21). FAPI and FDG signals are portrayed for each patient (A) and signal ratios were calculated for different organs (B). Myocardial standardized uptake values (SUV) were generally higher using an FDG tracer. Signal ratios were similar between FDG and FAPI for heart/blood pool as well as heart/ lung. Heart brain and heart liver ratios were significantly higher while the heart gluteus ratio was lower using a FAPI tracer. Signal ratios were compared using a Kruskal-Wallis test. \* p<0.05, \*\*\*\*p<0.0001

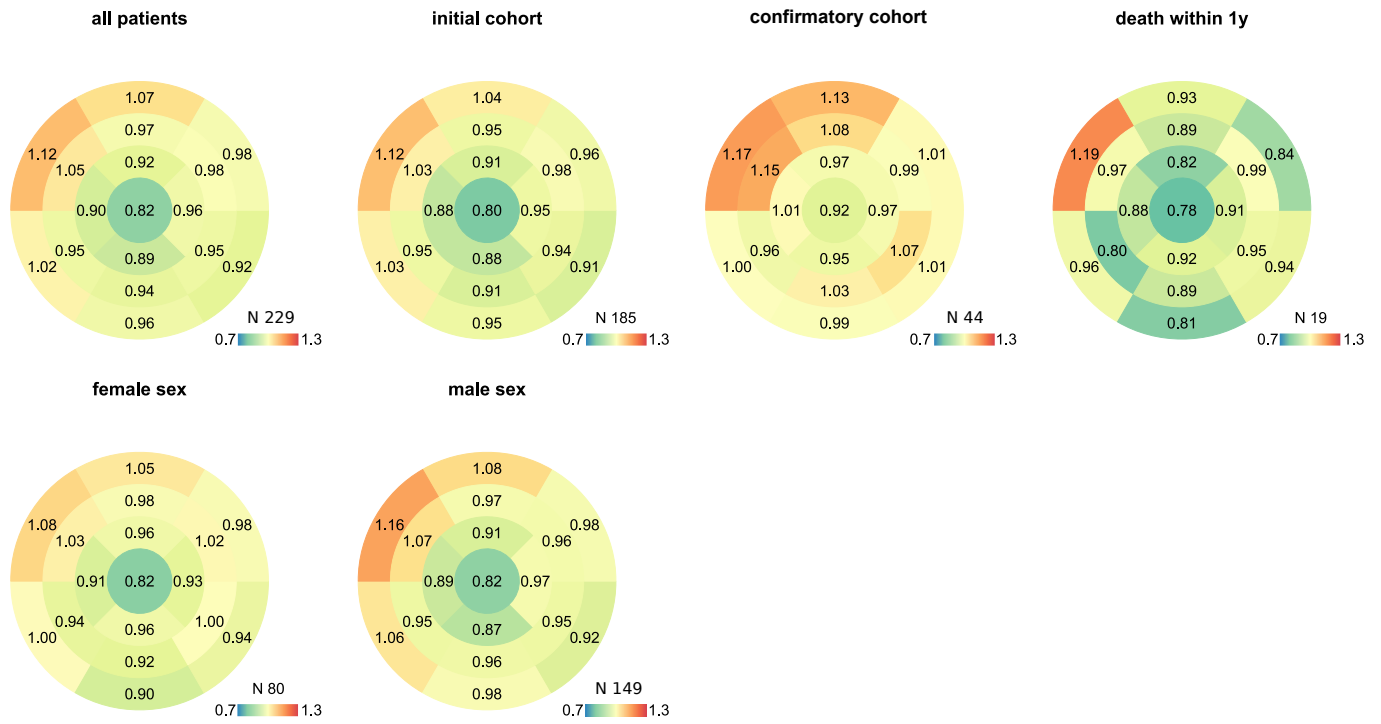
## Supplementary Figure 3



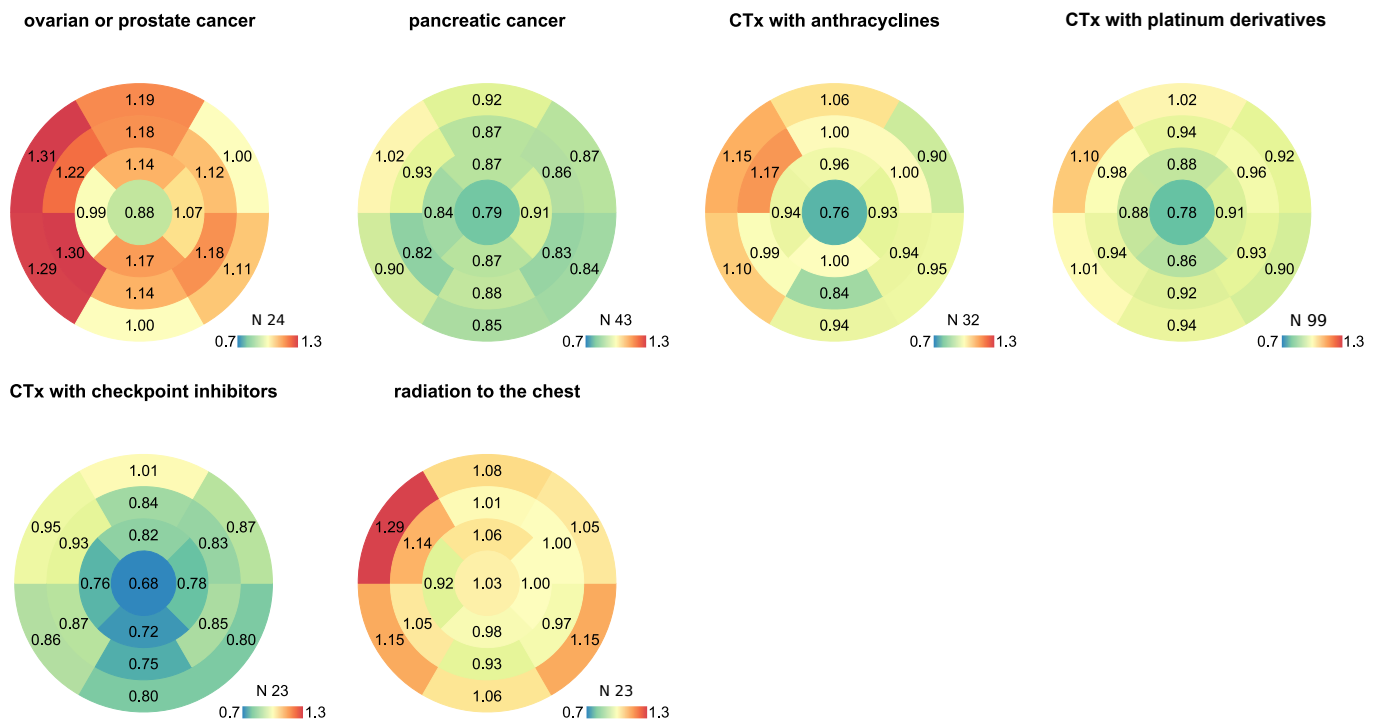
**Suppl. Figure 3. Myocardial signal intensities by main entity.** Standardized uptake values (SUV) are reported for each cancer entity.

# Supplementary Figure 4

## Patient cohorts and subgroups

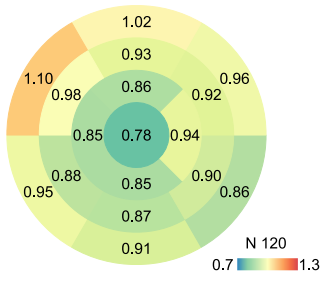


## Cancer and cancer therapy

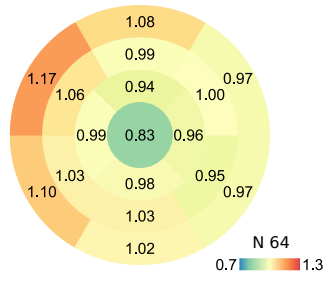


# Cardiovascular risk and medication

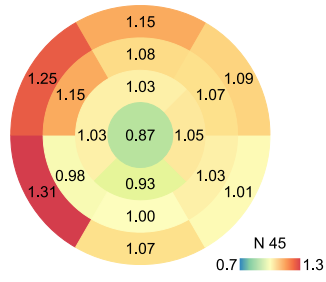
no CvRF



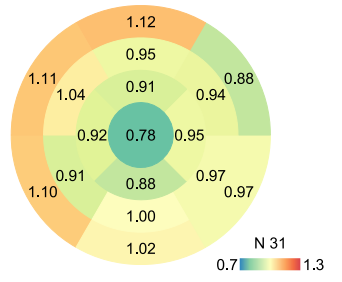
CvRF 1-4



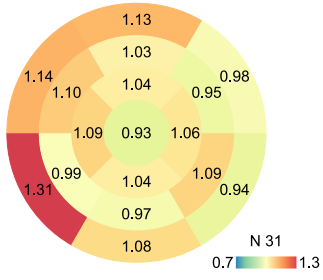
CvRF >4



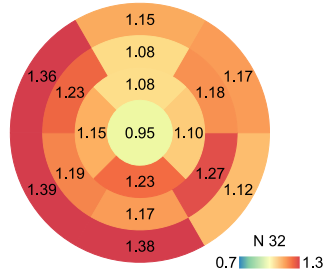
smokers



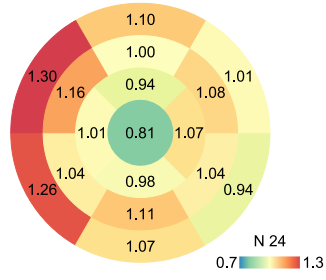
coronary artery disease



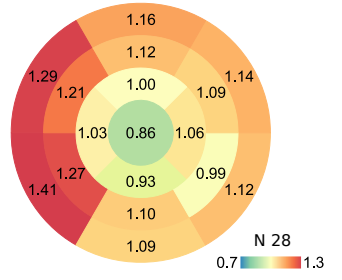
daily Aspirin use



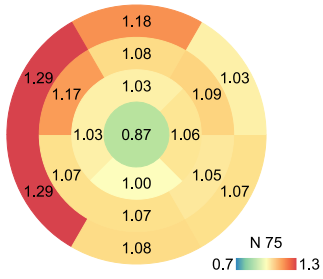
daily statin use



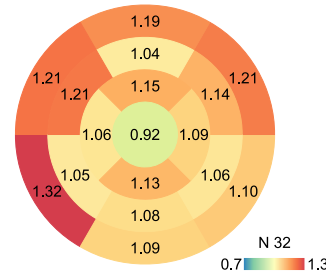
diabetes mellitus



arterial hypertension

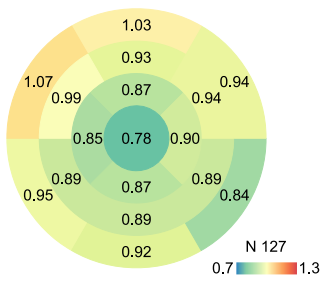


daily betablocker use

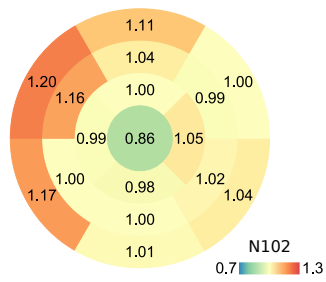


## Obesity and metabolic disease

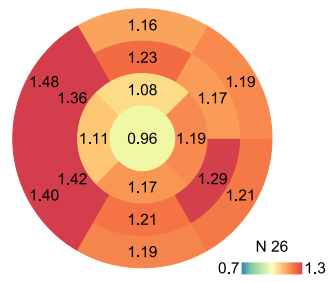
normal weight: BMI<25kg/m<sup>2</sup>



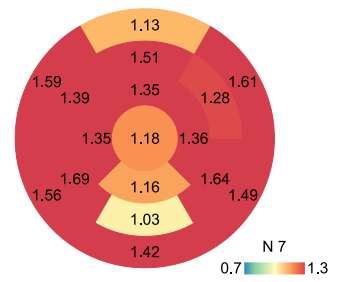
overweight: BMI>25kg/m<sup>2</sup>



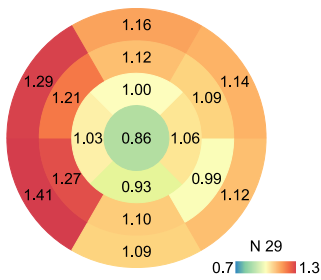
obesity: BMI>30kg/m<sup>2</sup>



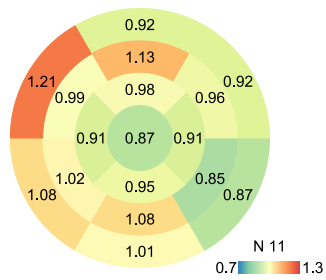
obesity: BMI>35kg/m<sup>2</sup>



diabetes mellitus

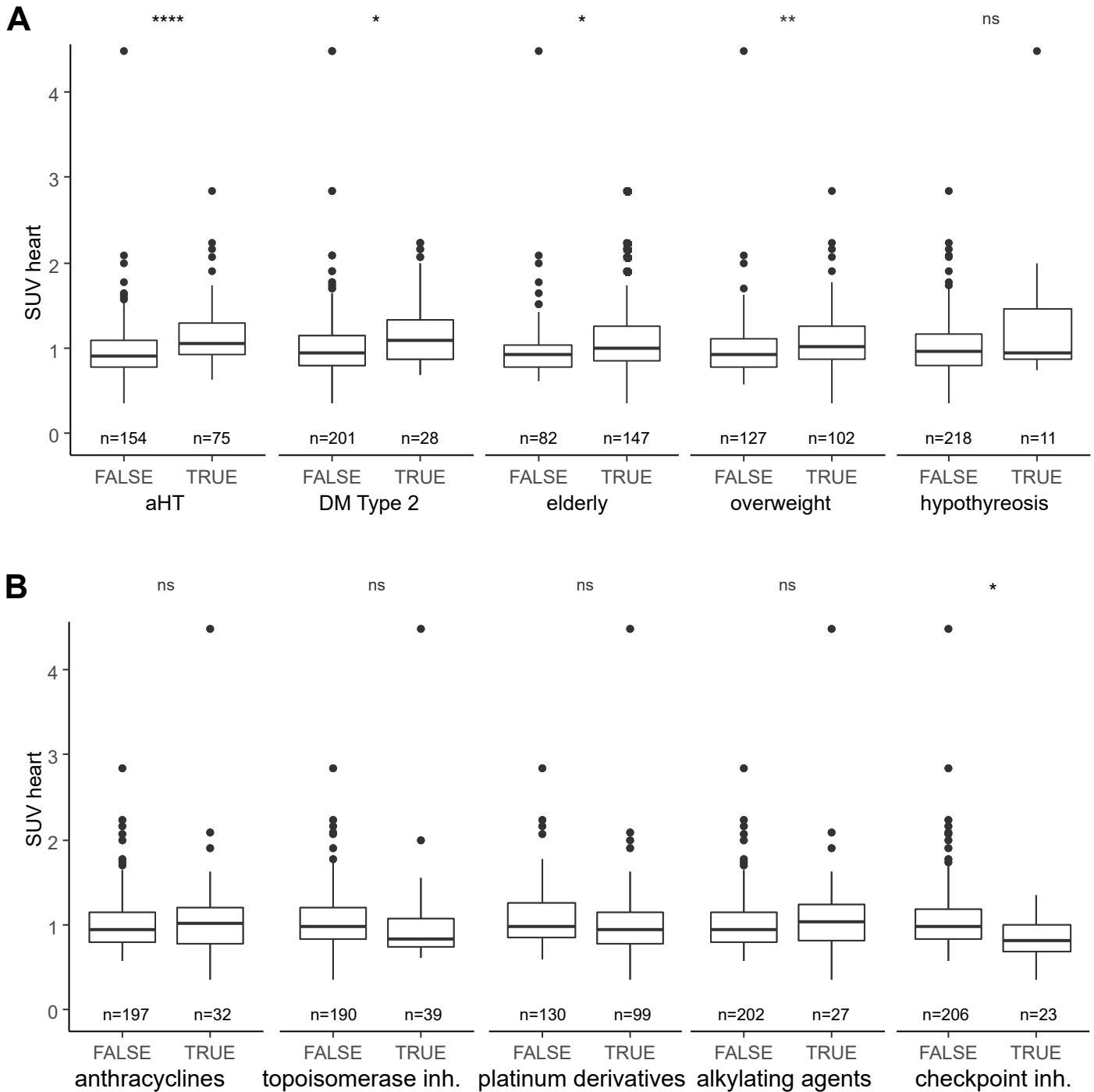


TSH > 4.0mU/l



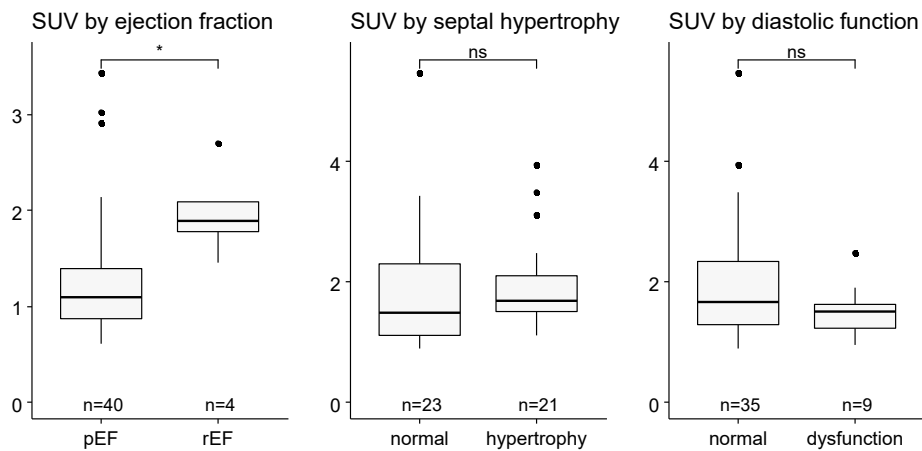
**Suppl. Figure 4: Median FAPI signal by subgroup.** Subgroups are organized thematically. The median signal intensity for each patient subgroup and the group size is reported in each bullseye.

# Supplementary Figure 5



**Suppl. Figure 5.** (A) Myocardial FAPI signal intensities in special subgroups prone to myocardial fibrosis. Patients with arterial hypertension, diabetes mellitus, the elderly and overweight patients showed a significant increase in FAPI signal. The difference in patients with hypothyreosis was not significant. (B) Myocardial FAPI signal intensities by chemotherapy use. After p-level adjustment only patients treated with checkpoint inhibitor showed reduced FAPI signal intensities. Wilcoxon sum test with holm-bonferroni p-level adjustment. ns not significant, \*  $p < 0.05$ , \*\*  $p < 0.01$ , \*\*\*  $p < 0.001$ , \*\*\*\*  $p < 0.0001$ .

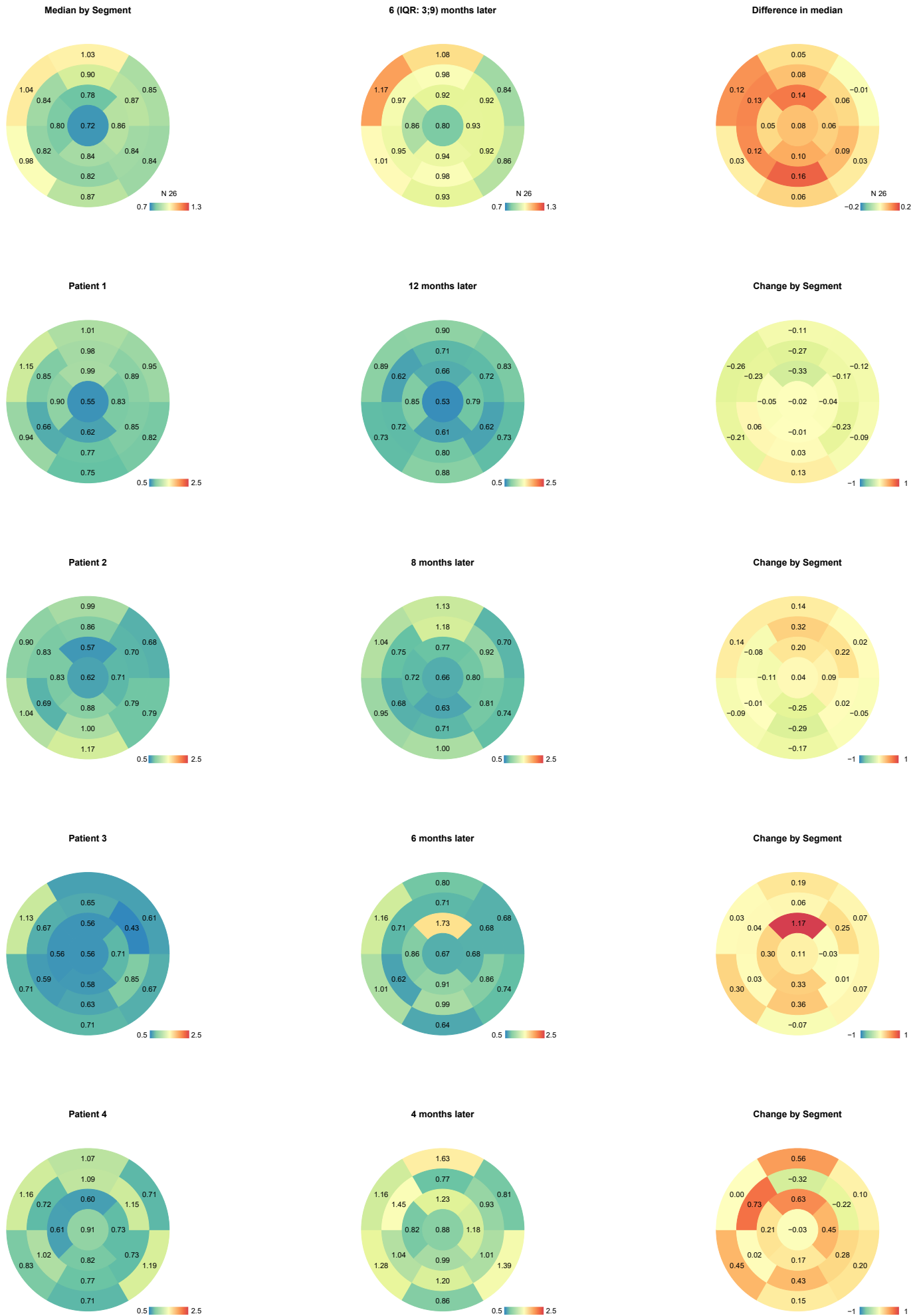
## Supplementary Figure 6



**Suppl. Figure 6. FAPI standardized uptake value (SUV) and echocardiographic findings.**

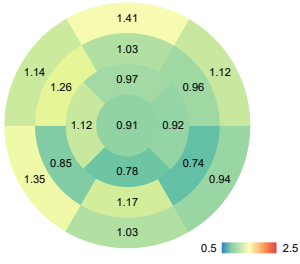
Echocardiographic findings of all patients where echocardiographic data was available (n=44). Patients with reduced ejection fraction showed an increase SUV while other echocardiographic findings such as septal hypertrophy and diastolic function were not associated with increased signal intensities.

# Supplementary Figure 7

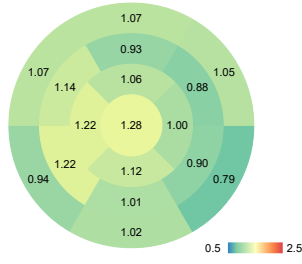




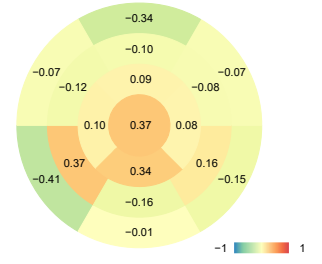
Patient 5



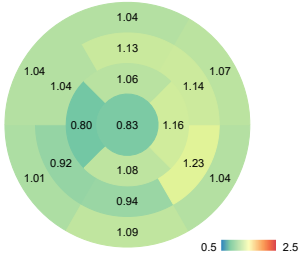
5 months later



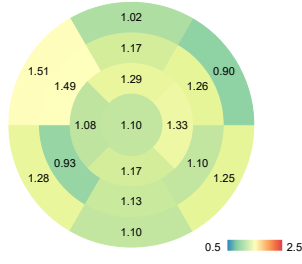
Change by Segment



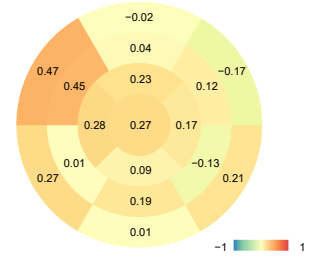
Patient 6



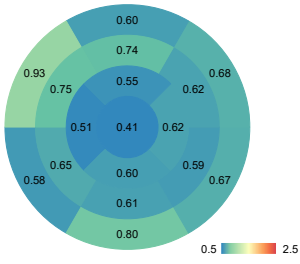
10 months later



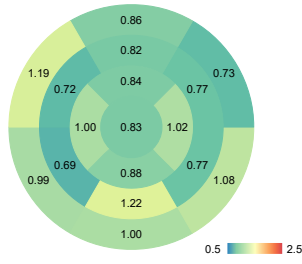
Change by Segment



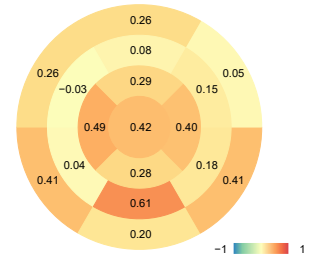
Patient 7



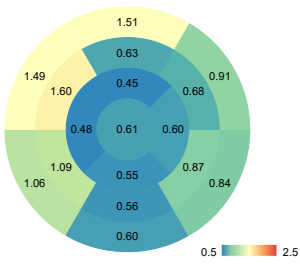
5 months later



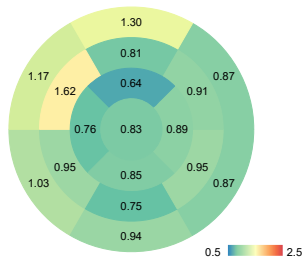
Change by Segment



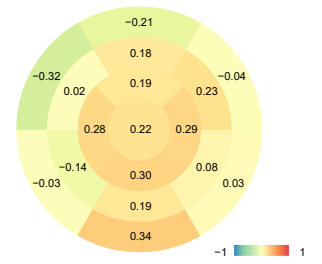
Patient 8



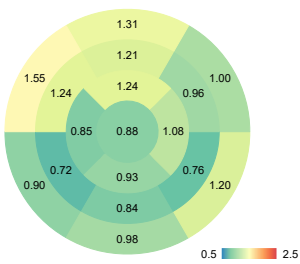
8 months later



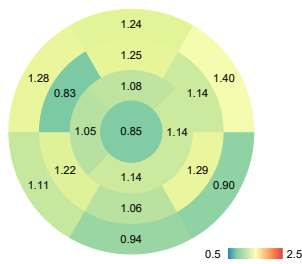
Change by Segment



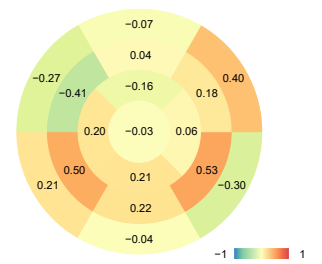
Patient 9



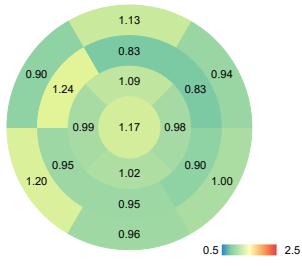
10 months later



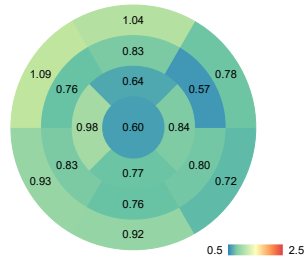
Change by Segment



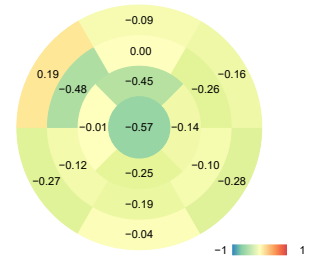Patient 10



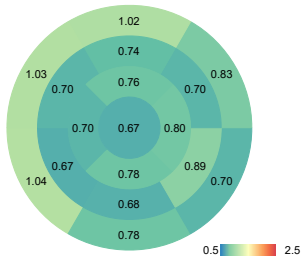
7 months later



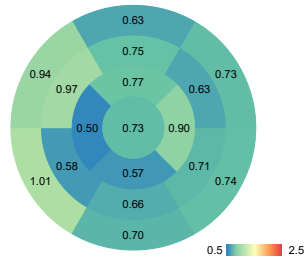
Change by Segment



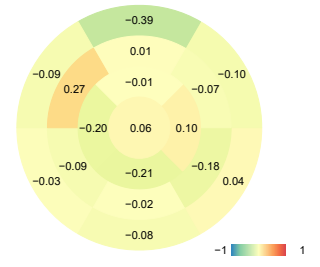
Patient 11



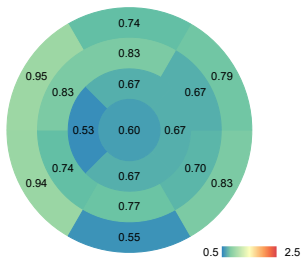
5 months later



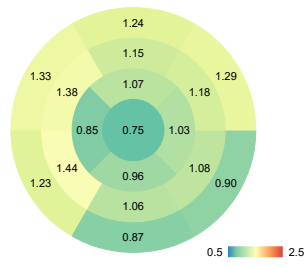
Change by Segment



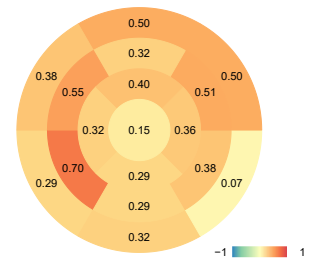
Patient 12



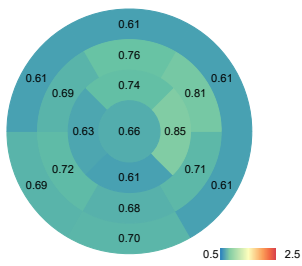
6 months later



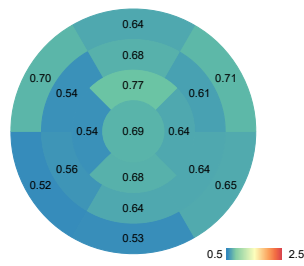
Change by Segment



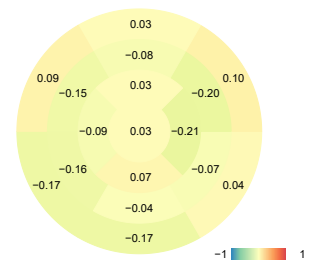
Patient 13



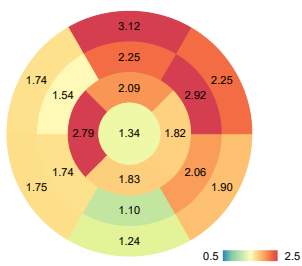
17 months later



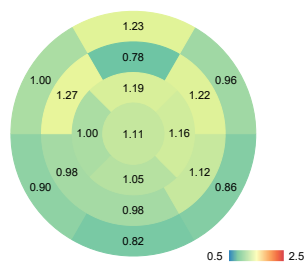
Change by Segment



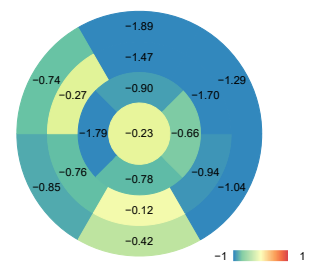
Patient 14



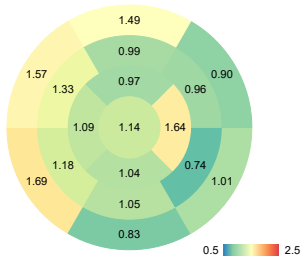
8 months later



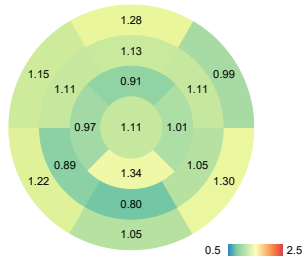
Change by Segment



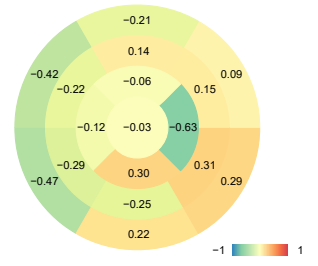
Patient 15



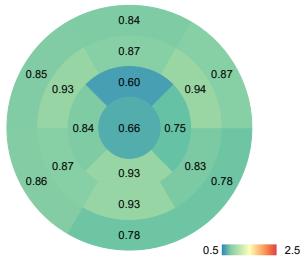
6 months later



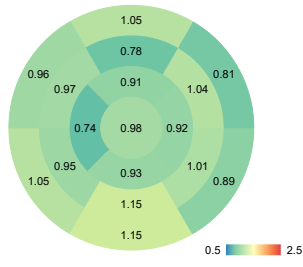
Change by Segment



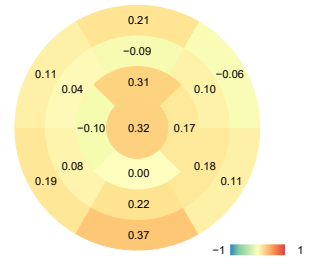
Patient 16



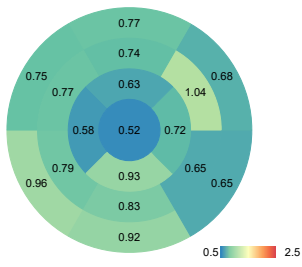
22 months later



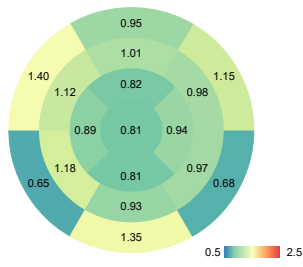
Change by Segment



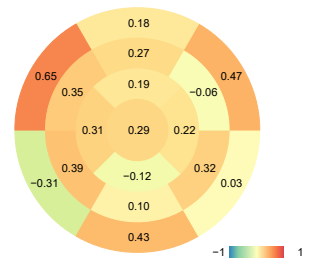
Patient 17



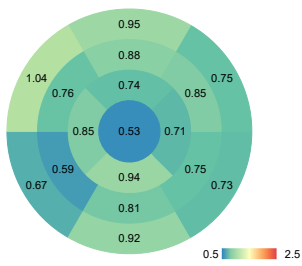
3 months later



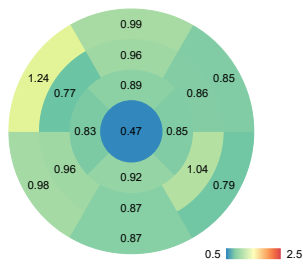
Change by Segment



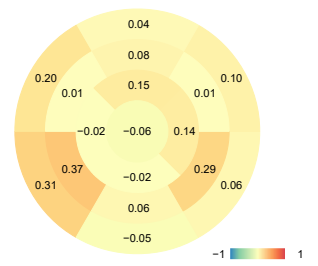
Patient 18



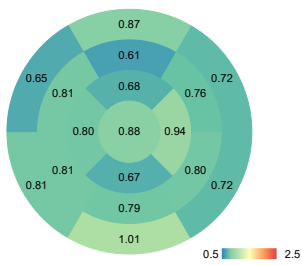
6 months later



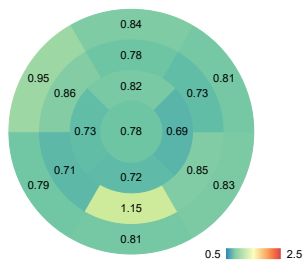
Change by Segment



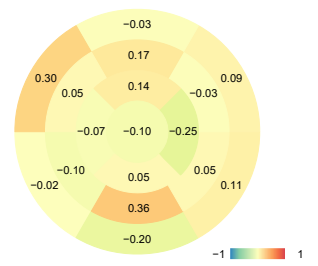
Patient 19



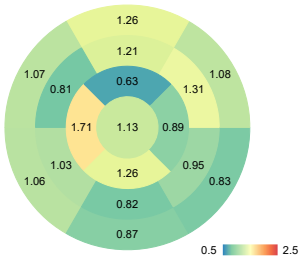
3 months later



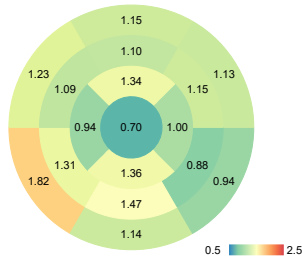
Change by Segment



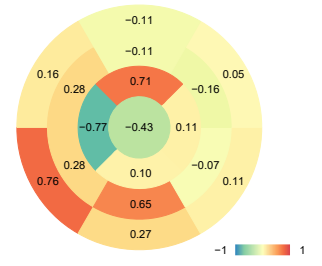
Patient 20



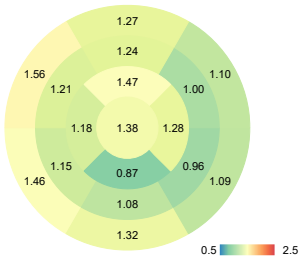
5 months later



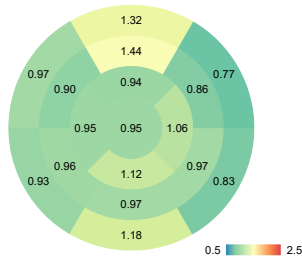
Change by Segment



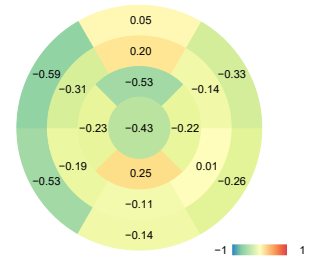
Patient 21



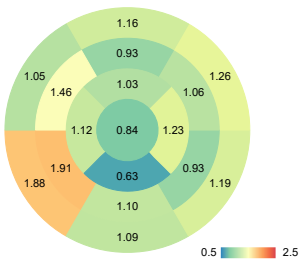
16 months later



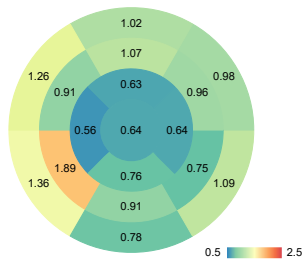
Change by Segment



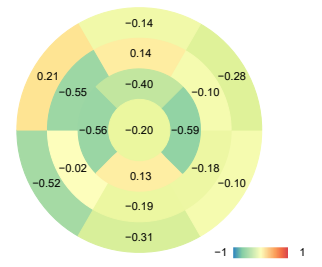
Patient 22



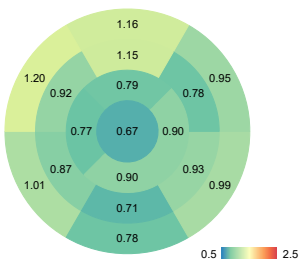
4 months later



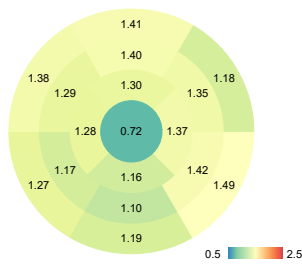
Change by Segment



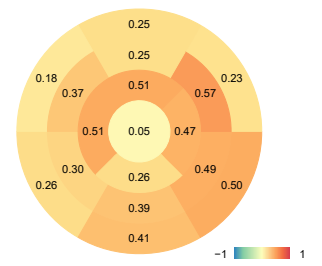
Patient 23



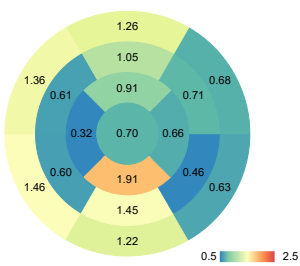
5 months later



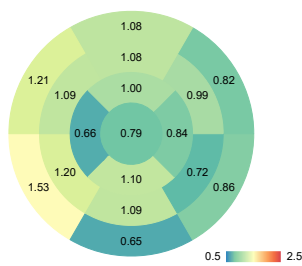
Change by Segment



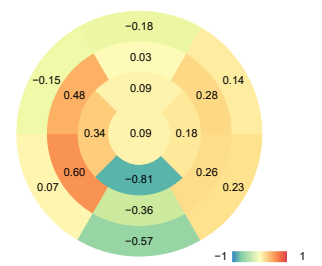
Patient 24

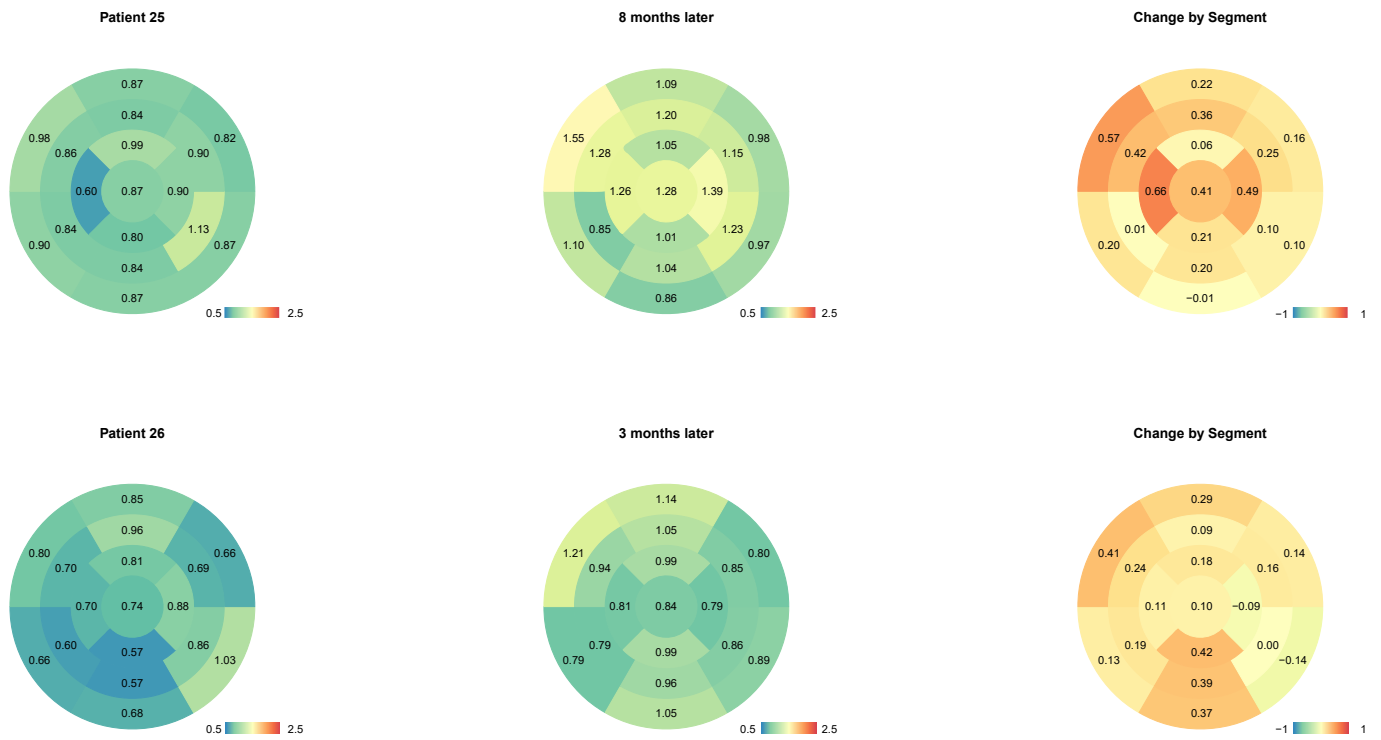


2 months later



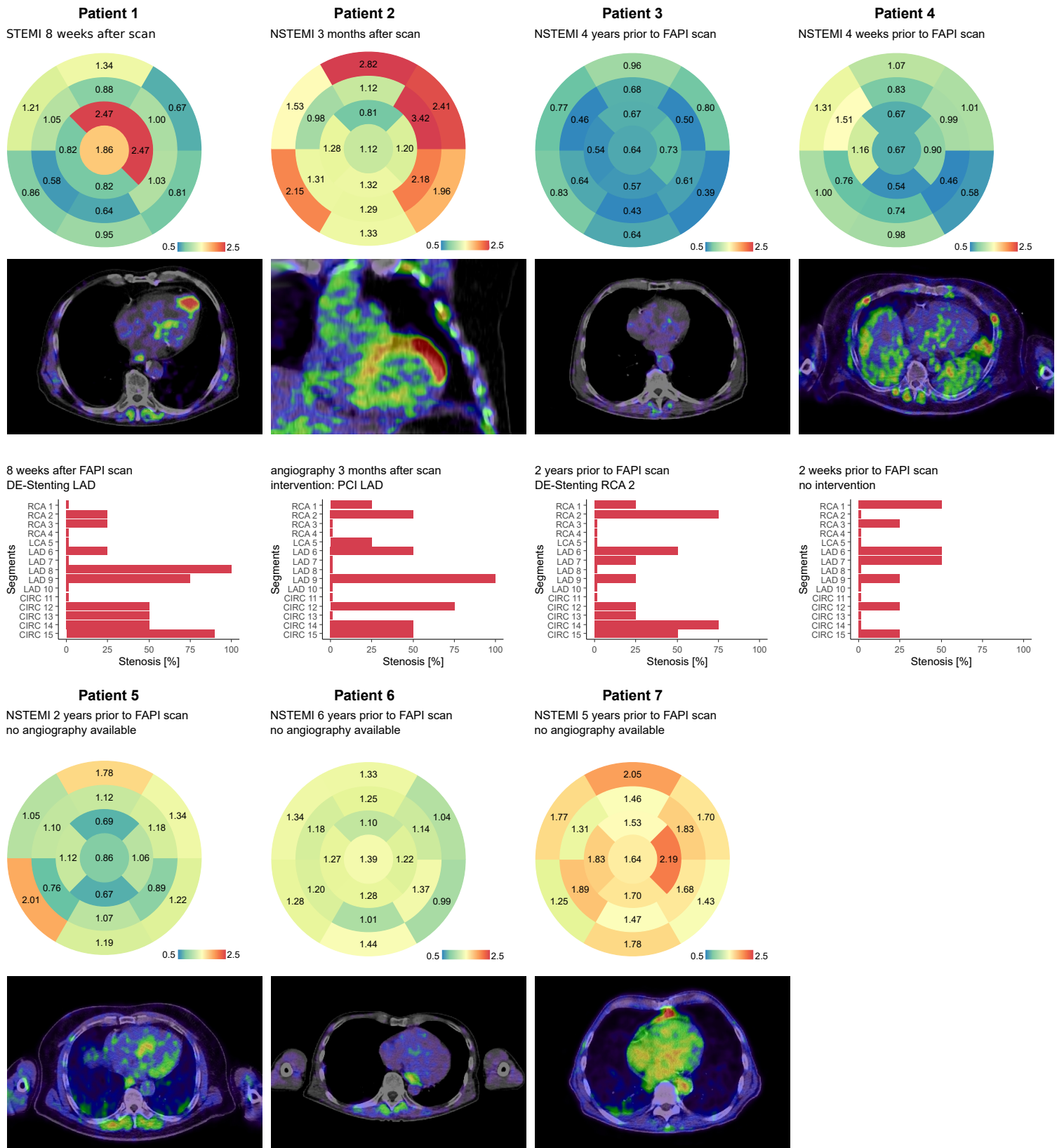
Change by Segment





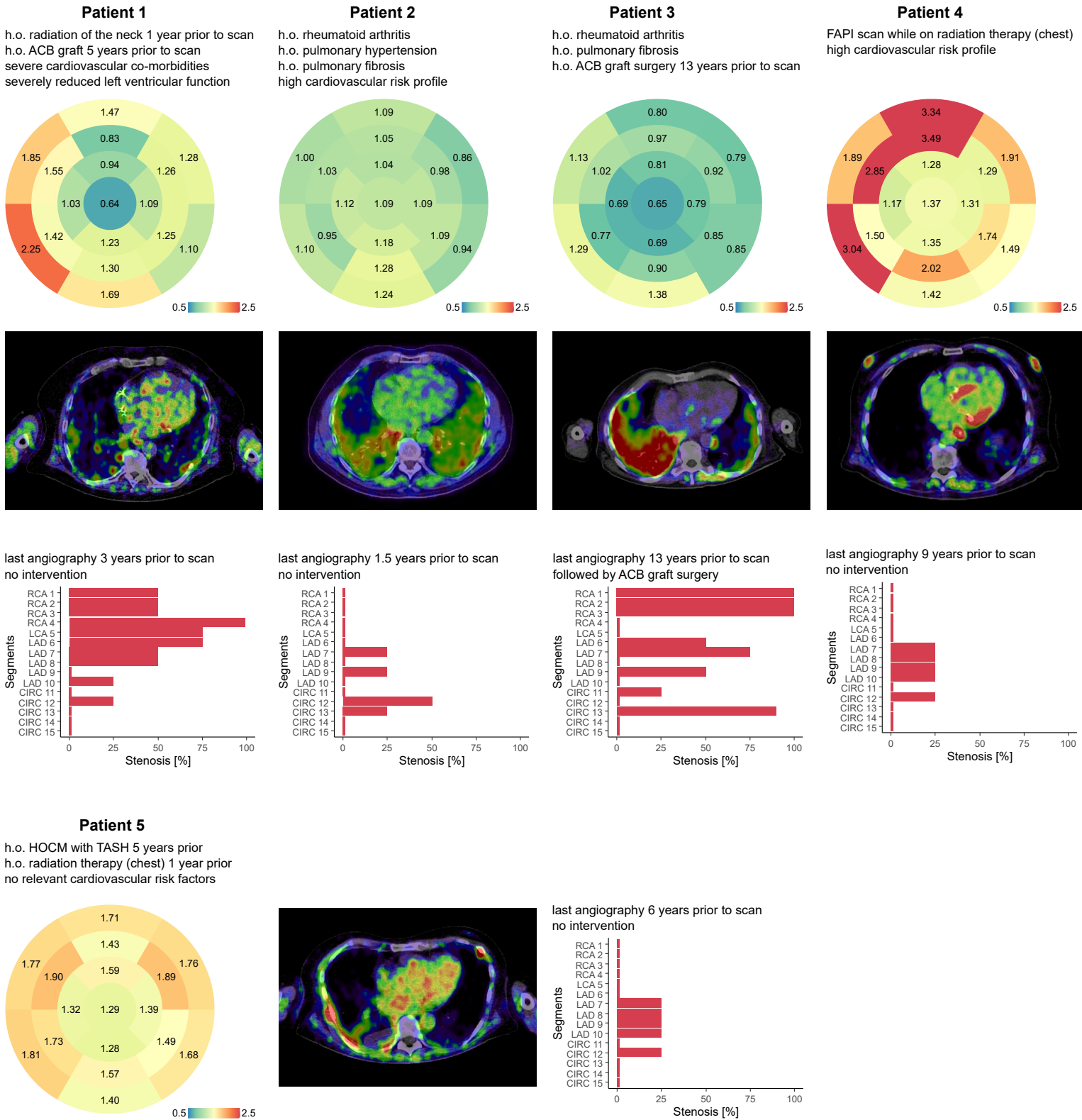
**Suppl. Figure 7: Sequential FAPI-PET-CT scans.** 26 Patients received sequential scans. The first row reports median signal intensities measured during the first and second scans for each segment. Differences are reported in the third column. Each patient is reported in a separated row. While there is a general increase in signal intensity over time, there is also one patient (patient 14), who showed a clear decrease in cardiac FAPI signals in the follow scan.

# Supplementary Figure 8



**Suppl. Figure 8. FAPI signals in patients following myocardial infarction.** FAPI signals are reported for each segment with a short medical history of each case and a FAPI-PET-CT image followed by coronary angiography findings where available. Interestingly, there is no evident increase in signal intensities years after myocardial infarction.

# Supplementary Figure 9



**Suppl. Figure 9. Patients with FAPI scans after coronary intervention.** Left ventricular FAPI signals intensities for each segment are reported with a short medical history followed by the last coronary angiography. While the severity of the coronary artery disease does not seem to correlate directly with FAPI intensities, radiotherapy of esophageal cancer in patient 4 is likely to have increased FAPI signals in the anterior wall as a sign of cardiac inflammation and remodelling.