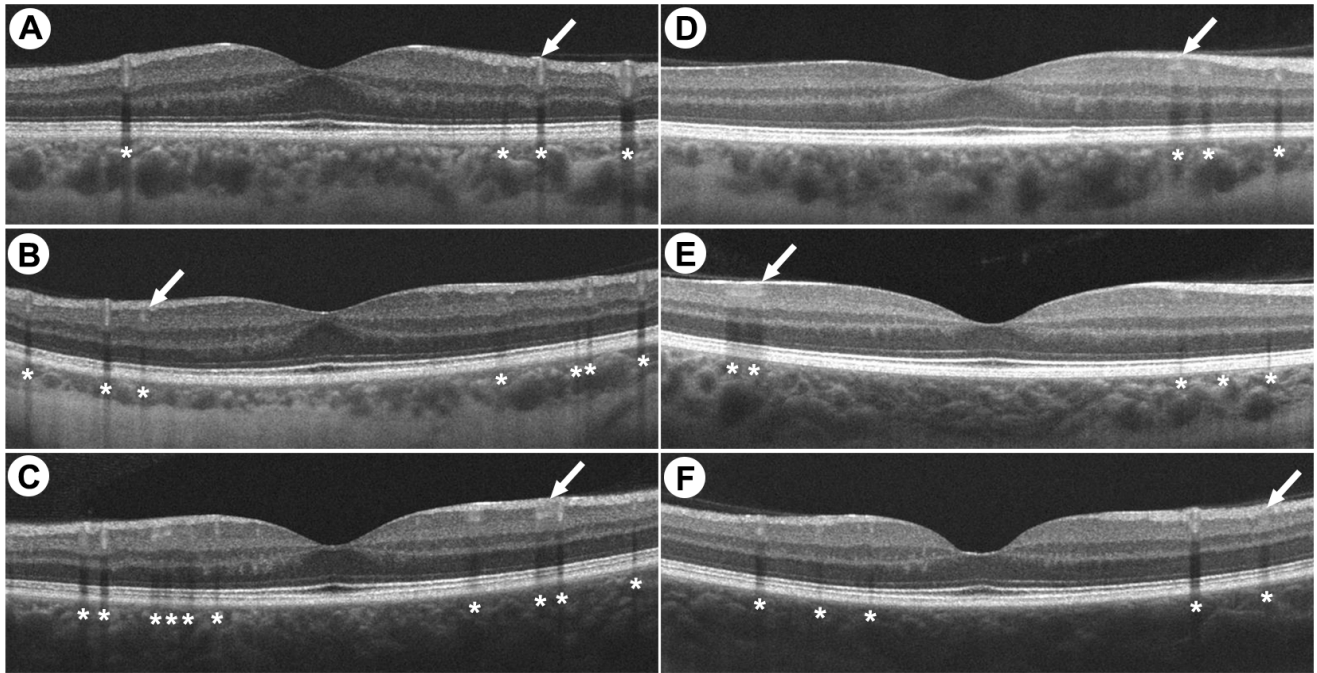


# THE LANCET

## Supplementary appendix

This appendix formed part of the original submission. We post it as supplied by the authors.

Supplement to: Collison FT, Carroll J. Seeking clarity on retinal findings in patients with COVID-19. *Lancet* 2020; **396**: e38.



**Figure: OCT Images Demonstrating Normal Imaging Features from Retinal Blood Vessels**

Panels A-C show OCT B-scans from three males with normal vision (ages 35, 44 and 27 years), while panels D-F show OCT B-scans from three females with normal vision (ages 42, 31 and 32). The hyper-reflective signals in the inner retina similar to those reported by Marinho *et al.* are indicated with arrows. The asterisks identify the shadow generated by the overlying blood vessels.