

THE LANCET

Supplementary appendix

This appendix formed part of the original submission. We post it as supplied by the authors.

Supplement to: Brandão-de-Resende C, Diniz-Filho A, Vasconcelos-Santos DV. Seeking clarity on retinal findings in patients with COVID-19. *Lancet* 2020; **396**: e37.

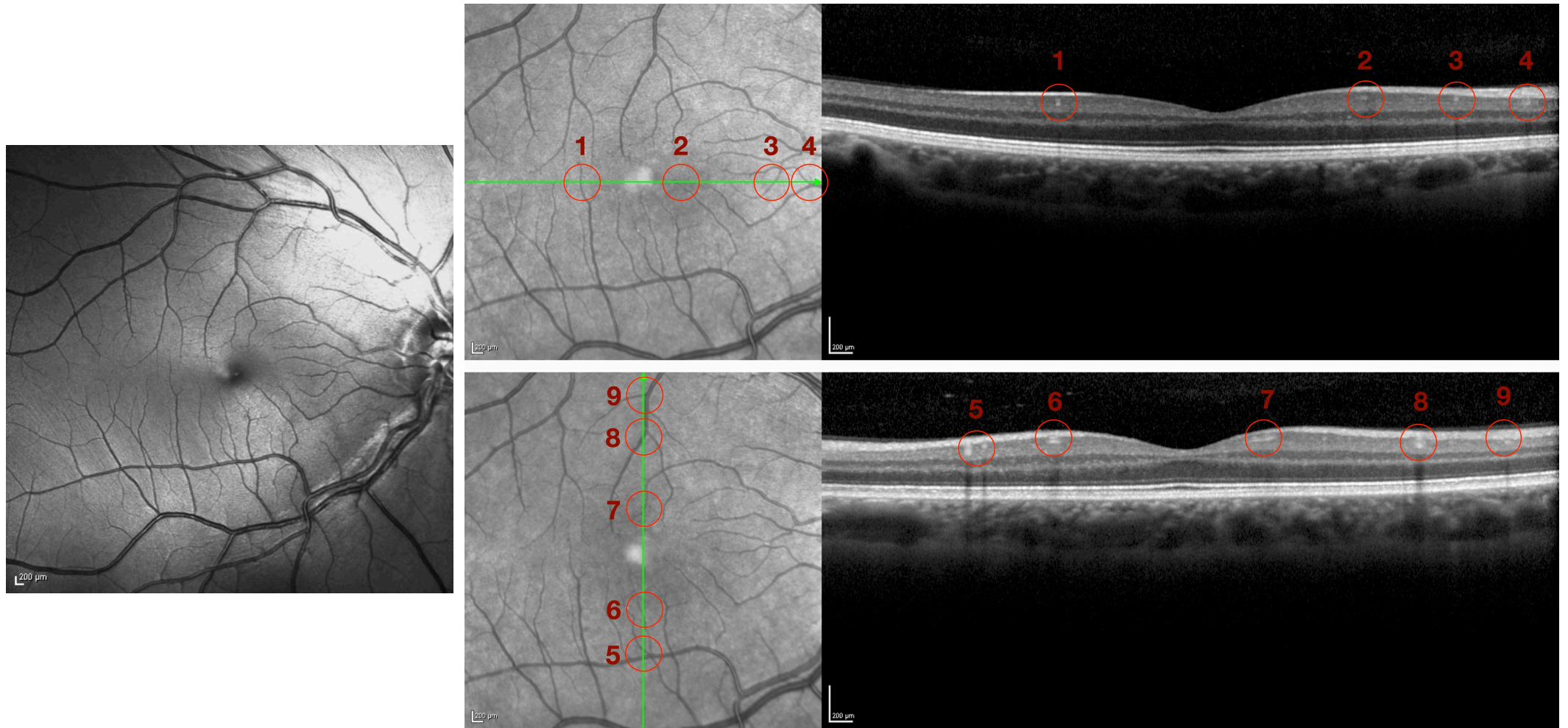


Figure: Tomographic correlations of normal macular blood vessels

Red-free (left) and near-infrared images (middle top and bottom), and corresponding horizontal (top right) and vertical (bottom right) optical coherence tomography sections of one of the authors (DVVS) normal right macula. Correlation of near-infrared images to OCT sections demonstrates that the highly hyper-reflective lesions in the ganglion cell layer nicely correspond to cross and oblique sections of macular blood vessels (numbered red circles).