

# THE LANCET

## Supplementary appendix

This appendix formed part of the original submission. We post it as supplied by the authors.

Supplement to: Ouyang P, Zhang X, Peng Y, Jiang B. Seeking clarity on retinal findings in patients with COVID-19. *Lancet* 2020; **396**: e35.

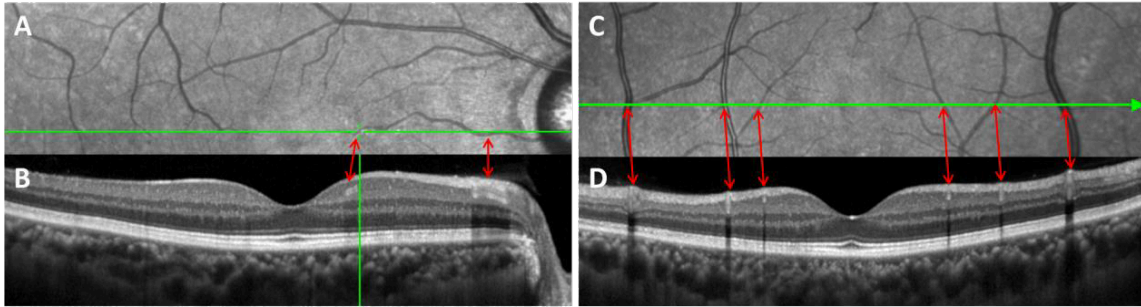


Figure: Normal retinal blood vessels in one healthy eye shown in OCT

Panels A-D are from the same eye of one healthy person. A and C are infrared fundus images. B and D are corresponding OCT images to A and C respectively. The red two-way arrows correspond the blood vessels on the infrared fundus images to those on the OCT. B shows the longitudinal sections of the vessels and D shows the cross sections of the vessels. The three characteristics of the retinal blood vessels in OCT images (vessels extension, the tube-like structure and the shadow) are all shown in B and D. OCT=optical coherence tomography.