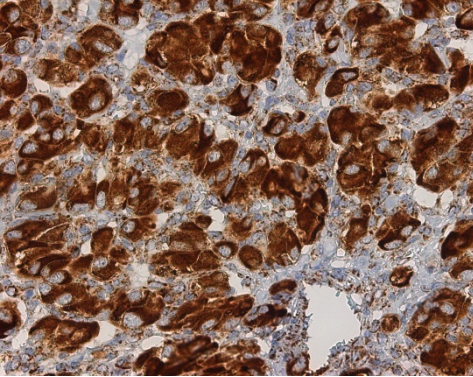
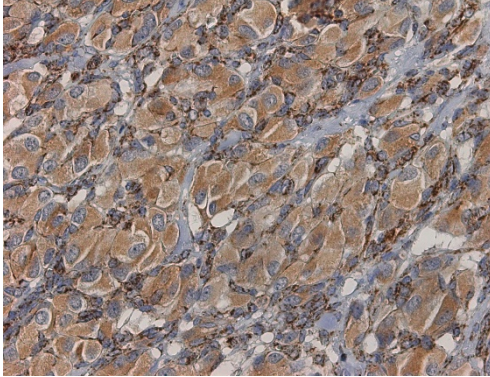
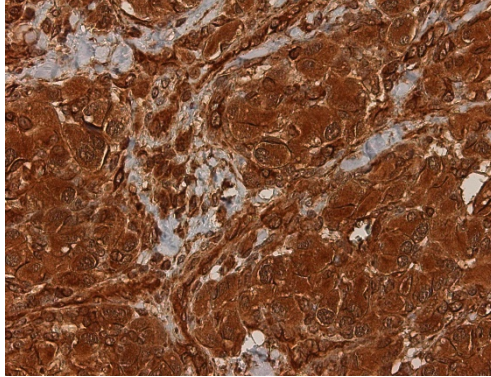
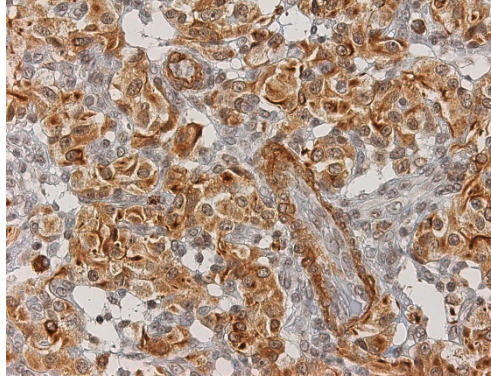
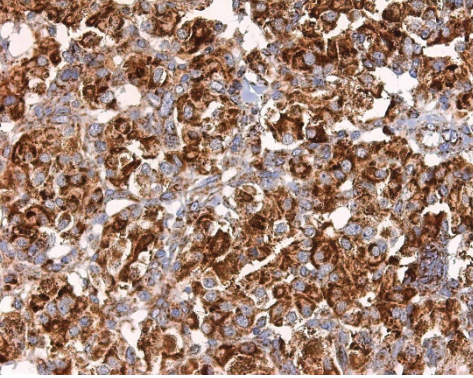
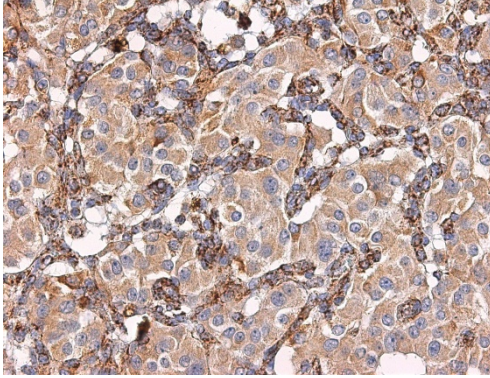
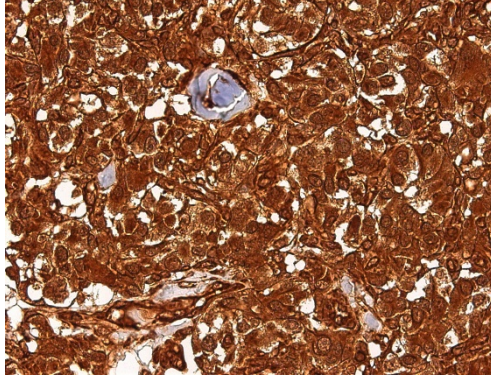
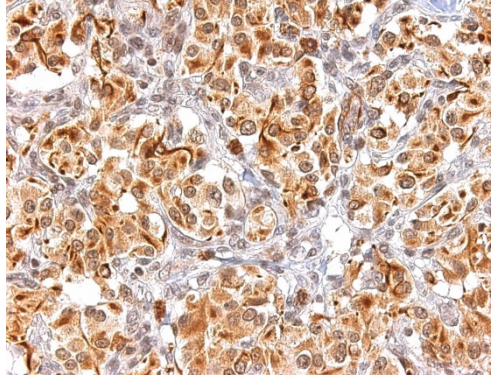
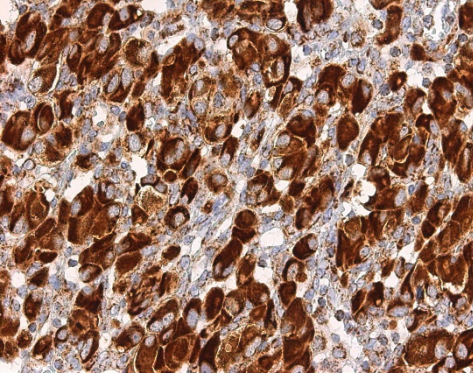
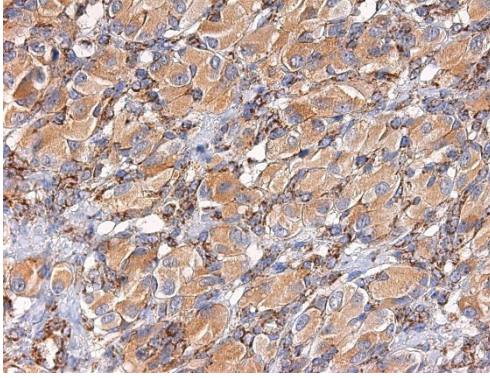
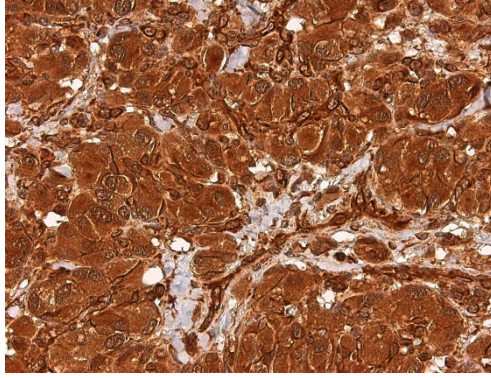
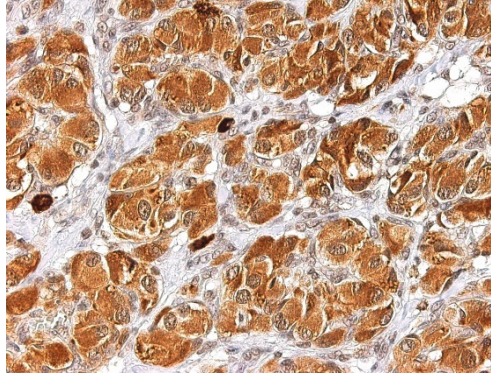


**Immunohistochemical staining of SDH subunits in carotid and vagal paragangliomas**

	<b>SDHA</b>	<b>SDHB</b>	<b>SDHC</b>	<b>SDHD</b>
<b>Left CPGL</b>	 <p>Positive</p>	 <p>Weak diffuse</p>	 <p>Positive</p>	 <p>Positive (weak)</p>
<b>Right CPGL</b>	 <p>Positive</p>	 <p>Weak diffuse</p>	 <p>Positive</p>	 <p>Positive (weak)</p>
<b>Right VPGL</b>	 <p>Positive</p>	 <p>Weak diffuse</p>	 <p>Positive</p>	 <p>Positive (weak)</p>