

Supplementary Materials

Novel missense *CACNA1G* mutations associated with infantile-onset developmental and epileptic encephalopathy

Géza Berecki, Katherine L. Helbig, Tyson L Ware, Bronwyn Grinton, Cara M. Skraban, Eric D. Marsh, Samuel F. Berkovic and Steven Petrou

Case 1 (*CACNA1G* variant c.2727G>C; p.L909F)

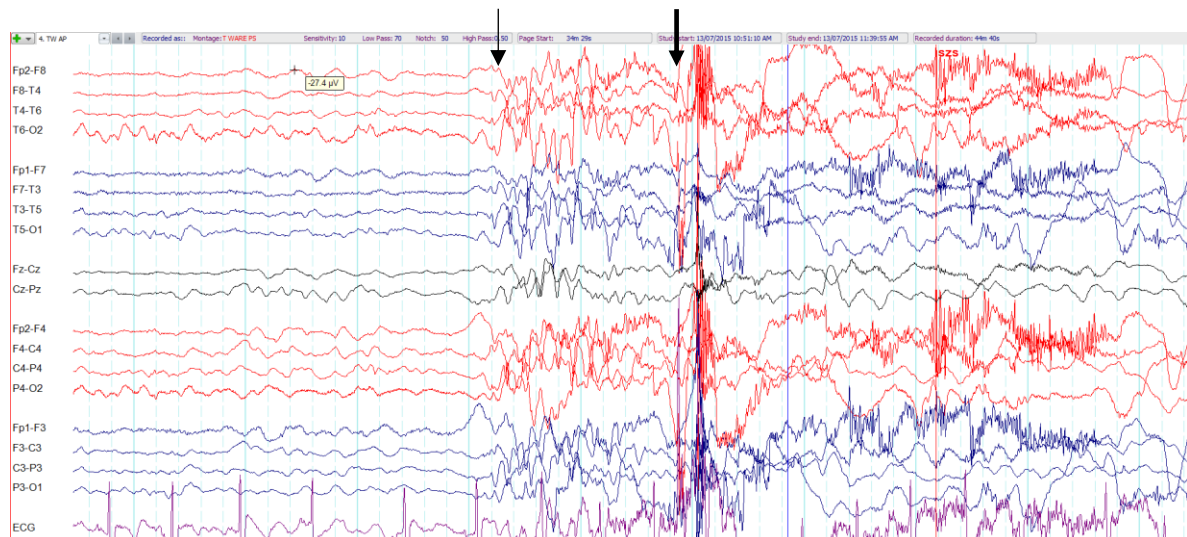


Figure S1. Electroencephalogram (EEG) of case 1 at age 5 years showing a burst of irregular generalized polyspike wave discharges (thin arrow) followed by a brief tonic seizure with generalized paroxysmal fast activity (thick arrow) contaminated by muscle artefact.