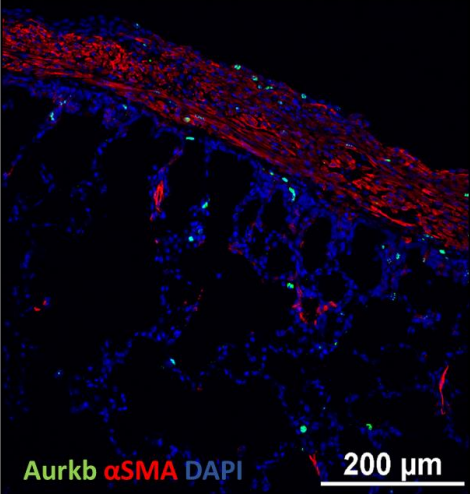
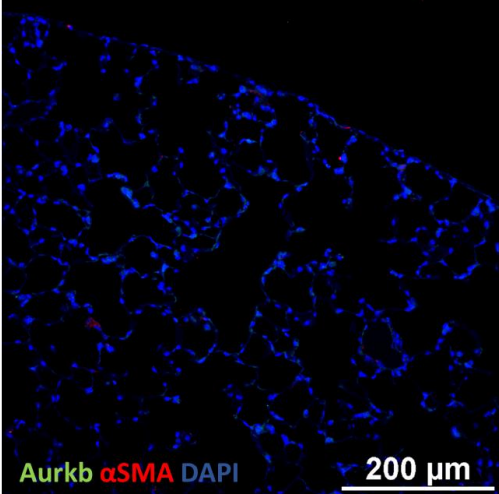


Figure 3

Panel H: Low magnification images

Normal Lung

Fibrotic Lung



Panel C: Negative control

Panel H: Negative control

