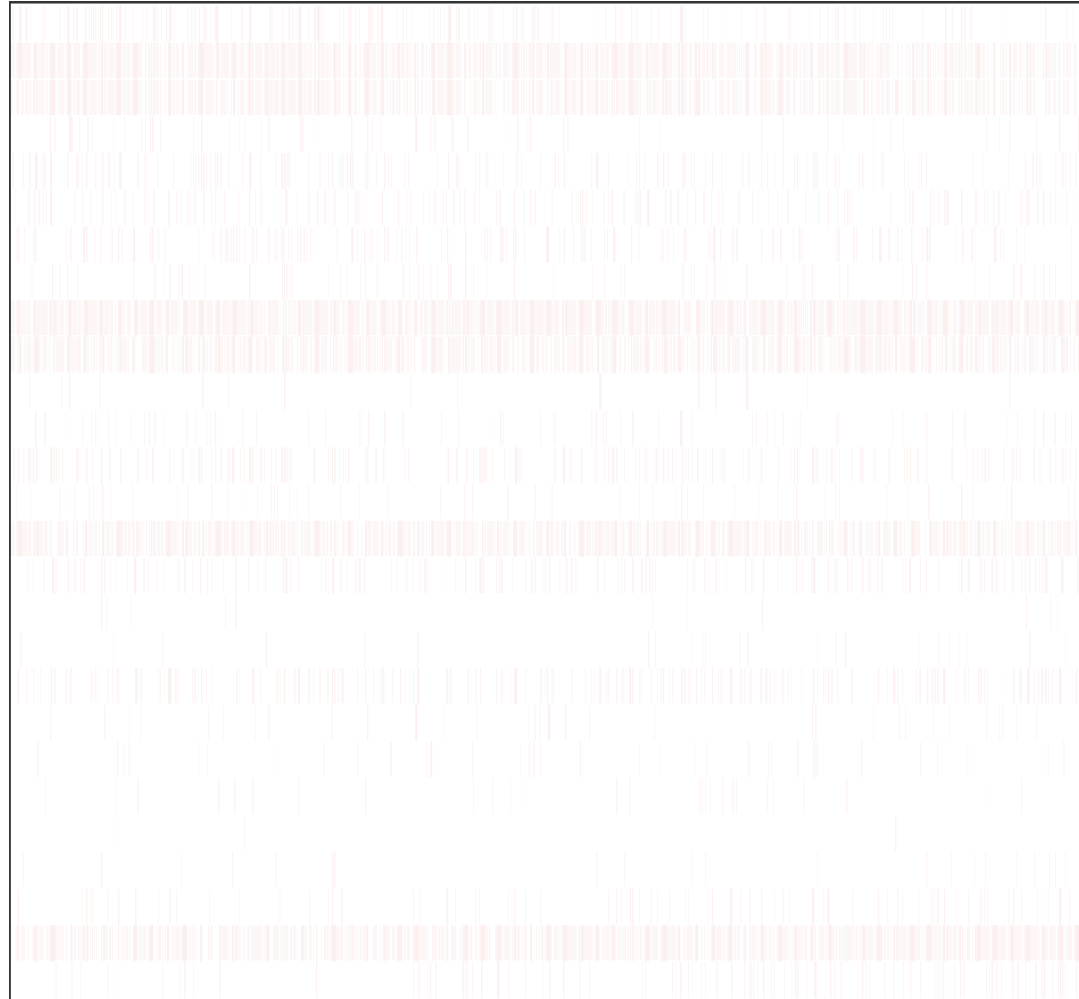


Clinical characteristics

Infiltrating Lobular Carcinoma ($p = 2e-08$)
ER Positive ($p = 4.6e-08$)
PR Positive ($p = 1.4e-05$)
Asian Race ($p = 0.37$)
Large Tumor Size ($p = 0.64$)
HER2 Equivocal ($p = 1$)
HER2 Positive ($p = 1$)
Positive Margins ($p = 1$)
Negative Margins ($p = 1$)
Post Menopause ($p = 1$)
Mucinous Carcinoma ($p = 1$)
Extensive Node Involvement ($p = 1$)
Late Stage ($p = 1$)
History Other Malignancy ($p = 1$)
White Race ($p = 1$)
Black or African-American Race ($p = 1$)
Sex Male ($p = 1$)
Close Margins ($p = 1$)
Pre Menopause ($p = 1$)
Peri Menopause ($p = 1$)
Other Histology ($p = 1$)
Mixed Histology ($p = 1$)
Metaplastic Carcinoma ($p = 1$)
Has Distant Metastasis ($p = 1$)
Early Onset Diagnosis ($p = 0.44$)
Infiltrating Ductal Carcinoma ($p = 1.8e-05$)
Triple Negative ($p = 4.7e-09$)



Patient