

Supplemental Material

Supplemental Table 1. Immunofluorescence report.

Supplemental Table 2. Final diagnoses of the kidney biopsies.

Supplemental Table 3. Numeric distribution of the immunofluorescence features.

Supplemental Table 4. Percent distribution of the immunofluorescence features.

Supplemental Table 5. Ground truth agreement between pathologists and Convolutional Neural Networks.

Supplemental Table 6. Inter-agreement Cohen's K of each feature.

Supplemental Table 7. Comparison of the report of a case of Lupus Nephritis (Supplemental Figure 4) between Ground Truth and Convolutional Neural Networks (CNN).

Supplemental Table 8. Ground truth agreement between pathologists and Convolutional Neural Networks.

Supplemental Figure 1. Classification of the '*Appearance*' of the deposits of the Immunofluorescence specimen.

Supplemental Figure 2. Classification of the '*Distribution*' of the deposits of the Immunofluorescence specimen.

Supplemental Figure 3. Classification of the '*Location*' of the deposits of the Immunofluorescence specimen.

Supplemental Figure 4. IgG direct Immunofluorescence of a Lupus Nephritis case.

Supplemental Figure 5. IgG direct Immunofluorescence of a Light Chain deposition disease.

Supplemental Table 1. Immunofluorescence report.

			IgG	IgA	IgM	C1q	C3	F	Kappa	Lambda
GLOMERULI	appearance	linear								
		pseudolinear								
		coarse granular								
		fine granular								
	distribution	diffuse/segmental								
		diffuse/global								
		focal/segmental								
		focal/global								
	location	mesangial								
		capillary wall								
		continuous regular capillary wall (subepithelial)								
		capillary wall regular discontinuous								
		irregular capillary wall (subendothelial)								
		INTENSITY								

The immunofluorescence report adopted at our center describes the *'Appearance'*, *'Distribution'* and *'Location'* of immune deposits. Furthermore, the *'Intensity'* of staining is described by a semi-quantitative rank with discrete values from 0 to 3 (by 0.5 intervals). The report includes the evaluation of IgG, IgA, IgM immunoglobulins, complement fractions C1Q, C3, Fibrinogen, Kappa and Lambda light chains.

Supplemental Table 2. Final diagnoses of the kidney biopsies.

Diagnosis	Freq	Percent
IgA Nephropathy	401	16%
Membranous Glomerulonephritis	232	9%
Mesangial Proliferative Glomerulonephritis without immune deposits	150	6%
Diabetic Nephropathy	146	6%
Mesangial Proliferative Glomerulonephritis with IgM Deposits	134	5%
Chronic Interstitial Nephritis	111	4%
Unclassified Nephropathy	98	4%
Membranoproliferative Glomerulonephritis	78	3%
Benign Nephroangiosclerosis	65	3%
Lupus Nephritis	64	3%
Other Diagnoses	1063	41%
Total	2225	100%

Supplemental Table 3. Numeric distribution of the immunofluorescence features.

			IgG	IgA	IgM	C1q	C3	F	Kappa	Lambda	Overall
GLOMERULI	appearance	linear	28	11	4	1	6	10	9	19	88
		pseudolinear	139	75	18	2	14	22	45	20	335
		coarse granular	55	78	277	87	260	28	74	127	986
		fine granular	171	126	109	43	182	41	135	165	972
	distribution	diffuse/segmental	50	91	265	67	138	52	57	96	816
		diffuse/global	565	734	656	279	987	370	618	937	5146
		focal/segmental	32	61	209	59	134	71	37	51	654
		focal/global	15	22	59	14	43	11	9	23	196
	location	mesangial	154	682	556	183	661	186	292	613	3327
		capillary wall	158	301	318	95	305	264	158	300	1899
		continuous regular capillary wall (subepithelial)	365	135	116	87	295	67	291	341	1697
		discontinuous regular capillary wall	17	17	35	14	97	13	14	25	232
		irregular capillary wall (subendothelial)	93	135	514	183	378	83	131	207	1724

Supplemental Table 4. Percent distribution of the immunofluorescence features.

			IgG	IgA	IgM	C1q	C3	F	Kappa	Lambda
GLOMERULI	appearance	linear	0.96%	0.38%	0.14%	0.03%	0.20%	0.34%	0.31%	0.65%
		pseudolinear	5%	3%	0.61%	0.07%	0.48%	0.75%	1%	0.68%
		coarse granular	2%	3%	9%	3%	9%	0.96%	3%	4%
		fine granular	6%	4%	4%	1%	6%	1%	5%	6%
	distribution	diffuse/segmental	2%	3%	9%	2%	5%	2%	2%	3%
		diffuse/global	19%	25%	22%	10%	34%	13%	21%	33%
		focal/segmental	1%	2%	7%	2%	5%	2%	1%	2%
		focal/global	1%	1%	2%	0.48%	1%	0.38%	0.31%	0.78%
	location	mesangial	5%	23%	19%	6%	23%	6%	10%	21%
		capillary wall	5%	10%	11%	3%	10%	9%	5%	10%
		continuous regular capillary wall (subepithelial)	12%	5%	4%	3%	10%	2%	10%	12%
		discontinuous regular capillary wall	0.58%	0.58%	1%	0.48%	3%	0.44%	0.48%	0.85%
		irregular capillary wall (subendothelial)	3%	5%	18%	6%	13%	3%	4%	7%

Supplemental Table 5. Ground truth agreement between pathologists and Convolutional Neural Network.

Agreement between human evaluators (three different pathologists) and Convolutional Neural Networks was calculated by the Cohen's Kappa (Kappa \pm standard deviation of 20 test images per feature).

	Feature	Pathologist 1 vs Ground Truth	Pathologist 2 vs Ground Truth	Pathologist 3 vs Ground Truth	CNN vs Ground Truth
Appearance	coarse granular	0.40 \pm 0.20	0.50 \pm 0.21	0.60 \pm 0.20	0.40 \pm 0.24
	fine granular	0.30 \pm 0.16	0.30 \pm 0.22	0.20 \pm 0.22	0.30 \pm 0.25
Distribution	segmental	0.41 \pm 0.20	0.50 \pm 0.21	0.10 \pm 0.22	0.20 \pm 0.25
	global	0.67 \pm 0.21	0.40 \pm 0.18	0.60 \pm 0.22	0.60 \pm 0.21
Location	mesangial	0.80 \pm 0.22	0.50 \pm 0.21	0.50 \pm 0.21	0.90 \pm 0.11
	capillary wall	0.60 \pm 0.22	0.40 \pm 0.22	0.40 \pm 0.22	0.50 \pm 0.22
	continuous regular capillary wall	0.60 \pm 0.20	0.40 \pm 0.18	0.50 \pm 0.22	0.60 \pm 0.21
	irregular capillary wall	0.30 \pm 0.22	0.40 \pm 0.20	0.20 \pm 0.20	0.40 \pm 0.24

Supplemental Table 6. Inter-agreement Cohen's K of each feature.

Pathologist 1, 2, 3 (Pat.1, Pat. 2, Pat. 3); Ground Truth (GT); Convolutional Neural Network (CNNs).

Mesangial	GT	CNNs	Pat.1	Pat.2
Pat.3	0.50 ± 0.22	0.59 ± 0.21	0.70 ± 0.18	0.34 ± 0.26
Pat.2	0.50 ± 0.22	0.59 ± 0.21	0.50 ± 0.22	
Pat.1	0.80 ± 0.15	0.70 ± 0.18		
CNNs	0.90 ± 0.11			
Capillary wall	GT	CNNs	Pat.1	Pat.2
Pat.3	0.40 ± 0.24	0.70 ± 0.18	0.60 ± 0.21	0.60 ± 0.21
Pat.2	0.40 ± 0.24	0.90 ± 0.11	0.42 ± 0.23	
Pat.1	0.60 ± 0.21	0.51 ± 0.22		
CNNs	0.50 ± 0.22			
Continuous Regular Capillary wall	GT	CNNs	Pat.1	Pat.2
Pat.3	0.50 ± 0.22	0.31 ± 0.24	0.52 ± 0.21	0.34 ± 0.23
Pat.2	0.40 ± 0.24	0.32 ± 0.27	0.74 ± 0.20	
Pat.1	0.60 ± 0.21	0.57 ± 0.22		
CNNs	0.60 ± 0.21			
Irregular Capillary wall	GT	CNNs	Pat.1	Pat.2
Pat.3	0.20 ± 0.25	0.40 ± 0.24	0.48 ± 0.23	0.52 ± 0.24
Pat.2	0.40 ± 0.24	0.40 ± 0.24	0.48 ± 0.23	
Pat.1	0.30 ± 0.25	0.30 ± 0.25		
CNNs	0.40 ± 0.24			
Coarse Granular	GT	CNNs	Pat.1	Pat.2
Pat.3	0.60 ± 0.21	0.76 ± 0.18	0.76 ± 0.18	0.66 ± 0.21
Pat.2	0.50 ± 0.22	0.89 ± 0.13	0.66 ± 0.21	
Pat.1	0.40 ± 0.24	0.76 ± 0.18		
CNNs	0.40 ± 0.24			
Fine Granular	GT	CNNs	Pat.1	Pat.2
Pat.3	0.20 ± 0.25	0.30 ± 0.25	0.30 ± 0.25	0.70 ± 0.18
Pat.2	0.30 ± 0.25	0.35 ± 0.25	0.35 ± 0.25	
Pat.1	0.10 ± 0.26	0.61 ± 0.30		
CNNs	0.30 ± 0.25			
Segmental	GT	CNNs	Pat.1	Pat.2
Pat.3	0.10 ± 0.26	0.06 ± 0.27	0.42 ± 0.23	0.18 ± 0.26

Pat.2	0.50 ± 0.22	0.43 ± 0.25	0.45 ± 0.22
Pat.1	0.30 ± 0.25	0.38 ± 0.22	
CNNs	0.20 ± 0.25		

Global	GT	CNNs	Pat.1	Pat.2
Pat.3	0.60 ± 0.21	0.35 ± 0.26	0.67 ± 0.20	0.55 ± 0.23
Pat.2	0.40 ± 0.24	0.47 ± 0.27	0.86 ± 0.16	
Pat.1	0.50 ± 0.22	0.38 ± 0.28		
CNNs	0.60 ± 0.21			

Supplemental Table 7. Comparison of the report of a case of Lupus Nephritis (Supplemental Figure 4) between Ground Truth and Convolutional Neural Network (CNN).

			IgG Ground Truth	IgG CNN	
GLOMERULI	appearance	linear			
		pseudolinear			
		coarse granular			
		fine granular	yes		
	distribution	segmental			
		global	yes	yes	
	location	mesangial			
		capillary wall			
		continuous regular capillary wall (subepithelial)	yes	yes	
		discontinuous regular capillary wall			
			irregular capillary wall (subendothelial)		
		Intensity	3	3	


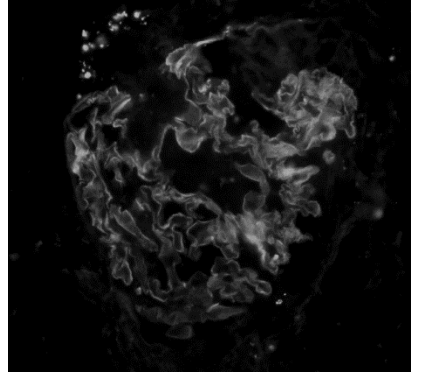

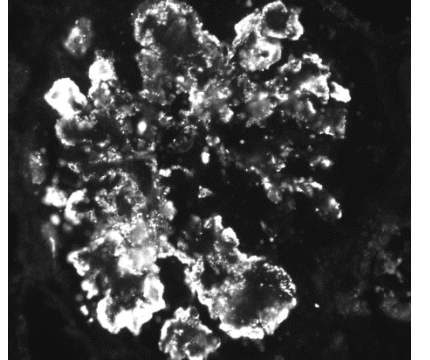

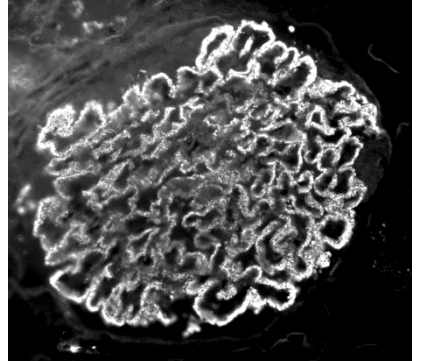
The Convolutional Neural Network could correctly recognize the deposits of the tuft (except for the fine granular appearance) despite of the presence of the extraglomerular deposits.

Supplemental Table 8. Ground truth agreement between pathologists and Convolutional Neural Networks.


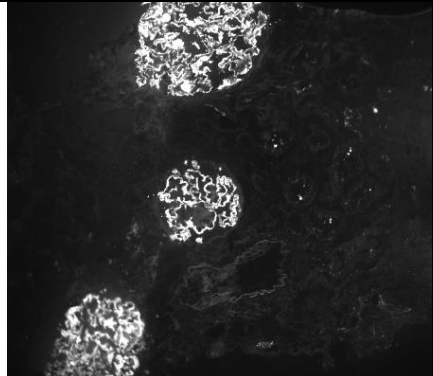

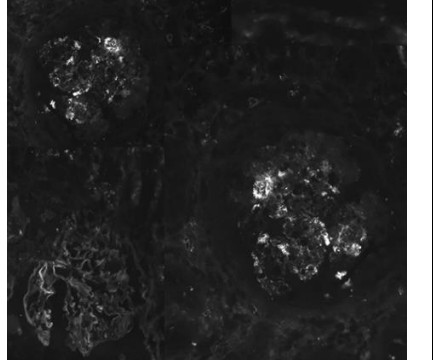

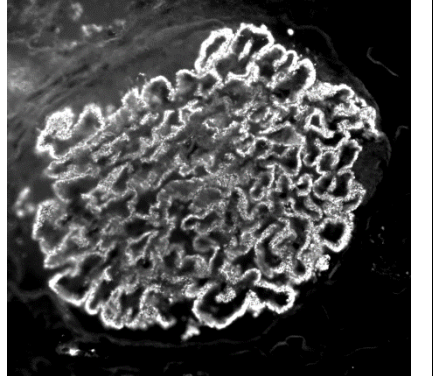

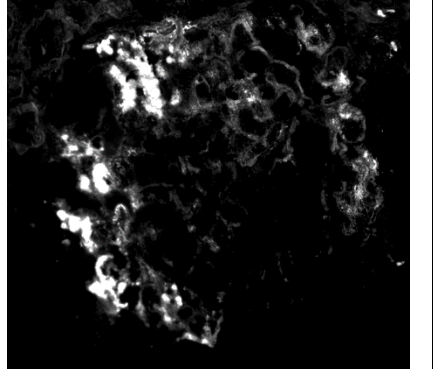
			Lambda Light Chain Ground Truth	Lambda Light Chain CNN	
GLOMERULI	appearance	linear	yes		
		pseudolinear			
		coarse granular			
		fine granular			
	distribution	segmental			
		global	yes	yes	
	location	mesangial			
		capillary wall	yes	yes	
		continuous regular capillary wall (subepithelial)			
		discontinuous regular capillary wall			
			irregular capillary wall (subendothelial)		
		Intensity	3	3	

The Convolutional Neural Network (CNN) could correctly recognize the deposits of the tuft despite of the presence of the extraglomerular deposits. The Convolutional Neural Network could not recognize the linear appearance because it was not trained for this task.


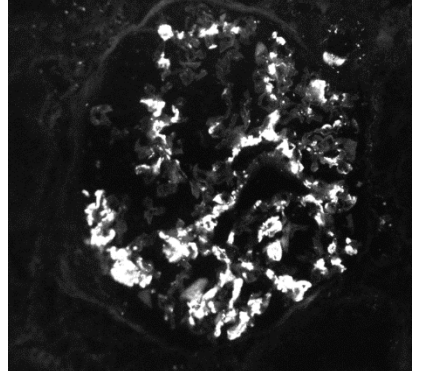

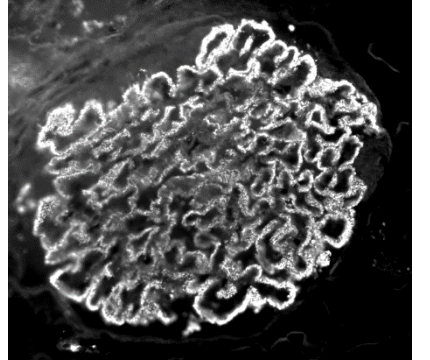

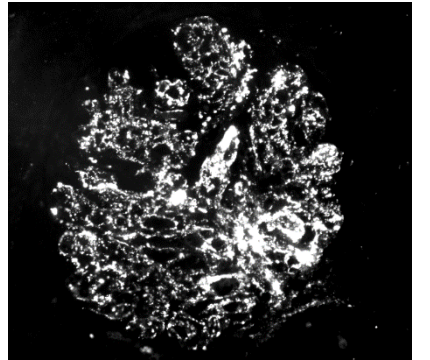

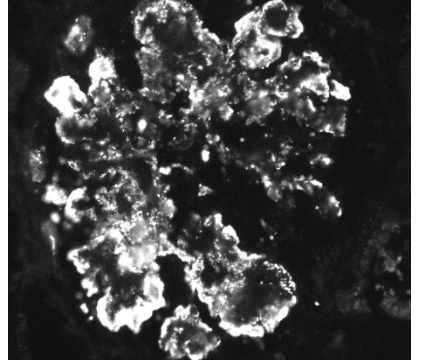
Supplemental Figure 1. Classification of the 'Appearance' of the deposits of the Immunofluorescence specimen ¹⁻³.

APPEARANCE		
LINEAR and PSEUDO-LINEAR	Scheme	Example
<p>The presence of the linear pattern is characteristic of the deposition of antibody against components of the glomerular basement membrane (GBM). The presence of circulant IgG against GBM is typical of the Goodpasture's syndrome ⁴. Linear staining is also reported in diabetic nephropathy (pseudolinear) along the glomerular capillary walls with immunoglobulin G (IgG). In membranous glomerulonephritis the deposits are usually discrete and uniform, but in some cases, especially at the initial stage of the disease, they are small and confluent. In these instances, they could have a pseudolinear appearance.</p>		
COARSE GRANULAR	Scheme	Example
<p>Coarse granularity can be identified in different conditions. For example, this pattern can be found in the deposits of membranoproliferative lesions and in the sub-epithelial deposits of postinfectious glomerulonephritis.</p>		
FINE GRANULAR	Scheme	Example
<p>Fine granularity as opposed to coarse granularity has smaller diameter deposits. This condition can, for example, be observed in the deposits of the membranous glomerulonephritis at the initial stages.</p>		

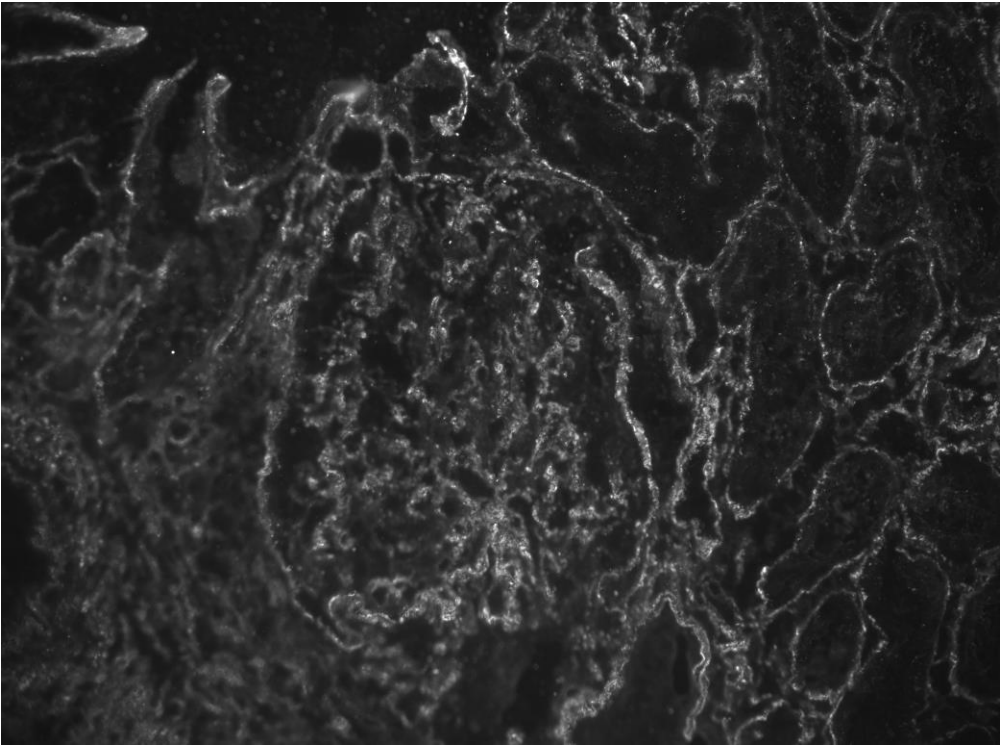
Supplemental Figure 2. Classification of the 'Distribution' of the deposits of the Immunofluorescence specimen ¹⁻³.

DISTRIBUTION		
<p>DIFFUSE</p> <p>The term 'diffuse' describes a lesion that is involving more than 50% of glomeruli.</p>	<p>Scheme</p> 	<p>Example</p> 
<p>FOCAL</p> <p>Focal describes a lesion that is involving less than 50% of glomeruli.</p>	<p>Scheme</p> 	<p>Example</p> 
<p>GLOBAL</p> <p>The term 'global' describes a lesion that involves all of a glomerular tuft.</p>	<p>Scheme</p> 	<p>Example</p> 
<p>SEGMENTAL</p> <p>The term 'segmental' describes a lesion that involves part of a glomerular tuft.</p>	<p>Scheme</p> 	<p>Example</p> 

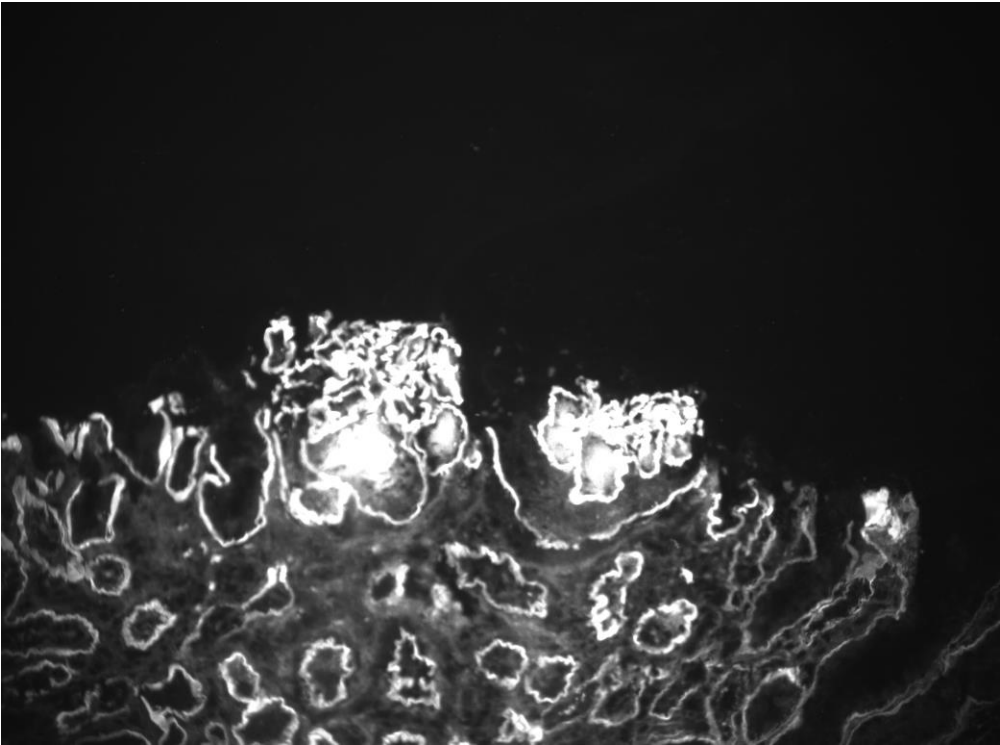
Supplemental Figure 3. Classification of the 'Location' of the deposits of the Immunofluorescence specimen ¹⁻³.

LOCATION		
MESANGIAL	Scheme	Example
<p>Mesangial deposition of immunoglobulin is the typical pattern of the IgA Nephropathy. However, mesangial deposition can be founded in other conditions such as membranoproliferative glomerulonephritis or postinfectious glomerulonephritis.</p>		
CONTINUOUS REGULAR CAPILLARY WALL	Scheme	Example
<p>The regular continuous capillary wall pattern corresponds to the identification of subepithelial deposits possible through ultramicroscopic analysis. This is the typical immunofluorescence finding of Membranous glomerulonephritis: a diffuse global granular deposits of immune reactants that follow the contour of the GBM.</p>		
DISCONTINUOUS REGULAR CAPILLARY WALL	Scheme	Example
<p>This pattern is also described as "bumps and humps" or "lumpy-dumpy", traditionally associated with postinfectious glomerulonephritis.</p>		
IRREGULAR CAPILLARY WALL	Scheme	Example
<p>The irregular capillary wall pattern corresponds to the identification of subendothelial deposits, ribbon-like deposits, negative in the mesangium, giving the appearance of lobes. This pattern is frequently associated with membranoproliferative glomerulonephritis.</p>		

Supplemental Figure 4. IgG direct Immunofluorescence of a Lupus Nephritis case (400X). The image shows the presence of regular continuous capillary wall deposits of the glomerulus and basal membrane deposits of the tubules. The Convolutional Neural Network could correctly recognize the deposits of the tuft despite of the presence of the extraglomerular deposits (see Supplemental Table 7).



Supplemental Figure 5. IgG direct Immunofluorescence of a Light Chain deposition disease (400X). The image shows the presence of deposits of the capillary wall of the glomerulus and basal membrane deposits of the tubules. The Convolutional Neural Network could correctly recognize glomerular deposits despite of the presence of the extraglomerular deposits (see Supplemental Table 8).



References

1. Wilson, CB, Dixon, FJ: Diagnosis of immunopathologic renal disease. *Kidney International*, 5: 389-401, 1974.
2. Morel-Maroger, L, Leathem, A, Richet, G: Glomerular abnormalities in nonsystemic diseases. Relationship between findings by light microscopy and immunofluorescence in 433 renal biopsy specimens. *Am J Med*, 53: 170-184, 1972.
3. D'Amico, G, Colasanti, G, Bestetti-Bosisio, M: *Le Glomerulonefriti Primitive* La Medicina Internazionale, 1977.
4. Lerner, RA, Glassock, RJ, Dixon, FJ: The role of anti-glomerular basement membrane antibody in the pathogenesis of human glomerulonephritis. *J Exp Med*, 126: 989-1004, 1967.