

Supplemental material:

Figures legends

Slide #2

Composite of initial lymph node biopsy showing detailed morphologic and immunophenotypic features of blastic proliferation with areas of myeloid and T cell differentiation (by IHC and FC)

H&E demonstrates two distinct sharply defined areas of blast proliferation: with myeloid differentiation, largely confined to connective tissue framework (vCD34+, vCD117+, vMPO+, CD33+, aberrant vCD7+, vCD2+, and vCD79a), and T-cell differentiation, largely confined to paracortical areas (cyt.CD3+, vTdT+, CD7+, vCD2+, vCD5+, vCD4+, vCD8+, v CD1a+, aberrant vCD33+, and vCD79a+). Please note heterogenous expression of lineage associated differentiation antigens by blasts in different areas of the lymph node biopsy and aberrant cross-lineage –antigens expression, consistent with their stem cell derivation with both myeloid and T cell differentiation potential. Furthermore, confinement of blast differentiation to T cell or myeloid differentiation to largely different anatomic areas of lymph node biopsy suggest influence of local lymph node microenvironment (different compartments) on blast differentiation potential. (H&E, CD34, CD117, MPO, TdT objx4; CD33, CD7, CD2, CD5, CD1a, CD4, CD8, CD79a objx40)

H&E sections showing MLAP blast transformation in lymph node with areas of T cell differentiation largely confined to paracortical and cortical areas and myeloid differentiation largely confined to lymph node trabecular connective tissue framework (objx40)

Flow cytometry dot plots of blast population in lymph node showing both T cell and myeloid differentiation, and in addition a small population of blasts with B-cell differentiation potential (CD79a+,CD19+).

Slide #3

FGFR2 IHC in lymph node using monoclonal mouse anti FGFR2 antibody (Abcam ab 582010). Blasts in both areas with T-cell and myeloid differentiation show cytoplasmic FGFR2 expression. Residual lymphocytes in lymph node show no FGFR2 expression. Objx40

ETV6 IHC in lymph node using polyclonal rabbit anti ETV6 polyclonal antibody (Invitrogen PA5-81865). Blasts in both areas with T-cell and myeloid differentiation show nuclear and cytoplasmic ETV6 expression. Residual lymphocytes in lymph node show variable weak nuclear ETV6 expression. Objx40

Slide #4

Consecutive bone marrow biopsies following induction chemotherapy with lymphoid directed regimen with CALG protocol, NADIR marrow and recovery marrow (Fig 3A), myeloid directed regimen with HIDAC/mitoxantrone, NADIR marrow and recovery marrow (Fig 3B), and post decitabine plus venetoclax BM prior ASCT (Fig 3C). All post induction bone marrow biopsies, irrespective of the induction regimen show residual disease, as indicated by increased CD34+ blasts, in a background of fibrosis, indicated by increased reticulin fibrosis.

Slide #5

Bone marrow biopsy, post ASCT showing relapsed acute leukemia with myeloid differentiation (AML), and no evidence of T-cell differentiation. Upper panel: H&E showing different areas with more and less fibrosis as indicated by reticulin stain; in more cellular areas increased eosinophils and numerous CD34+ blasts with clustering, c/w relapsed AML. Obj x10, x40. Middle panel: H&E showing peritrabecular proliferation of spindle cells, CD33+, vCD117+, vCD25+, variable mast cell tryptase +, consistent with immature mast cells (objx40).

Slide #6

Cytospin preparation of peritoneal fluid showing numerous large blasts with monocytic differentiation. Flow cytometry dot plots of blast population with CD45 moderate and high side scattered showing monocytic differentiation with a population of CD64+ blasts and a population of CD64+CD36+ blasts, and coexpression of CD33 and CD34+(subset). The blasts show no evidence of T-cell differentiation, as demonstrated on CD3 vs MPO dot plot which shows only a small population of mature T cells, but no blasts with cyt. CD3 expression.

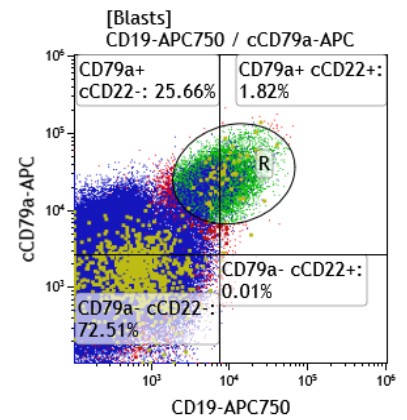
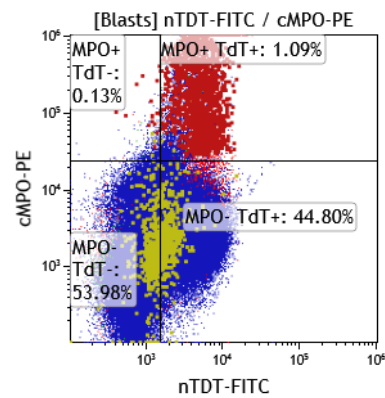
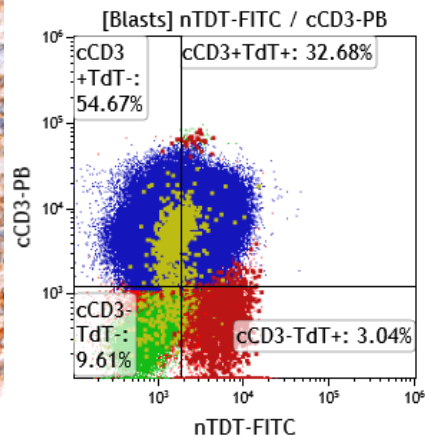
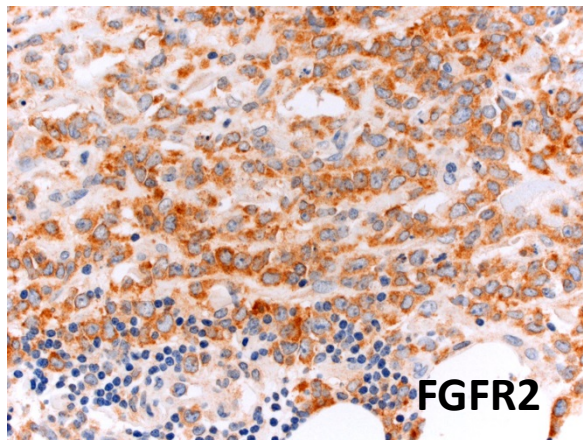
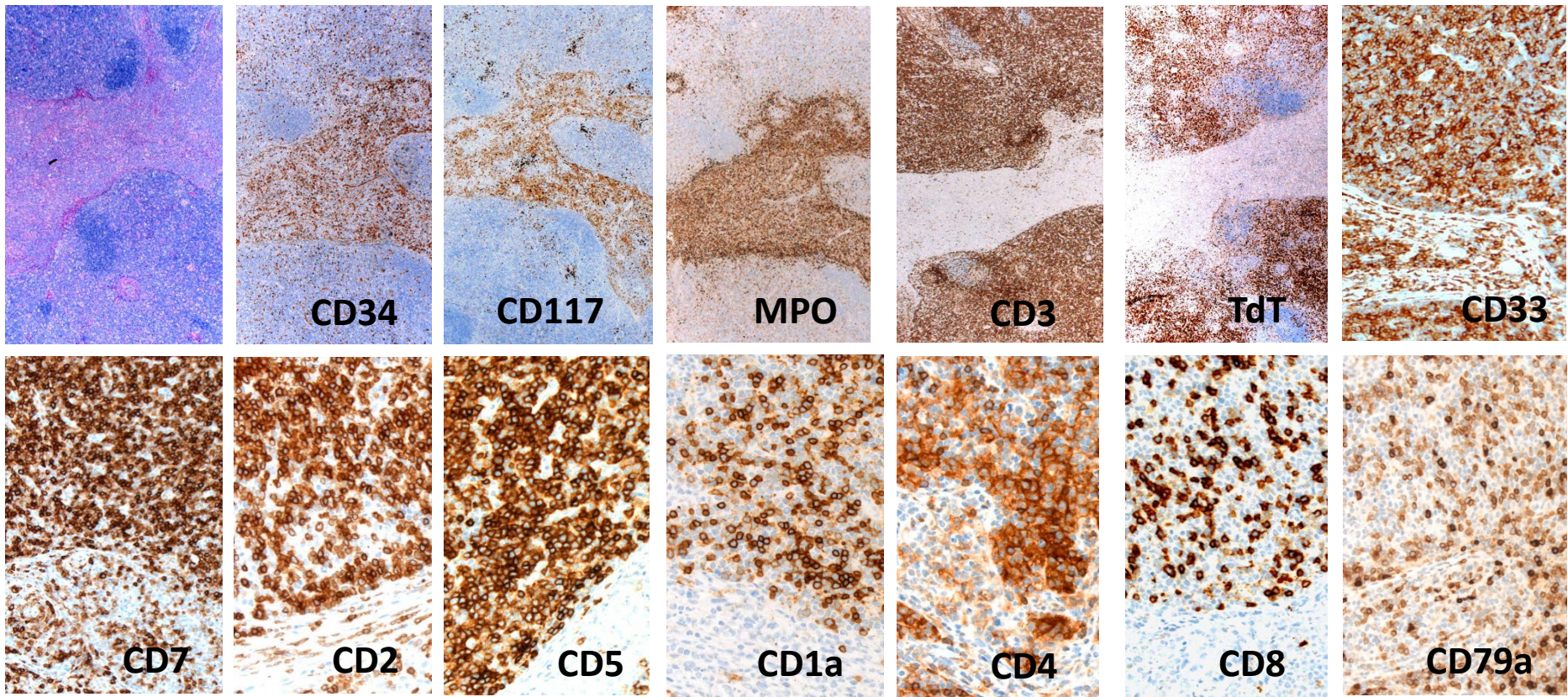
Slide #7

FGFR2 IHC in BM 8, s/p ASCT with recurrent AL with myeloid differentiation, using monoclonal mouse anti FGFR2 antibody (Abcam ab 582010). Blasts with myeloid differentiation, as shown in Fig 4B, demonstrate cytoplasmic FGFR2 expression. Residual hematopoietic cells (erythroid precursors) show no FGFR2 expression. Objx40

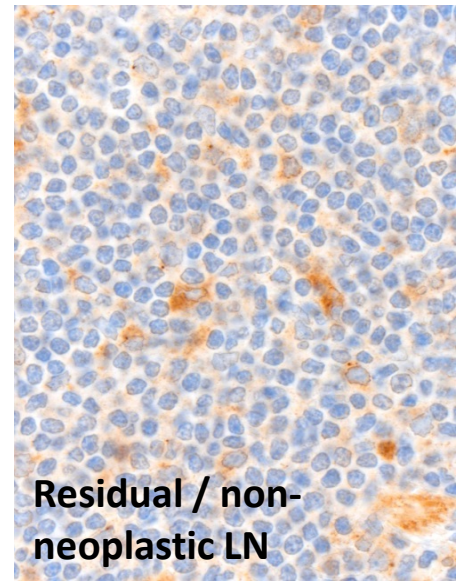
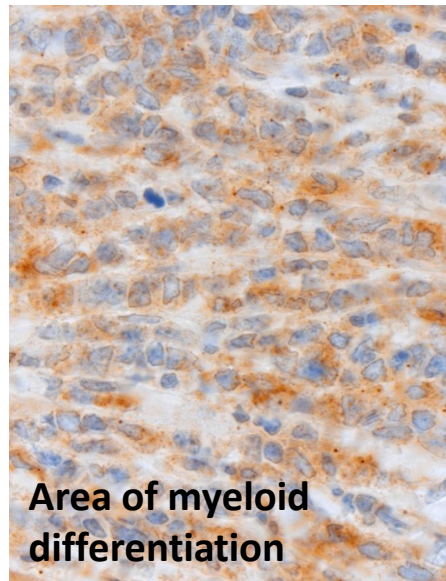
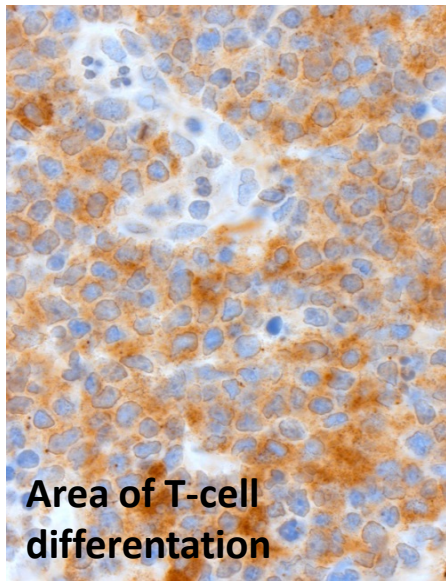
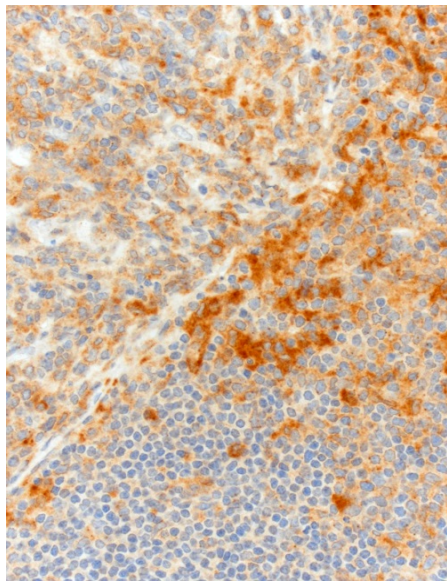
ETV6 IHC in BM 8, s/p ASCT with recurrent AL with myeloid differentiation, using polyclonal rabbit anti ETV6 polyclonal antibody (Invitrogen PA5-81865). Blasts with myeloid differentiation, as shown in Fig 4B demonstrate nuclear and cytoplasmic ETV6 expression. Residual hematopoietic cells (erythroid precursors and maturing granulocytic precursors show variable nuclear ETV6 expression but no aberrant cytoplasmic ETV6 expression. Objx40

ETV6-FGFR2

Supplemental material.



Initial diagnosis lymph node and flow cytometry

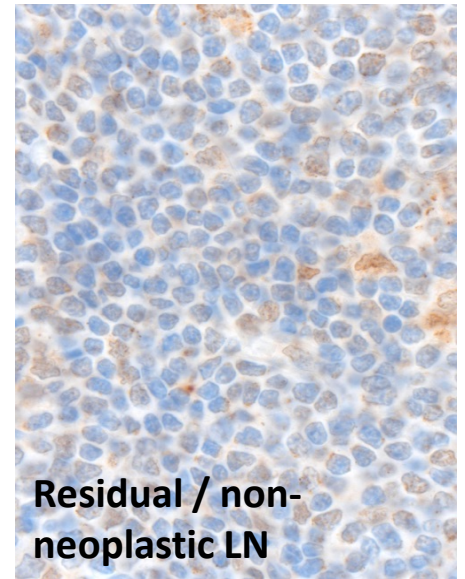
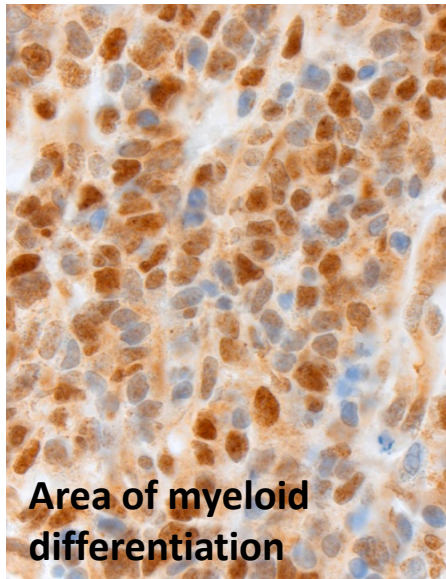
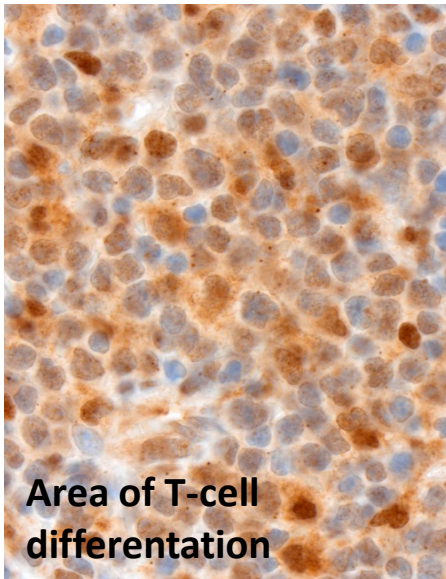
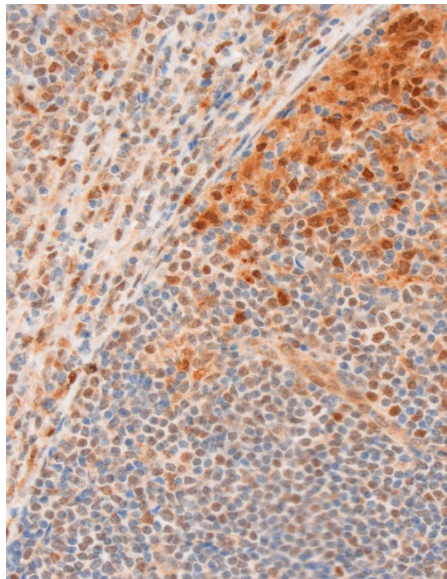


Area of T-cell differentiation

Area of myeloid differentiation

Residual / non-neoplastic LN

Lymph node: FGFR2 IHC

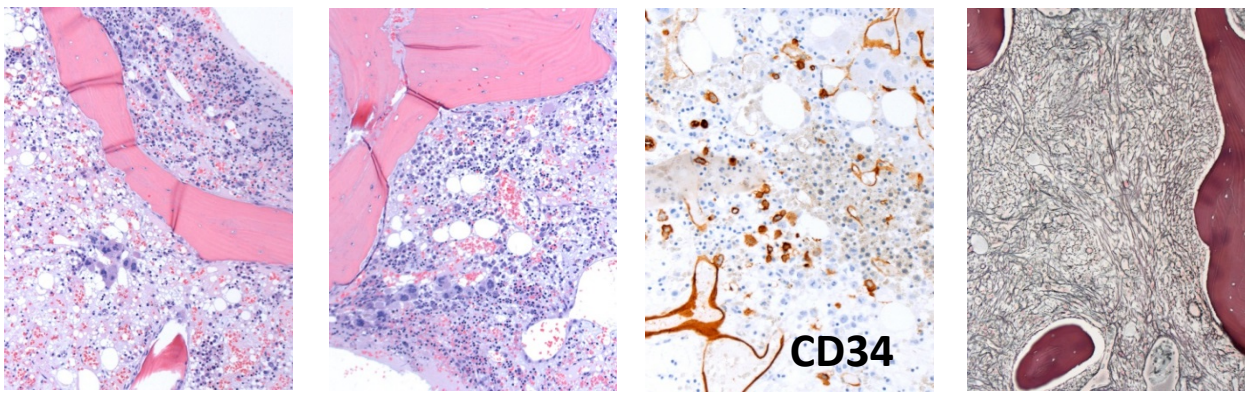


Area of T-cell differentiation

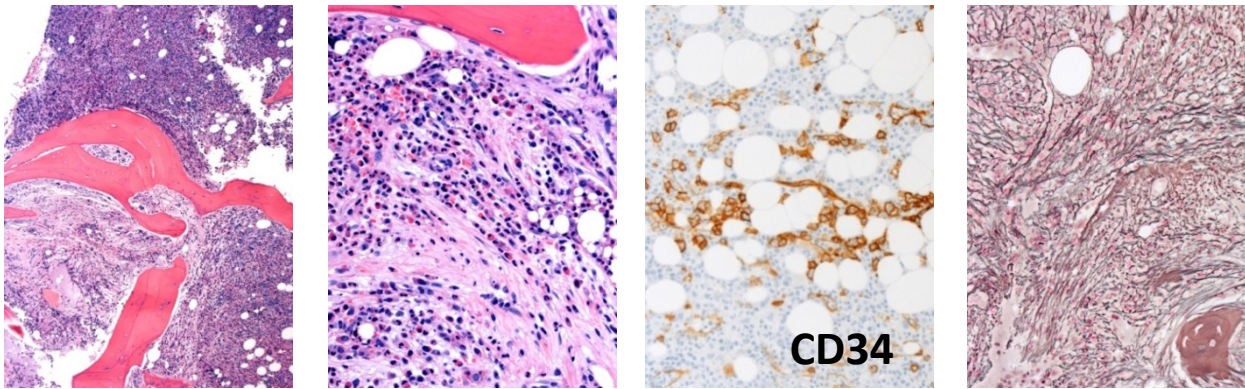
Area of myeloid differentiation

Residual / non-neoplastic LN

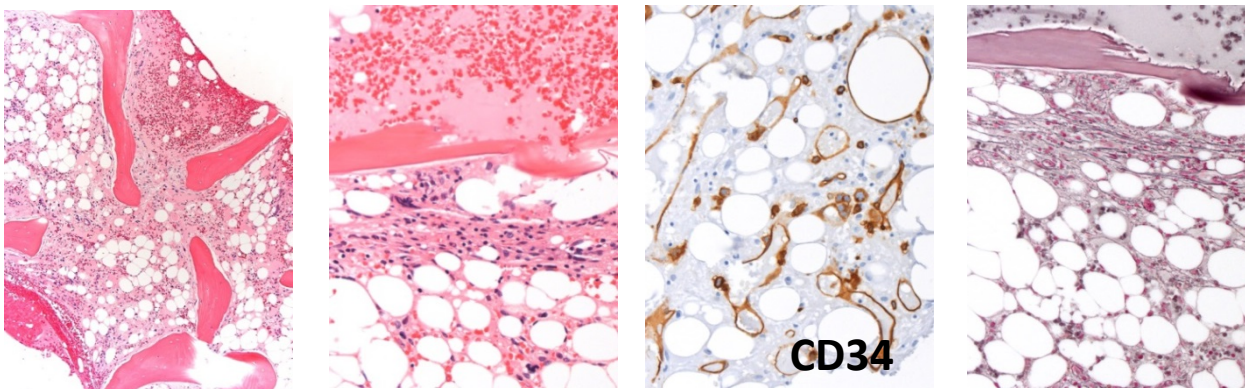
Lymph node: ETV6 IHC



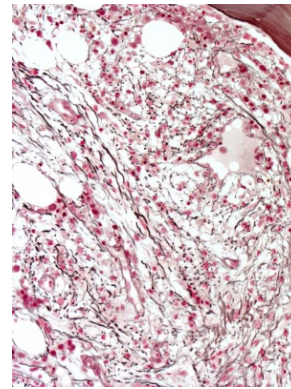
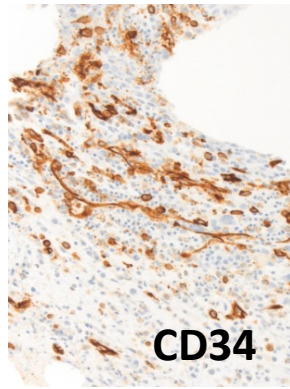
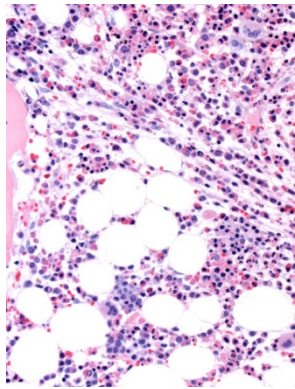
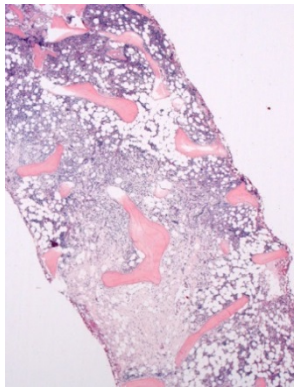
BM bx 3, post induction with CALGB protocol, Day 14 (NADIR marrow), 11.29.2018



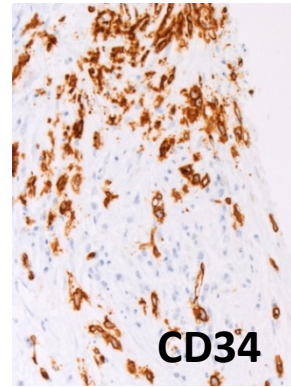
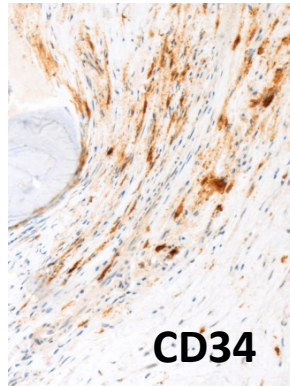
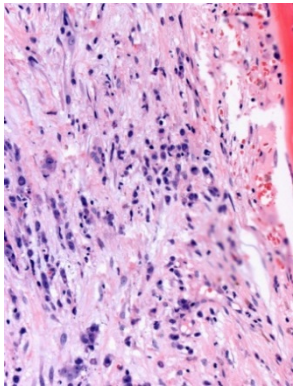
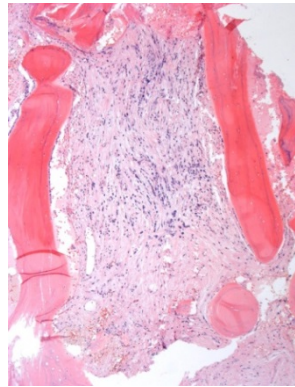
BM bx 4, post induction with CAGB protocol, (Day 41 recovery marrow), 12.27.2018



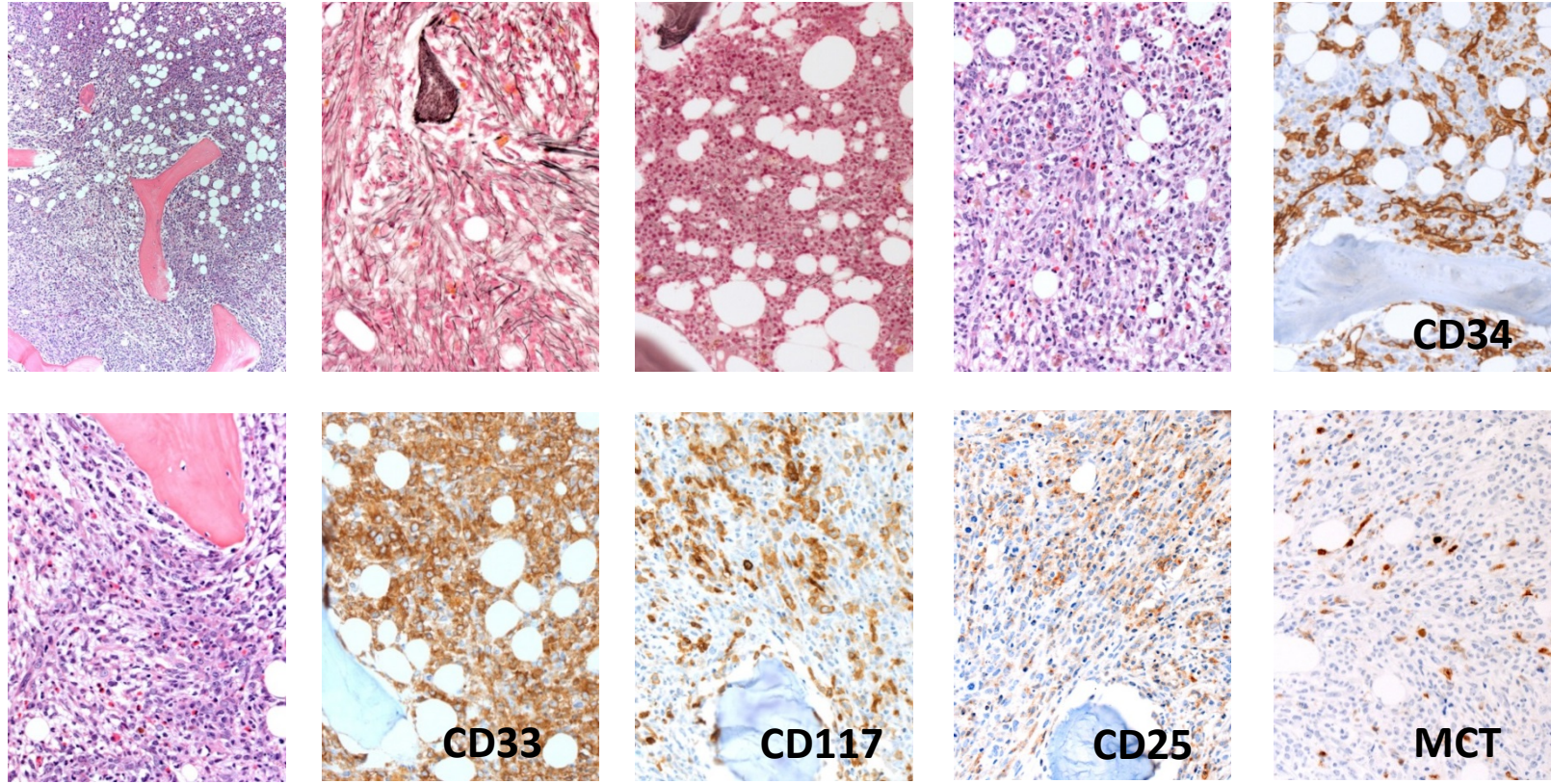
BM bx 5, after end of induction based on lymphoid regimen, 01.17.2019



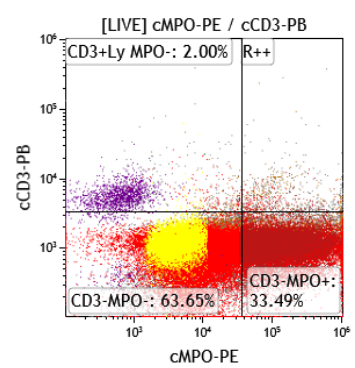
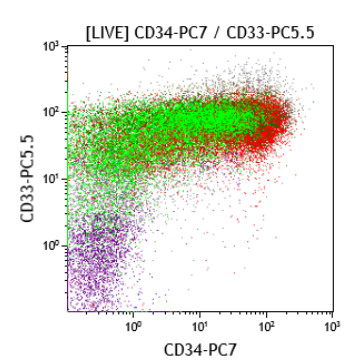
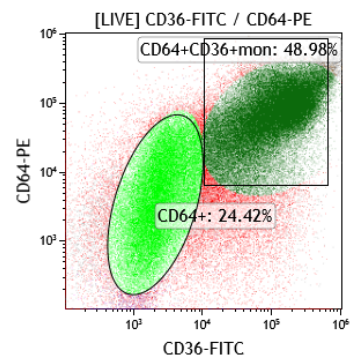
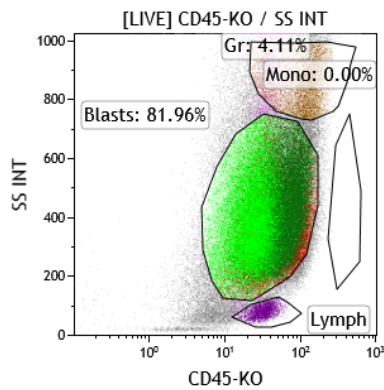
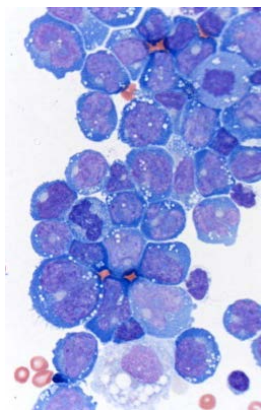
BM bx 6, s/p second induction with HiDAC/mitoxantrone, 02.13.2019



BM bx 7, s/p decitabine plus venetoclax prior ASCT, 03.26.2019

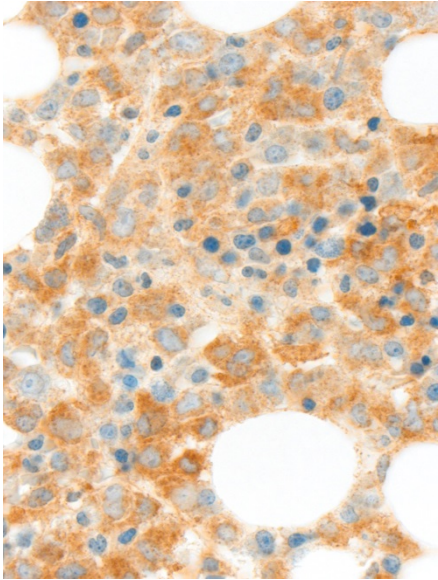
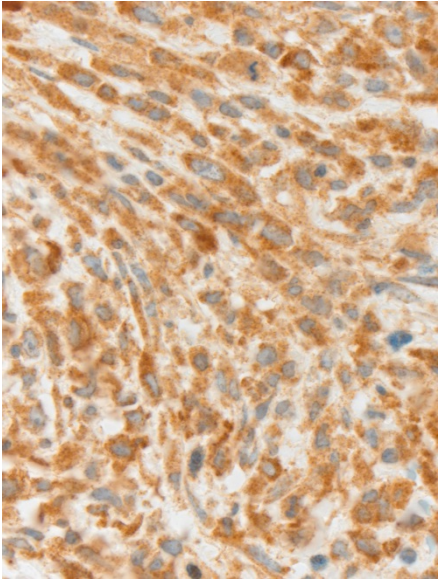
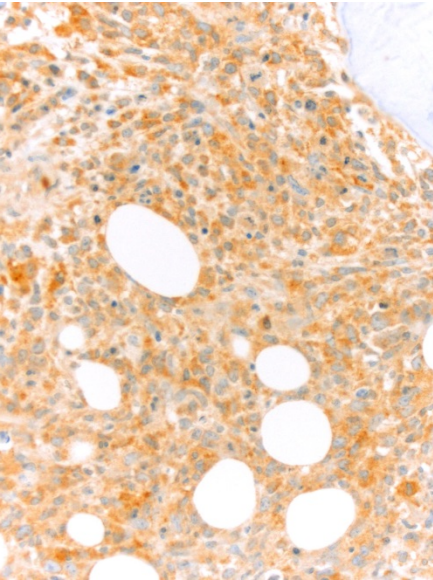


BM bx 8, s/p ASCT 05.21.2019

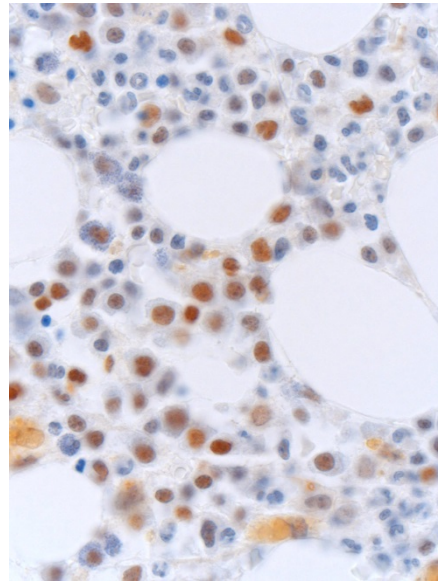
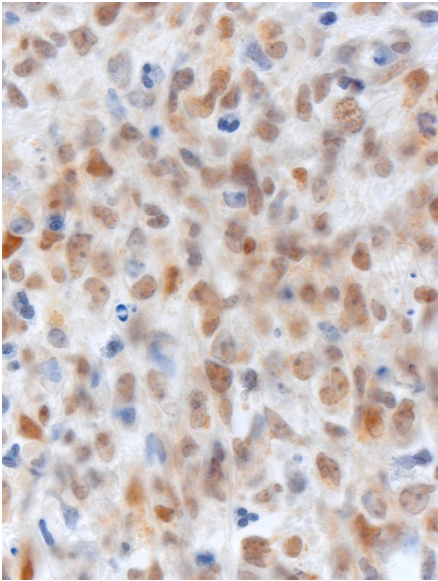
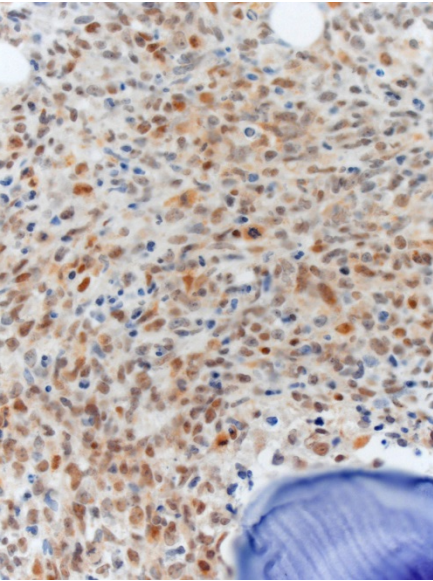


Peritoneal fluid 06.06.2019

BM bx 8, s/p ASCT 05.21.2019 continued.



Bone marrow: FGFR2 IHC



Bone marrow: ETV6 IHC