

Peer review file

Article information: <http://dx.doi.org/10.21037/jtd-20-1948>

Reviewer A

Major Criticisms

**Comment 1:** The text oscillates between individual clinical anecdotes, narrative summary of multicenter data, and broad generalizations and statements of opinion. This disorganization is jarring to the reader and makes the manuscript difficult to follow.

**Reply 1:** Thank you for your comments. We revised the text thoroughly based on your comments. In the new version, we have added the new evidence and relevant information, and deleted the irrelevant sentences. We aimed to focus on the issues related to lung transplantation summary which was derived from the multicenter data in China.

**Changes in the text:** we have modified our text as advised (see the new table 1 and new figure 1-A, page 1, line 19-20, page 3, line 51-56, and page 4, line 69-72).

**Page 1, line 19-20:** Table 1 and figure 1-A show the detailed information and computed tomography (CT) findings of the patient.

**Table 1** Clinical characteristics of the lung transplant recipient with COVID-19

---

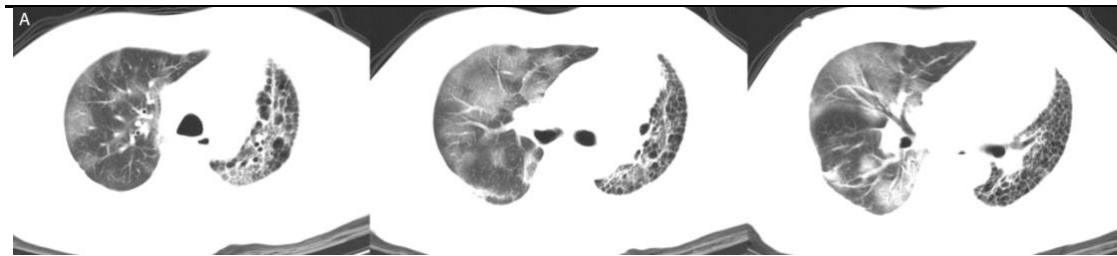
Basic information of the lung transplant recipient	
Gender	Male
Age	65-year-old
Primary indication	Idiopathic pulmonary fibrosis
Date of operation	September 26 <sup>th</sup> 2018
Type of transplant	Right single lung transplant
Range of the follow-up period	Every six-seven weeks if stable
Immunosuppressant	Tacrolimus, mycophenolate mofetil and methylprednisolone
Comorbidities	Diabetes mellitus, chronic kidney disease
CLAD	No

---

### Clinical characteristics of the patient with COVID-19

Date of onset	January 25 <sup>th</sup> 2020
Epidemiology	Exposure to his daughter who was diagnosed COVID-19 on January 20 <sup>th</sup> 2020
Main symptoms	Mild fever (<38.0°C), chills, cough, shortness of breath
RT-PCR results for SARS-CoV-2	Negative on January 29 <sup>th</sup> 2020 (throat swab); Positive on January 31 <sup>st</sup> 2020 (throat swab)
CT findings	Diffuse ground-glass opacities (Figure 1-A)
Treatment	Ganciclovir 0.3g/d intravenously and oral moxifloxacin 0.4g/d (January 29 <sup>th</sup> to 31 <sup>st</sup> )
Outcome	Died 2 hours after admission (January 31 <sup>st</sup> 2020)

CLAD: Chronic lung allograft dysfunction; RT-PCR: real time polymerase chain reaction



**Figure 1-A:** Thoracic CT images of the lungs in a right single lung transplant recipient with COVID-19. The figure shows diffuse ground-glass opacities, which are more prominent in the right lung. Reticular pattern and honeycombing are also seen in the left lung.

**Page 3, line 51-56:** For lung transplant recipients during hospitalization, the detection for SARS-CoV-2 should be done routinely at least every week if they are stable, including those who undergo pulmonary rehabilitation in the early stage post lung transplantation. However, if they are unstable or suspected to be infected with SARS-CoV-2, the test should be performed timely or frequently. For the recipients who are stable and at home, COVID-19 tests would not be mandatory unless they have new-onset symptoms and are suspected to be infected with SARS-CoV-2.

**Page 4, line 69-72:** Based on the experience on the treatment for COVID-19 patients who had undergone SOT in China<sup>[3]</sup>, we suggest the following strategies for lung recipients suffering from COVID-19: 1) Temporally withhold anti-metabolic medication; 2) Decrease the dose of calcineurin inhibitors to a certain degree; 3) Administer low-dose methylprednisolone or steroids therapy.

**Comment 2:** Many assertions are made without sufficient supporting data. One example is lines 31-32: “The success of the transplantation could be attributed to the

dedication of the transplant staff and the implementation of an effective guideline on the prevention strategies of Covid-19.”

**Reply 2:** We have changed our description into “There are several specific guidelines for organ transplantation during the outbreak of COVID-19 in China, and the transplant staff adhered strictly to the guidelines at every step.

**Change in the text:** we have modified our text as advised (see page 2, line 37-39)

**Page 2, line 37-39:** There were several specific guidelines for organ transplantation during the COVID-19 outbreak in China, and the transplant staff adhered strictly to the guidelines at every step.

**Comment 3:** Table 1 requires more explanation. The leftmost column demonstrates a list of author names with a superscript number indicating a citation, but many of these do not correspond with any of the references listed at the end of the manuscript. This is concerning and suggests that the table may have been taken from elsewhere without proper attribution.

**Reply 3:** We do apologize for our carelessness. It was not a correct table. In the new version text, we have uploaded a correct table 1 which matches with the manuscript.

**Changes in the text:** we have modified our text as advised (see the new table 1 and page 1, line 19-20).

**Page 1, line 19-20:** Table 1 and figure 1-A show the detailed information and computed tomography (CT) findings of the patient.

The new table 1 is also attached here:

**Table 1** Clinical characteristics of the lung transplant recipient with COVID-19

---

Basic information of the lung transplant recipient	
Gender	Male
Age	65-year-old
Primary indication	Idiopathic pulmonary fibrosis
Date of operation	September 26 <sup>th</sup> 2018
Type of transplant	Right single lung transplant
Range of the follow-up period	Every six-seven weeks if stable
Immunosuppressant	Tacrolimus, mycophenolate mofetil and methylprednisolone

Comorbidities	Diabetes mellitus, chronic kidney disease
CLAD	No
Clinical characteristics of the patient with COVID-19	
Date of onset	January 25 <sup>th</sup> 2020
Epidemiology	Exposure to his daughter who was diagnosed COVID-19 on January 20 <sup>th</sup> 2020
Main symptoms	Mild fever (<38.0°C), chills, cough, shortness of breath
RT-PCR results for SARS-CoV-2	Negative on January 29 <sup>th</sup> 2020 (throat swab); Positive on January 31 <sup>st</sup> 2020 (throat swab)
CT findings	Diffuse ground-glass opacities (Figure 1-A)
Treatment	Ganciclovir 0.3g/d intravenously and oral moxifloxacin 0.4g/d (January 29 <sup>th</sup> to 31 <sup>st</sup> )
Outcome	Died 2 hours after admission (January 31 <sup>st</sup> 2020)

CLAD: Chronic lung allograft dysfunction; RT-PCR: real time polymerase chain reaction

**Comment 4:** The penultimate paragraph of the manuscript (lines 51-62) appears to be based entirely on the data presented in table 1. The issues with this table make this paragraph uninterpretable.

**Reply 4:** The penultimate paragraph of the manuscript (page 3, lines 57-63) has been amended thoroughly in the revised text. Moreover, we have re-uploaded a correct table 1 which matches with the topic of the manuscript. The previous table 1 has been deleted.

**Chang in the text:** we have modified our text as advised (see page 4, line 67-74)

**Page 4, line 67-74:** Maintenance therapy is crucial to SOT recipients after transplantation. Thus, adjustment for the dosage of immunosuppressants is crucial aside from the background therapy for SOT recipients with Covid-19. Based on the experience on the treatment for COVID-19 patients who had undergone SOT in China[3], we suggest the following strategies for lung recipients suffering from COVID-19: 1) Temporally withhold anti-metabolic medication; 2) Decrease the dose of calcineurin inhibitors to a certain degree; 3) Administer low-dose methylprednisolone or steroids therapy.

The new table 1 is also attached here:

**Table 1** Clinical characteristics of the lung transplant recipient with COVID-19

Basic information of the lung transplant recipient	
Gender	Male
Age	65-year-old
Primary indication	Idiopathic pulmonary fibrosis

Date of operation	September 26 <sup>th</sup> 2018
Type of transplant	Right single lung transplant
Range of the follow-up period	Every six-seven weeks if stable
Immunosuppressant	Tacrolimus, mycophenolate mofetil and methylprednisolone
Comorbidities	Diabetes mellitus, chronic kidney disease
CLAD	No

---

Clinical characteristics of the patient with COVID-19

---

Date of onset	January 25 <sup>th</sup> 2020
Epidemiology	Exposure to his daughter who was diagnosed COVID-19 on January 20 <sup>th</sup> 2020
Main symptoms	Mild fever (<38.0°C), chills, cough, shortness of breath
RT-PCR results for SARS-CoV-2	Negative on January 29 <sup>th</sup> 2020 (throat swab); Positive on January 31 <sup>st</sup> 2020 (throat swab)
CT findings	Diffuse ground-glass opacities (Figure 1-A)
Treatment	Ganciclovir 0.3g/d intravenously and oral moxifloxacin 0.4g/d (January 29 <sup>th</sup> to 31 <sup>st</sup> )
Outcome	Died 2 hours after admission (January 31 <sup>st</sup> 2020)

---

CLAD: Chronic lung allograft dysfunction; RT-PCR: real time polymerase chain reaction

### Overall Impression

This manuscript has issues with structure, tone, and data sourcing, as listed above. It cannot be recommended for publication in its current form.

**Reply:** Thank you for your comments and suggestions. We made a major revision according to your suggestions and instructions.

---

### Reviewer B

I think is a good overview of how to deal with lung trasplant during the Covid emergency. I think you should also write few words about lung transplant performed in Covid patients.

**Reply:** Thank you for your encouragements. Lung transplantation was performed on six patients in mainland China who had suffered from COVID-19. The PCR results for SARS-CoV-2 had been negative for three continuous tests before transplantation. The common indication for transplantation among the six patients are the following: (1)

severe and diffuse lung damage; (2) life-threatening respiratory failure; (3) extremely poor oxygenation. These conditions made it very difficult for these patients to withdraw from the support of the extracorporeal membrane oxygen (ECMO). Among them, the longest time was 62 days for a patient who had been on ECMO for life support.

**Changes in the text:** We believe that these points should be addressed thoroughly. However, I am afraid that we couldn't add a few words about lung transplant performed in COVID-19 patients because of the length limitation and it's irrelevant topic.

---

### **Reviewer C**

Thank you for submitting this letter which has the courage to address a sensitive subject of how to deal with a high medical consuming activity during a dramatic period of time where the same medical resources were almost all dedicated to the COVID pandemic.

Nevertheless, I have troubles with getting your point, are you trying to demonstrate the safe feasibility of solid organ transplantation during the pandemic, are you willing to give recommendation on resuming this activity or are you discussing the specificity of lung transplantation during a pandemic of respiratory disease? I think your letter contains too much of information, all very interesting, but the whole is confusing when put all together with no special aim or pathway to follow in the way you present all your ideas. You need to better identify your aims, and organize your ideas on one central point you wish to address.

**Reply:** Thank you for your instructive comments and suggestions. We have deleted the irrelevant information and removed some statements. In the revised manuscript, we have focused on one central point of lung transplantation during COVID-19 outbreak in mainland China.

**Chang in the text:** we have modified our text as advised (see the new table 1 and new figure 1-A, page 1, line 19-20, page 3, line 51-56, and page 4, line 69-72)

**Page 1, line 19-20:** Table 1 and figure 1-A show the detailed information and computed tomography (CT) findings of the patient.

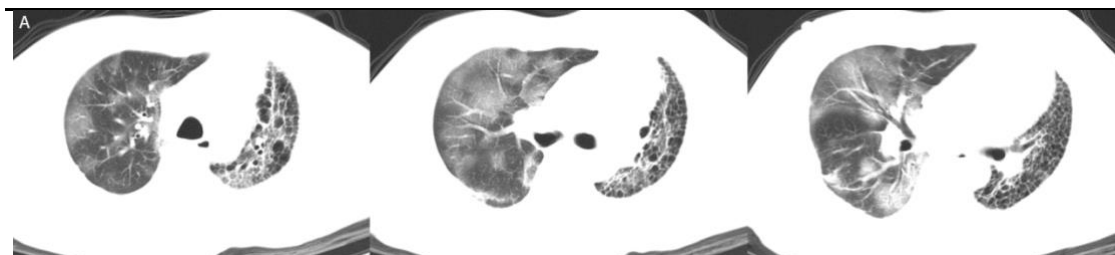
---

**Table 1** Clinical characteristics of the lung transplant recipient with COVID-19

---

Basic information of the lung transplant recipient	
Gender	Male
Age	65-year-old
Primary indication	Idiopathic pulmonary fibrosis
Date of operation	September 26 <sup>th</sup> 2018
Type of transplant	Right single lung transplant
Range of the follow-up period	Every six-seven weeks if stable
Immunosuppressant	Tacrolimus, mycophenolate mofetil and methylprednisolone
Comorbidities	Diabetes mellitus, chronic kidney disease
CLAD	No
Clinical characteristics of the patient with COVID-19	
Date of onset	January 25 <sup>th</sup> 2020
Epidemiology	Exposure to his daughter who was diagnosed COVID-19 on January 20 <sup>th</sup> 2020
Main symptoms	Mild fever (<38.0°C), chills, cough, shortness of breath
RT-PCR results for SARS-CoV-2	Negative on January 29 <sup>th</sup> 2020 (throat swab); Positive on January 31 <sup>st</sup> 2020 (throat swab)
CT findings	Diffuse ground-glass opacities (Figure 1-A)
Treatment	Ganciclovir 0.3g/d intravenously and oral moxifloxacin 0.4g/d (January 29 <sup>th</sup> to 31 <sup>st</sup> )
Outcome	Died 2 hours after admission (January 31 <sup>st</sup> 2020)

CLAD: Chronic lung allograft dysfunction; RT-PCR: real time polymerase chain reaction



**Figure 1-A:** Thoracic CT images of the lungs in a right single lung transplant recipient with COVID-19. The figure shows diffuse ground-glass opacities, which are more prominent in the right lung. Reticular pattern and honeycombing are also seen in the left lung.

**Page 3, line 51-56:** For lung transplant recipients during hospitalization, the detection for SARS-CoV-2 should be done routinely at least every week if they are stable, including those who undergo pulmonary rehabilitation in the early stage post lung transplantation. However, if they are unstable or suspected to be infected with SARS-

CoV-2, the test should be performed timely or frequently. For the recipients who are stable and at home, COVID-19 tests would not be mandatory unless they have new-onset symptoms and are suspected to be infected with SARS-CoV-2.

**Page 4, line 69-72:** Based on the experience on the treatment for COVID-19 patients who had undergone SOT in China<sup>[3]</sup>, we suggest the following strategies for lung recipients suffering from COVID-19: 1) Temporally withhold anti-metabolic medication; 2) Decrease the dose of calcineurin inhibitors to a certain degree; 3) Administer low-dose methylprednisolone or steroids therapy.

#### **Reviewer D**

In this letter to the Editor, Ju et al shortly review the chinese experience with COVID-19 infected solid organ transplant recipients. They especially focus on COVID-19 infected lung transplant recipients. I have the following comments/concerns:

**Comment 1:** Line 15: I think that the authors meant SOT Transplantation and not non-lung SOT Transplantation.

**Reply 1:** Thank you for your comments. We have corrected the sentence by removing the word.

**Chang in the text:** see Page 1, line 15-16.

**Page 1, line 15-16:** Of the 30 patients with COVID-19 who have undergone SOT procedures.

**Comment 2:** Line 16: I suggest that the authors should spend a couple of lines more describing this specific case of COVID-19 infected lung transplant recipient, for example describing the presence of comorbidities, CLAD...

**Reply 2:** Thank you for your suggestion. We have provided the information in detail about the lung transplantation patient according to your advise. There was no evidence to diagnose CLAD because his lung function and CT scan had been stable before he suffered from the COVID-19. Also, he had a stable exercise capacity before he was infected with SARS-CoV-2. As for the comorbidities, he had type 2 diabetes and chronic kidney disease after lung transplantation caused by Immunosuppressant such as Tacrolimus and methylprednisolone. He had been on some medications for his



diabetes and chronic kidney disease. We have added a new table 1 in which we supplemented the information in detail in the revised manuscript.

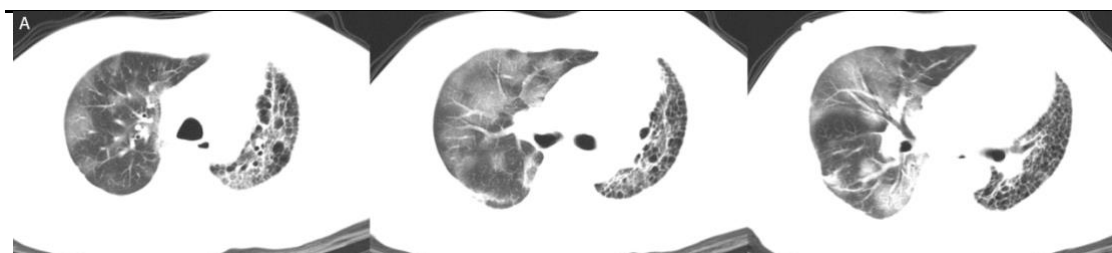**Changes in the text:** We have modified our text as advised (see table 1, and page 1, line19-20)

**Page 1, line 19-20:** Table 1 and figure 1-A show the detailed information and computed tomography (CT) findings of the patient.

**Table 1** Clinical characteristics of the lung transplant recipient with COVID-19

Basic information of the lung transplant recipient	
Gender	Male
Age	65-year-old
Primary indication	Idiopathic pulmonary fibrosis
Date of operation	September 26 <sup>th</sup> 2018
Type of transplant	Right single lung transplant
Range of the follow-up period	Every six-seven weeks if stable
Immunosuppressant	Tacrolimus, mycophenolate mofetil and methylprednisolone
Comorbidities	Diabetes mellitus, chronic kidney disease
CLAD	No
Clinical characteristics of the patient with COVID-19	
Date of onset	January 25 <sup>th</sup> 2020
Epidemiology	Exposure to his daughter who was diagnosed COVID-19 on January 20 <sup>th</sup> 2020
Main symptoms	Mild fever (<38.0°C), chills, cough, shortness of breath
RT-PCR results for SARS-CoV-2	Negative on January 29 <sup>th</sup> 2020 (throat swab); Positive on January 31 <sup>st</sup> 2020 (throat swab)
CT findings	Diffuse ground-glass opacities (Figure 1-A)
Treatment	Ganciclovir 0.3g/d intravenously and oral moxifloxacin 0.4g/d (January 29 <sup>th</sup> to 31 <sup>st</sup> )
Outcome	Died 2 hours after admission (January 31 <sup>st</sup> 2020)

CLAD: Chronic lung allograft dysfunction; RT-PCR: real time polymerase chain reaction



**Figure 1-A:** Thoracic CT images of the lungs in a right single lung transplant recipient with COVID-19. The figure shows diffuse ground-glass opacities, which are more prominent in the right lung. Reticular pattern and honeycombing are also seen in the left lung.

**Comment 3:** Line 20: I do not understand if there were 2 or only 1 (line 16) COVID-19 infected lung-transplanted patients. Here I understand that there were two COVID-19 lung-transplanted patients.

**Reply 3:** Thank you for your comment. There are two issues that should be clarified: on the one hand, In our manuscript, we presented one lung recipient who suffered from the COVID-19 16 months post lung transplantation. There was only one lung recipient who infected with SARS-CoV-2 in China. We have spent a few lines of texts describing the lung transplant recipient who suffered from COVID-19 16 months post lung transplantation. On the other hand, there were six COVID-19 patients who underwent lung transplantation in mainland China according to the report from our national organ transplant center. The common indications for their transplants among the six patients were the following: (1) severe and diffuse lung damage; (2) life-threatening respiratory failure; (3) extremely poor oxygenation. These conditions made it very difficult for them to withdraw from the support of the extracorporeal membrane oxygen (ECMO). However, conditions of the COVID-19 patients who underwent the lung transplantation would not be specified in the main text because this would dilute our topic, especially taking into account the limited space for an editorial article according to the Journal's policy.

**Chang in the text:** We have modified our text as advised (see table 1 and figure 1-A, page1, line 19-20)

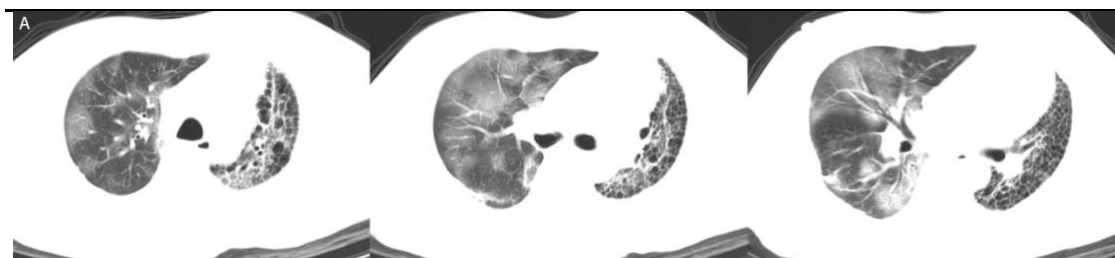**Page 1, line 19-20:** Table 1 and figure 1-A show the detailed information and computed tomography (CT) findings of the patient.

**Table 1** Clinical characteristics of the lung transplant recipient with COVID-19

Basic information of the lung transplant recipient	
Gender	Male
Age	65-year-old
Primary indication	Idiopathic pulmonary fibrosis
Date of operation	September 26 <sup>th</sup> 2018

Type of transplant	Right single lung transplant
Range of the follow-up period	Every six-seven weeks if stable
Immunosuppressant	Tacrolimus, mycophenolate mofetil and methylprednisolone
Comorbidities	Diabetes mellitus, chronic kidney disease
CLAD	No
Clinical characteristics of the patient with COVID-19	
Date of onset	January 25 <sup>th</sup> 2020
Epidemiology	Exposure to his daughter who was diagnosed COVID-19 on January 20 <sup>th</sup> 2020
Main symptoms	Mild fever (<38.0°C), chills, cough, shortness of breath
RT-PCR results for SARS-CoV-2	Negative on January 29 <sup>th</sup> 2020 (throat swab); Positive on January 31 <sup>st</sup> 2020 (throat swab)
CT findings	Diffuse ground-glass opacities (Figure 1-A)
Treatment	Ganciclovir 0.3g/d intravenously and oral moxifloxacin 0.4g/d (January 29 <sup>th</sup> to 31 <sup>st</sup> )
Outcome	Died 2 hours after admission (January 31 <sup>st</sup> 2020)

CLAD: Chronic lung allograft dysfunction; RT-PCR: real time polymerase chain reaction

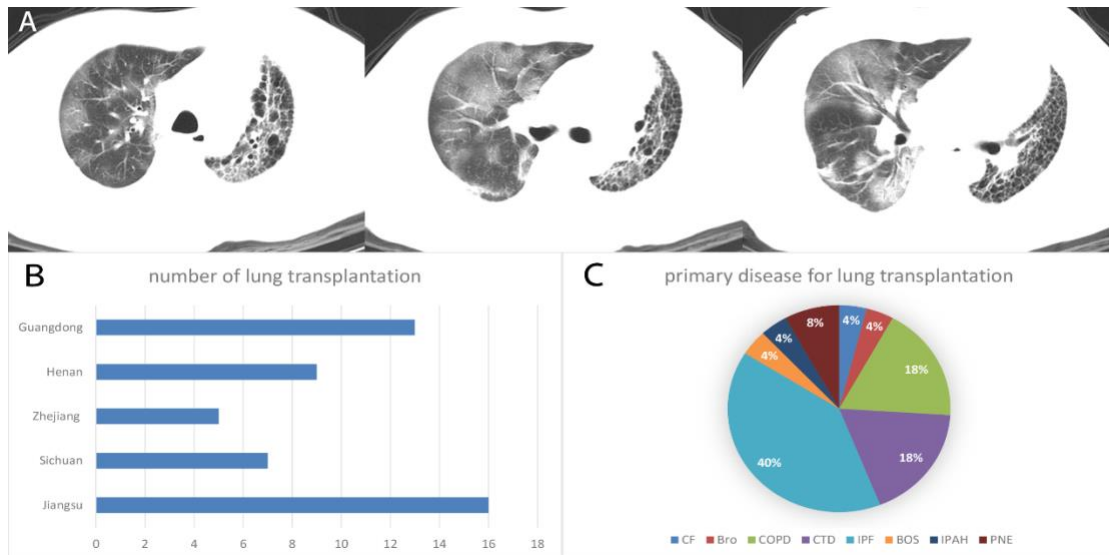


**Figure 1-A:** Thoracic CT images of the lungs in a right single lung transplant recipient with COVID-19. The figure shows diffuse ground-glass opacities, which are more prominent in the right lung. Reticular pattern and honeycombing are also seen in the left lung.

**Comment 4:** Line 26: the figure numeration is not correct: I think that the correct figure here should be Figure 1-B and not A. The same for line 30, here it should be Figure 1-C and not B.

**Reply 4:** We apologize for the lack of clarity. In the revised text, we made a major amendment, and the new figure 1-A has been re-uploaded and the figure numeration has been checked.

**Chang in the text:** We have modified our text as advised (see the Page 1, line 19-20; page 2, line 29 and 36; and see new figure 1 A-C)



**Figure 1-A:** Thoracic CT images of the lungs in a right single lung transplant recipient with COVID-19. The figure shows diffuse ground-glass opacities, which are more prominent in the right lung. Reticular pattern and honeycombing are also seen in the left lung.

**Figure 1-B:** The number of lung transplantation performed in several centers during the outbreak of COVID-19 in mainland China.

**Figure 1-C:** The underlying diseases for lung transplantation during the COVID-19 outbreak in mainland China.

Bro=bronchiectasis, BOS=obliterative bronchiolitis syndrome; COPD=chronic obstructive pulmonary disease; CTD=connective tissue disease related lung interstitial disease (CTD-ILD); IPAH= idiopathic pulmonary arterial hypertension; IPF=idiopathic pulmonary fibrosis; Pne=pneumoconiosis.

**Comment 5:** Line 27: the authors should specify the time span when the 50 patients were transplanted.

**Reply 5:** Thank you for your suggestion. We have specified the time span.

**Change in the text:** We have modified our text as advised (see Page 2, line 30-32).

**page 2, line 30-32:** The total number of lung transplantation surgeries performed was 50 during the epidemic period (from 23 January to 22 April) in mainland China, with 11 cases being performed from 23<sup>rd</sup> January to 22<sup>nd</sup> February, 14 cases from 23<sup>rd</sup> February to 22<sup>nd</sup> March, and 25 cases from 23<sup>rd</sup> March to 22<sup>nd</sup> April.

**Comment 6:** Line 41 and 42: I do not agree with the authors that post-transplant patients should weekly undergo COVID-19 test.

**Reply 6:** Thank you for your opinion. We apologize for the lack of clarity. The

statement intended to convey the message that the recipients who should undergo COVID-19 test weekly are those who are hospitalized but remaining stable, including those who were hospitalized to undergo pulmonary rehabilitation in the early stage post lung transplantation. It is a routine test weekly until discharged from the hospital. However, if they are unstable or suspected to be infected with SARS-CoV-2, the test should be performed timely or frequently. For the recipients who are stable and at home, COVID-19 tests would not be mandatory unless they have new-onset symptoms and are suspected to be infected with SARS-CoV-2.

**Chang in the text:** We have modified our text as advised (see Page 3, line 51-56).

**Page 3, line 51-56:** For lung transplant recipients during hospitalization, the detection for SARS-CoV-2 should be done routinely at least every week if they are stable, including those who undergo pulmonary rehabilitation in the early stage post lung transplantation. However, if they are unstable or suspected to be infected with SARS-CoV-2, the test should be performed timely or frequently. For the recipients who are stable and at home, COVID-19 tests would not be mandatory unless they have new-onset symptoms and are suspected to be infected with SARS-CoV-2.

**Comment 7:** Line 58: which through levels of CNI are suggested by the authors in case of COVID-19 infection?

**Reply 7:** Thank you for your question. It is difficult to elaborate a definite levels for the recipients in case of COVID-19 infection. Generally, we decided the trough levels of CNI according to the patients' age, severity of the infection, functions of liver and kidney, status of the immune system, with or without commodities such as myelosuppression, etc. We would decrease the trough levels of CNI to a varying degree based on the overall condition of the patients.

**Chang in the text:** We have modified our text as advised (see Page 4, line 71-72).

**Page 4, line 71-72:** 1) Temporally withhold anti-metabolic medication; 2) Decrease the dose of calcineurin inhibitors to a certain degree; 3) Administer low-dose methylprednisolone or steroids therapy.

## **Reviewer E**

The authors reviewed the data of 30 recipients of solid-organ transplantation who

experienced COVID-19 in mainland China. Among these, only one patient had underwent lung transplantation; however, this patient died of 2 hours later before the admission in ICU. Other recipients of kidney, liver and heart transplantation were successfully managed by the reduction of maintenance immunosuppression. This paper provided valuable data and important information for transplant physicians especially about maintenance immunosuppression during the treatment of COVID-19; however, the authors need to address the comments as below.

Major comments:

**Comment 1:** The authors should describe the details about clinical course of the patient who encountered COVID-19 after lung transplantation, including chest X-ray or computed tomography (CT). Did the patient have the evidence of the development of chronic lung allograft dysfunction (CLAD) before the diagnosis of COVID-19? Did he undergo single or bilateral lung transplantation? What symptom did he have, cough, fever or general fatigue? The details about this patient's clinical course should be summarized in one paragraph for better understanding.

**Reply 1:** Thank you for your suggestion. We have provided the information in detail about the lung transplantation patient as advised. There was no evidence of CLAD because his lung function and CT scan had been stable before he suffered from the COVID-19. Also, he had a stable exercise capacity before he was infected with SARS-CoV-2. He underwent right single lung transplantation. He had symptoms including cough, chills, cough and shortness of breath. The details about this patient's clinical course have been summarized in the new table 1 and figure 1-A.

**Chang in the text:** We have modified our text as advised (see table 1 and figure 1-A, page1, line 19-20)

**Page 1, line 19-20:** Table 1 and figure 1-A show the detailed information and computed tomography (CT) findings of the patient.

**Table 1** Clinical characteristics of the lung transplant recipient with COVID-19

Basic information of the lung transplant recipient	
Gender	Male
Age	65-year-old
Primary indication	Idiopathic pulmonary fibrosis

Date of operation	September 26 <sup>th</sup> 2018
Type of transplant	Right single lung transplant
Range of the follow-up period	Every six-seven weeks if stable
Immunosuppressant	Tacrolimus, mycophenolate mofetil and methylprednisolone
Comorbidities	Diabetes mellitus, chronic kidney disease
CLAD	No

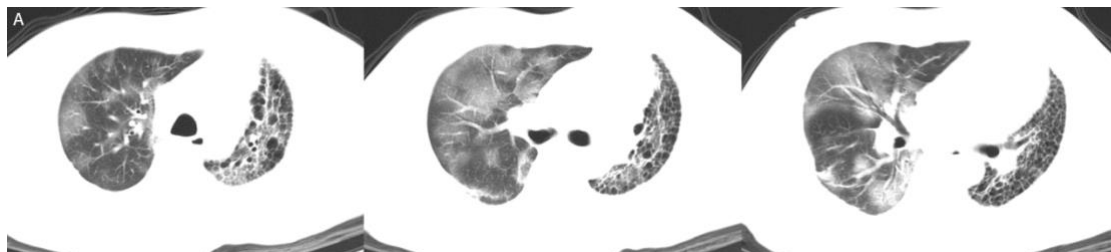
---

Clinical characteristics of the patient with COVID-19

---

Date of onset	January 25 <sup>th</sup> 2020
Epidemiology	Exposure to his daughter who was diagnosed COVID-19 on January 20 <sup>th</sup> 2020
Main symptoms	Mild fever (<38.0°C), chills, cough, shortness of breath
RT-PCR results for SARS-CoV-2	Negative on January 29 <sup>th</sup> 2020 (throat swab); Positive on January 31 <sup>st</sup> 2020 (throat swab)
CT findings	Diffuse ground-glass opacities (Figure 1-A)
Treatment	Ganciclovir 0.3g/d intravenously and oral moxifloxacin 0.4g/d (January 29 <sup>th</sup> to 31 <sup>st</sup> )
Outcome	Died 2 hours after admission (January 31 <sup>st</sup> 2020)

CLAD: Chronic lung allograft dysfunction; RT-PCR: real time polymerase chain reaction



**Figure 1-A:** Thoracic CT images of the lungs in a right single lung transplant recipient with COVID-19. The figure shows diffuse ground-glass opacities, which are more prominent in the right lung. Reticular pattern and honeycombing are also seen in the left lung.

**Comment 2:** Did the deceased donors have the examination of PCR analysis of SARS-CoV-2? The authors should clearly describe about this issue.

**Reply 2:** Thanks for your nice suggestion. The deceased donors underwent PCR assays of SARS-CoV-2. We have stated as “To ensure safety, the potentially eligible donors must undergo bronchoscopy, blood and fecal test to preclude the infection with COVID-19, the negative PCR result for SARS-CoV-2 must be confirmed before the organ was procured”.

**Chang in the text:** We have modified our text as advised (see Page 3, line 48-51).

**Page 3, line 48-51:** To ensure safety, the potentially eligible donors must undergo bronchoscopy, blood and fecal test to preclude the infection with COVID-19, the negative PCR result for SARS-CoV-2 must be confirmed before the organ was procured.

**Comment 3:** How was the risk of repeated bronchoscopy to collect BALF samples for lung transplant physicians? Wasn't the bronchoscopy hazardous for physicians or did the bronchoscopy increase the risk of COVID-19 for physicians?

**Reply 3:** Thank you for your comment. We completely agree with your viewpoint. We have modified the sentence into “The detection for SARS-CoV-2 should be performed every 1-2 days for the throat swab in suspected cases. However, bronchoalveolar lavage fluid (BALF) might be considered if a recipient was highly suspected of suffering from COVID-19 despite repeated negative findings of the throat swab.”

**Chang in the text:** We have modified our text as advised (see Page 3, line 63-66).

**Page 3, line 63-66:** The detection for SARS-CoV-2 should be performed every 1-2 days for the throat swab in suspected cases. However, bronchoalveolar lavage fluid (BALF) might be considered if a recipient was highly suspected of suffering from COVID-19 despite repeated negative findings of the throat swab.

**Comment 4:** The authors should describe the range of the follow-up period after transplantation in Table 1, because the maintenance immunosuppression is gradually tapered after transplantation. Also, chest X-ray or CT findings of the lungs in COVID-19 patients should be added in Table 1 if possible.

**Reply 4:** Thank you for your suggestions. We totally agree with your points that the range of the follow-up period after transplantation should be described. For the COVID-19 patients, CT findings of the lungs have been added in the new table 1 and in figure 1-A (attached in the following).

**Chang in the text:** We have modified our text as advised (see new table 1, figure 1-A, and page 1, line 19-20)

**Page 1, line 19-20:** Table 1 and figure 1-A show the detailed information and computed tomography (CT) findings of the patient.

---

**Table 1** Clinical characteristics of the lung transplant recipient with COVID-19

---

Basic information of the lung transplant recipient

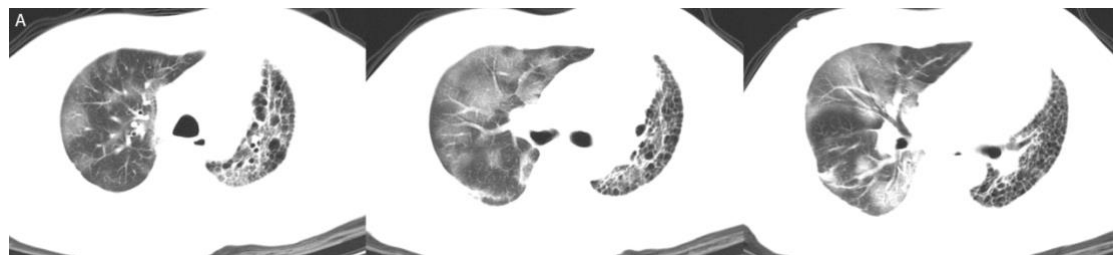


Gender	Male
Age	65-year-old
Primary indication	Idiopathic pulmonary fibrosis
Date of operation	September 26 <sup>th</sup> 2018
Type of transplant	Right single lung transplant
Range of the follow-up period	Every six-seven weeks if stable
Immunosuppressant	Tacrolimus, mycophenolate mofetil and methylprednisolone
Comorbidities	Diabetes mellitus, chronic kidney disease
CLAD	No

Clinical characteristics of the patient with COVID-19

Date of onset	January 25 <sup>th</sup> 2020
Epidemiology	Exposure to his daughter who was diagnosed COVID-19 on January 20 <sup>th</sup> 2020
Main symptoms	Mild fever (<38.0°C), chills, cough, shortness of breath
RT-PCR results for SARS-CoV-2	Negative on January 29 <sup>th</sup> 2020 (throat swab); Positive on January 31 <sup>st</sup> 2020 (throat swab)
CT findings	Diffuse ground-glass opacities (Figure 1-A)
Treatment	Ganciclovir 0.3g/d intravenously and oral moxifloxacin 0.4g/d (January 29 <sup>th</sup> to 31 <sup>st</sup> )
Outcome	Died 2 hours after admission (January 31 <sup>st</sup> 2020)

CLAD: Chronic lung allograft dysfunction; RT-PCR: real time polymerase chain reaction



**Figure 1-A:** Thoracic CT images of the lungs in a right single lung transplant recipient with COVID-19. The figure shows diffuse ground-glass opacities, which are more prominent in the right lung. Reticular pattern and honeycombing are also seen in the left lung.

Minor comments:

**Comment 1:** (Line 36) How long had the transplant program been ceased in the epicenters such as Wuhan City? Has it already restarted? Are there some guidelines for the restart of organ transplantation in China?

**Reply 1:** Thank you for your comment. The transplant program had been ceased for about 76 days (from 23<sup>rd</sup> Jan to 8<sup>th</sup> April) in the epicenters such as Wuhan City, and was restarted at the mid-April, 2020. There are several guidelines for the re-initiation of organ transplantation in China, and the transplant staff did adhere strictly to the guidelines.

**Chang in the text:** We have modified our text as advised (see Page 2, line 37-39).

**Page 2, line 37-39:** There were several specific guidelines for organ transplantation during the COVID-19 outbreak in China, and the transplant staff adhered strictly to the guidelines at every step.

**Comment 2:** (Line 37) The authors should clearly describe “COVID-19” in the description of “new cases.”

**Reply2:** Thank you for your suggestion. We have made the relevant changes.

**Chang in the text:** We have modified our text as advised (see Page 3, line 45).

**Page 3, line 45:** In light of the substantially decreased number of new cases with COVID-19.

**Comment 3:** (Line 56) the word of “methyltrienolone” was methylprednisolone?

**Reply 3:** Yes, The correct word should be “methylprednisolone”.

**Chang in the text:** We have modified our text as advised (see Page 4, line 72).

**Page 4, line 72:** Administer low-dose methylprednisolone or steroids therapy.

**Comment 4:** The size or resolution of Figure 1 and Table 1 was not adequate and should be changed to appropriate version.

**Reply4:** The size and resolution of Figure 1 and Table 1 have been changed into appropriate version in the revised manuscript.

**Chang in the text:** We modified the figure 1 and table 1 as advised (see figure 1 and new table 1).