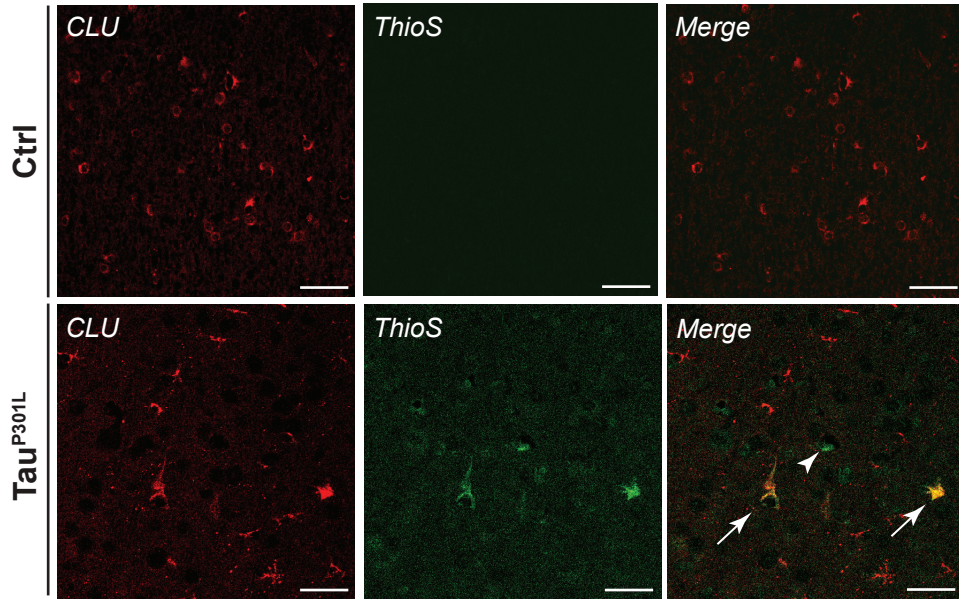
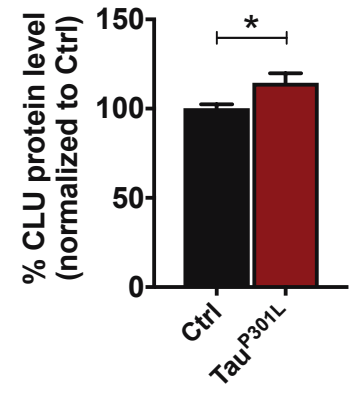
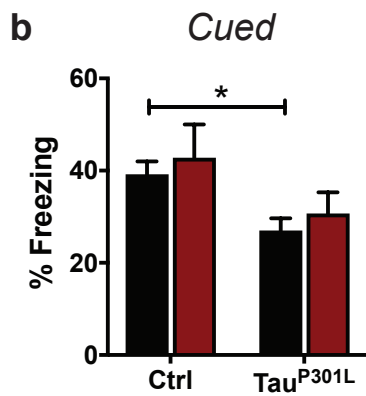
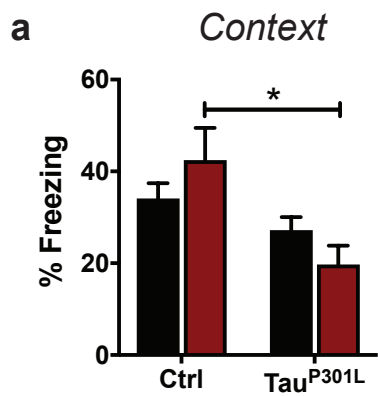


Neuropathological diagnosis	Normal Control	Alzheimer's disease	Corticobasal degeneration	Pick's disease
Braak tangle stage	1	5	3	2
Thal amyloid phase	0	5	0	0
Age	73	69	75	59

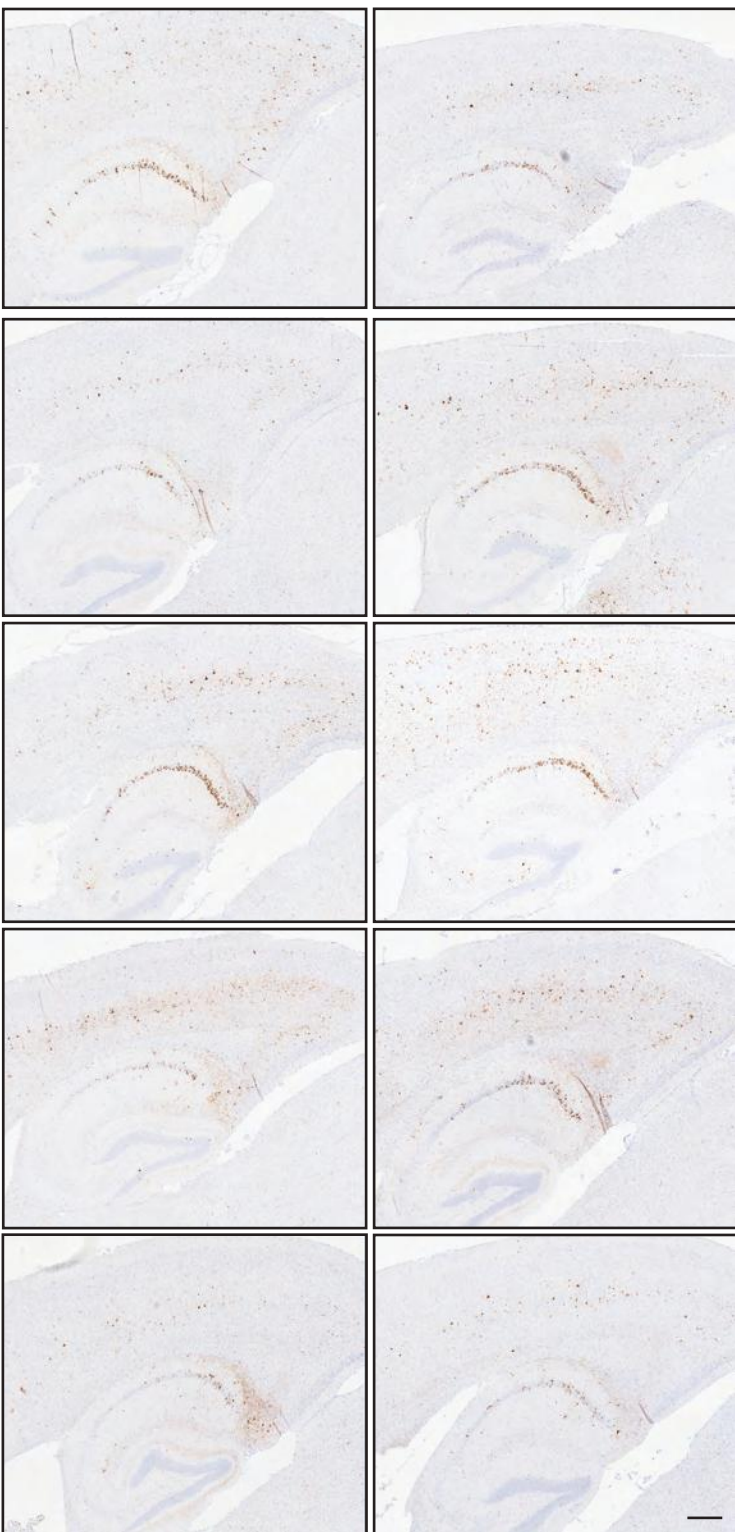
Neuropathological diagnosis	Normal Control (N=10)	Alzheimer's disease (N=10)	Corticobasal degeneration (N=15)	Pick's disease (N=12)
Median Braak tangle stage (range)	2 (1-3)	6 (6)	2 (0-4)	2 (0-3)
Median Thal amyloid phase (range)	0 (0-1)	5 (5)	0 (0-2)	0 (0-3)
Median age (range)	71.5 (60-78)	66 (56-75)	67 (58-77)	65.5 (53-84)
Female (%)	4/10 (40%)	6/10 (60%)	6/15 (40%)	5/12 (42%)

**a****b**

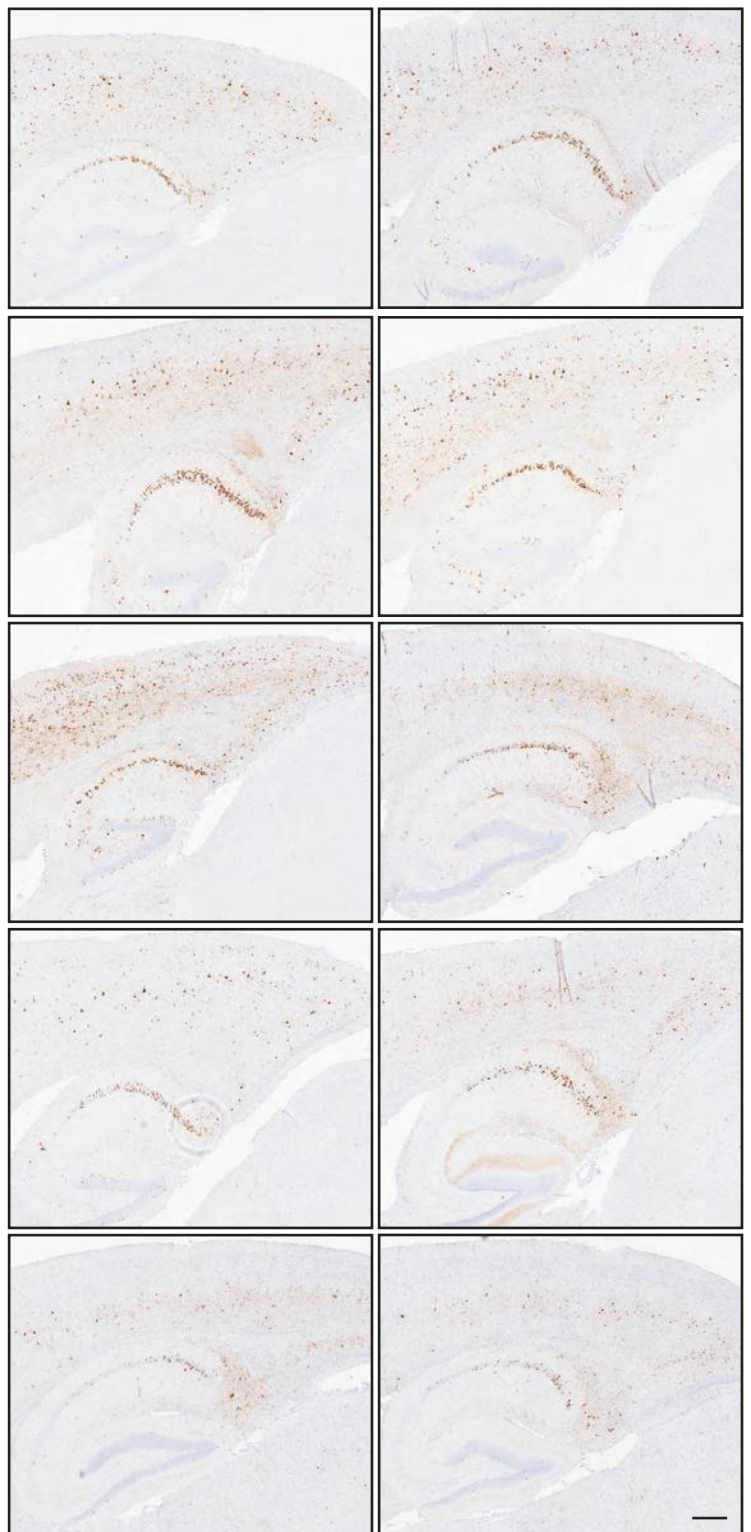


**a**

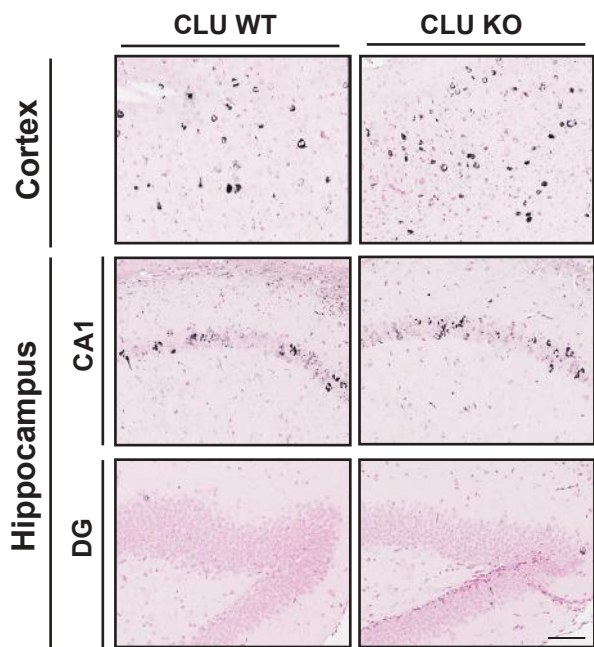
**CLU WT**



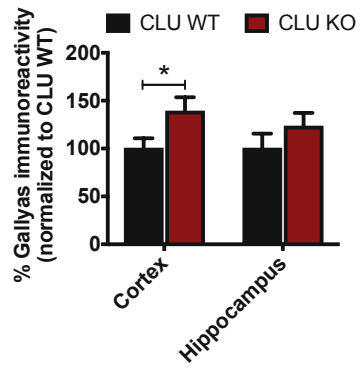
**CLU KO**



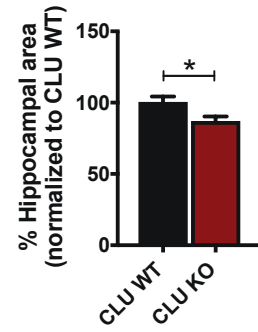
**a** Gallyas silver stain



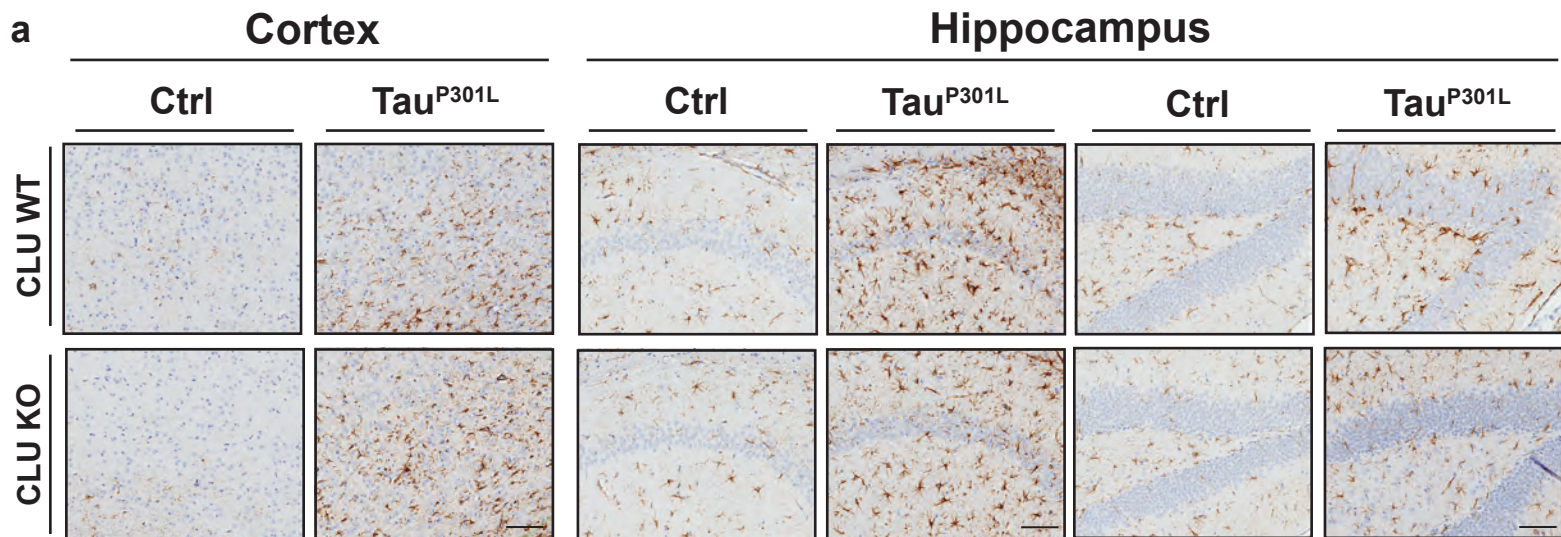
**b**



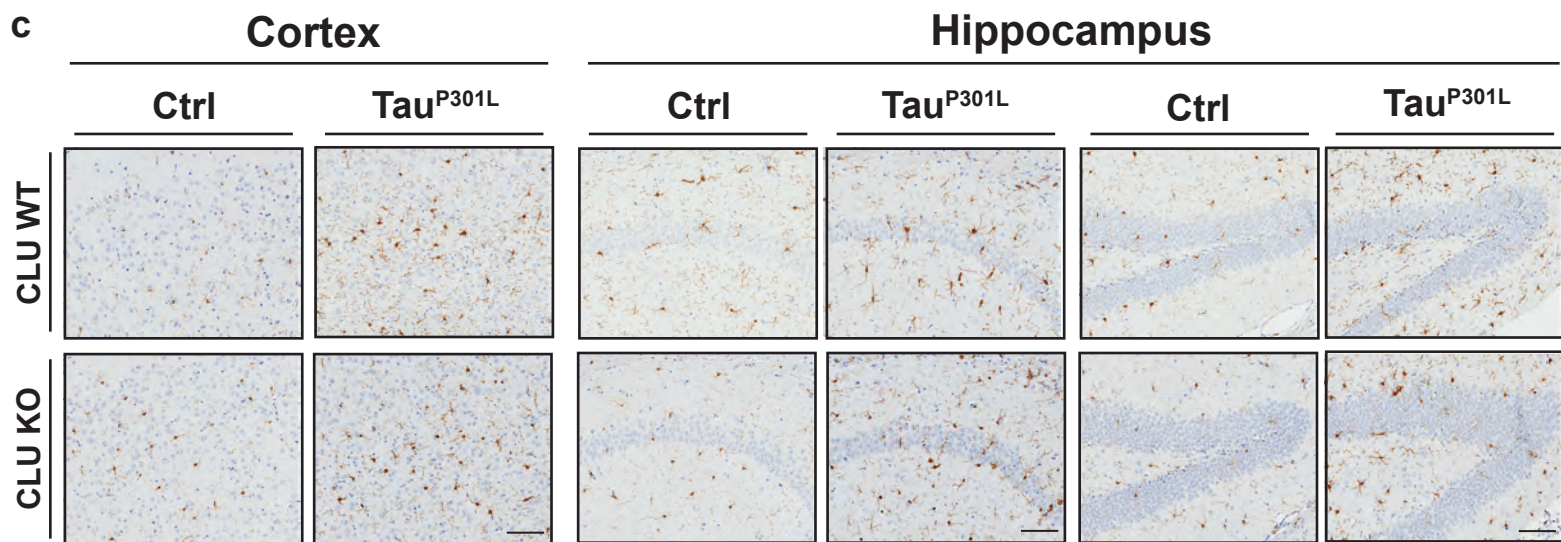
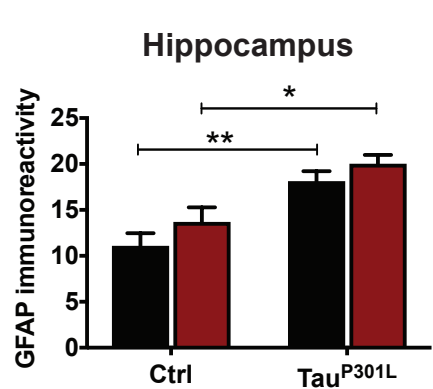
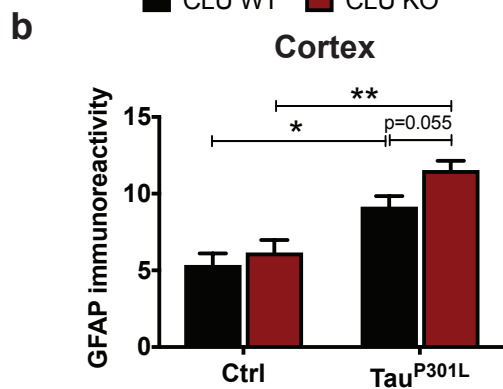
**c**







■ CLU WT ■ CLU KO



■ CLU WT ■ CLU KO

