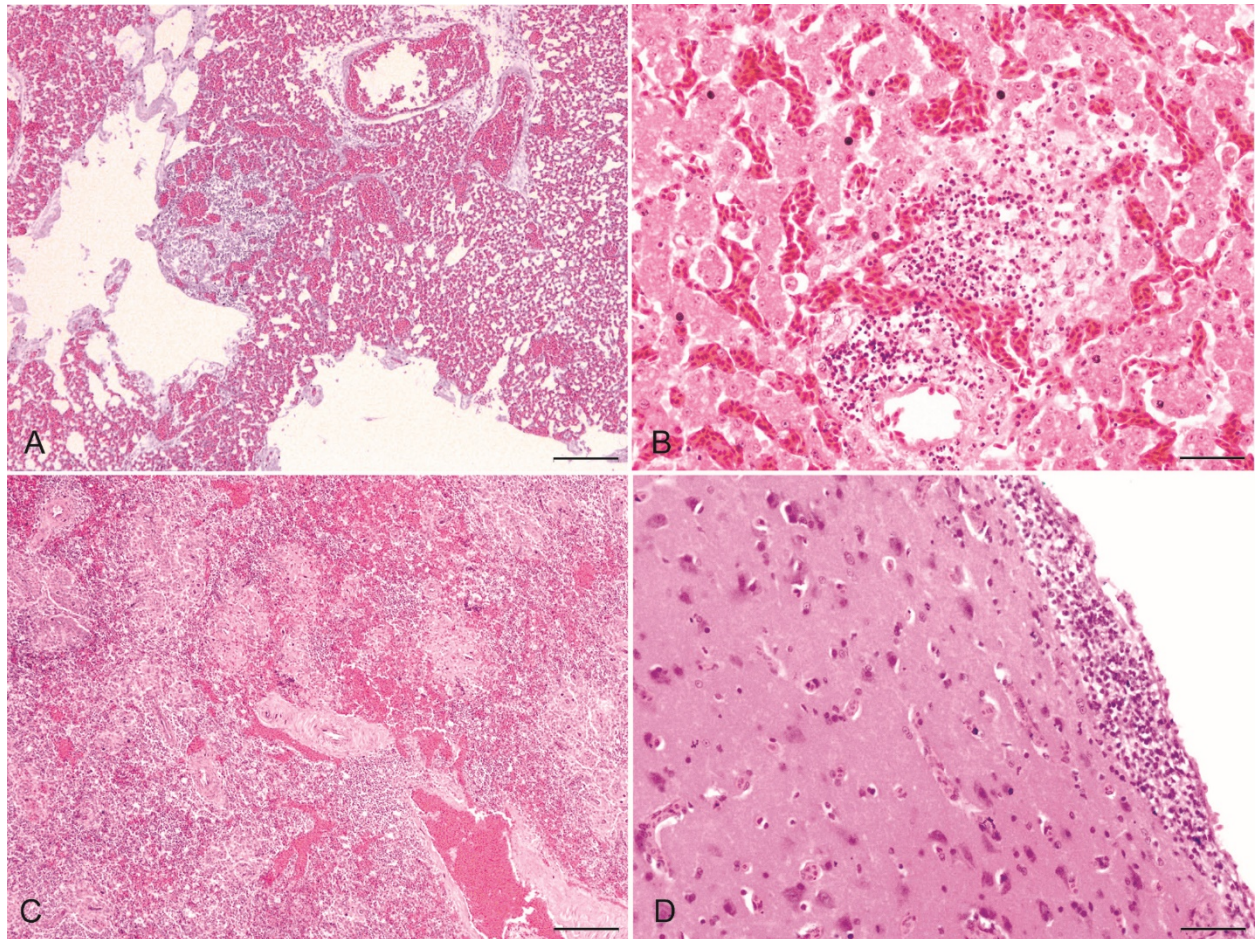


Mumu TT, et al. Pathology of an outbreak of highly pathogenic avian influenza A (H5N1) virus of clade 2.3.2.1a in turkeys in Bangladesh



**Supplementary Figure 1.** Histopathologic changes in avian influenza A(H5N1) virus-affected turkeys. **A.** Hemorrhages in the lungs. Bar = 50  $\mu$ m. **B.** Hemorrhages in the liver. Bar = 50  $\mu$ m. **C.** Multifocal necrosis with hemorrhages in the spleen. Bar = 50  $\mu$ m. **D.** Gliosis and focal encephalomalacia with encephalitis. Bar = 50  $\mu$ m. H&E.