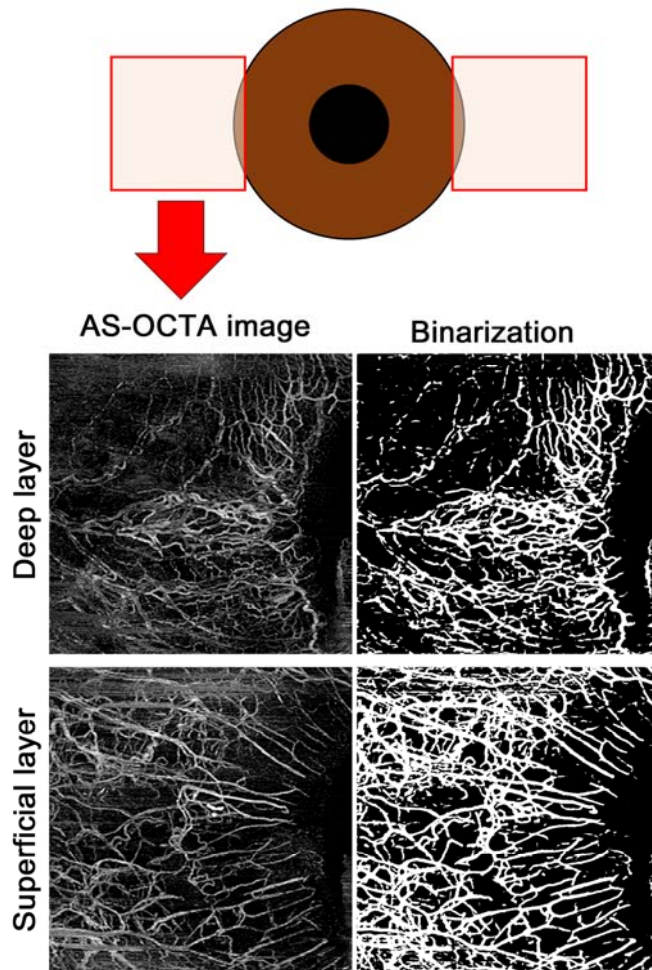


Figure S1. AS-OCTA Image Acquisition and Processing.



AS-OCTA images of the corneal limbus were obtained in the temporal and nasal regions. Binarization of each image in the deep and superficial layer was performed using a Trainable Weka Segmentation in ImageJ software.