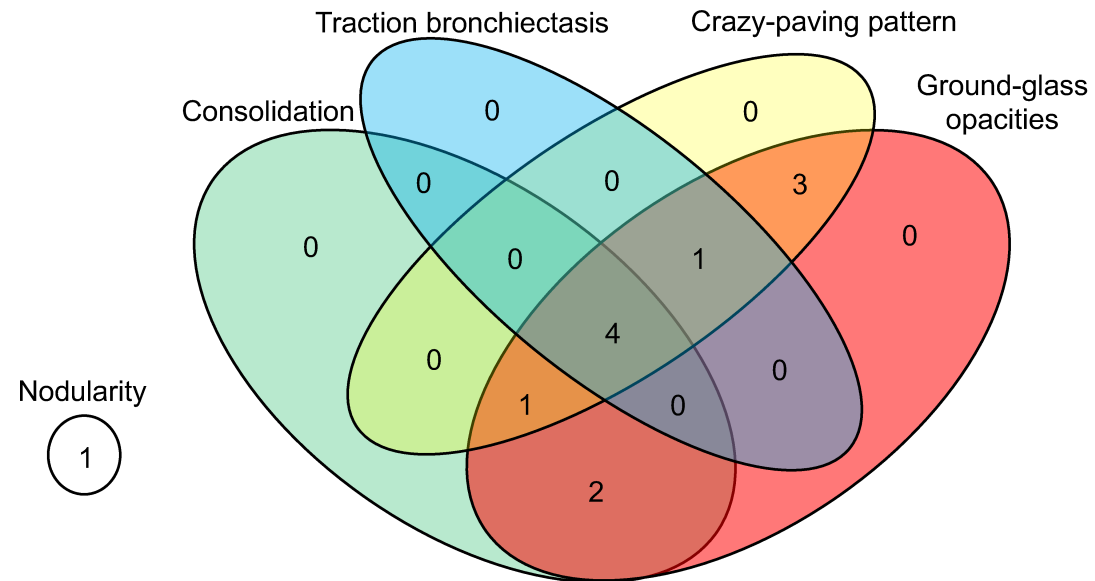


Supplemental Figure 1: Depiction of Infiltrate Type and Laterality of ICI-Pneumonitis upon Diagnostic Chest CT Scan



Treatment group	IVIG	Infliximab	Combination
CIP radiological characteristics			
Consolidation			
with GGOs	1	0	1
with GGOs + crazy-paving pattern	0	1	0
with GGOs + traction bronchiectasis + crazy-paving pattern	4	0	0
GGOs			
with crazy-paving pattern	1	1	1
with crazy-paving pattern + traction bronchiectasis	0	0	1
Nodularity alone	1	0	0
Laterality			
Unilateral	2	1	0
Bilateral	5	1	3