

Figure S1. Representative ISH and P16 images of HPV-positive and HPV-negative head and neck squamous cell carcinoma tissues (magnification, x200). Scale bar, 100 μ m. ISH, *in-situ* hybridization; HPV, human papillomavirus.

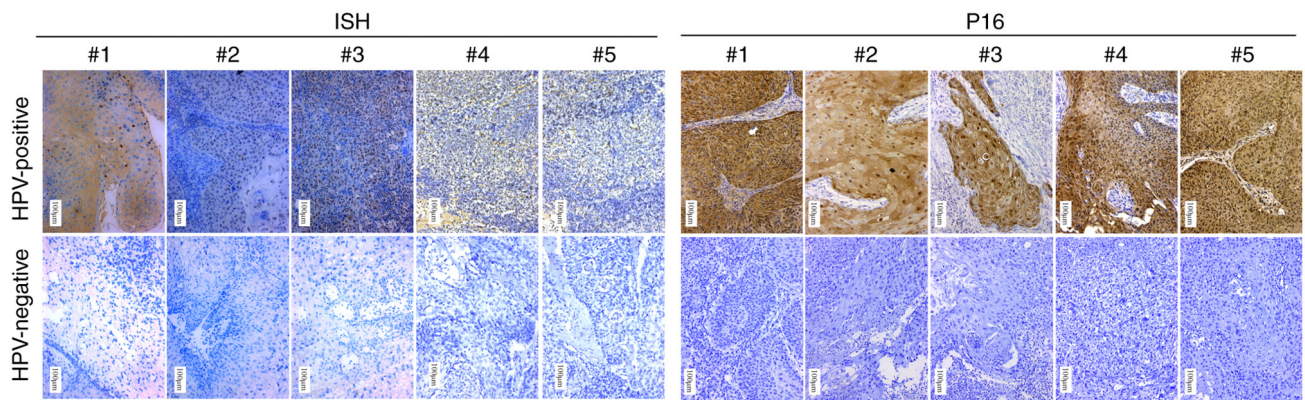


Figure S2. Supplementary immunohistochemistry images of SRRT, CHEK2, SNRPE, PSMC2, ORC5, S100A7 and KRTDAP staining in HPV-negative HNSCC, HPV-positive HNSCC and adjacent tissues (magnification, x200). Scale bar, 100 μ m. SRRT, serrate RNA effector molecule; CHEK2, checkpoint kinase 2; SNRPE, small nuclear ribonucleoprotein polypeptide E; PSMC2, proteasome 26S subunit ATPase 2; ORC5, origin recognition complex subunit 5; S100A7, S100 calcium binding protein A7; KRTDAP, keratinocyte differentiation associated protein; HPV, human papillomavirus; HNSCC, head and neck squamous cell carcinoma; N, normal tissues; T, tumor tissues.

