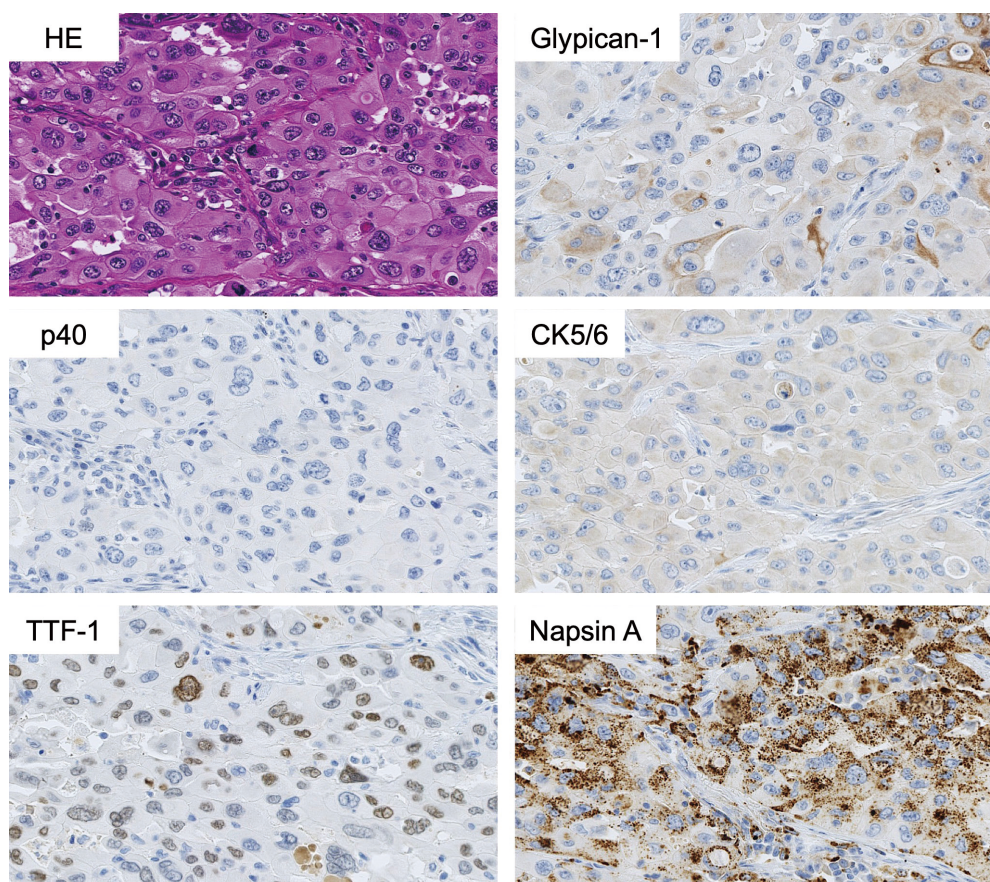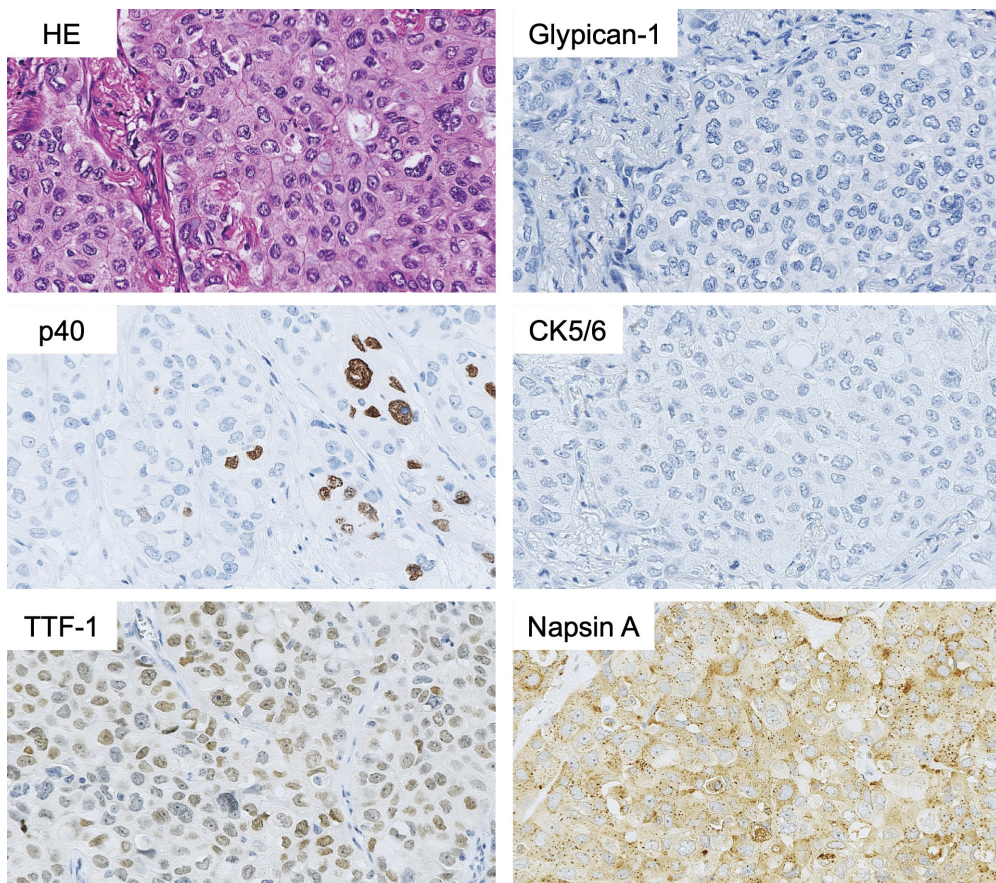


**Figure S1** One exceptional case of glypican-1-positive solid lung adenocarcinoma (1+). The tumor cells were immunohistochemically stained negative for p40 and cytokeratin 5/6 but were positive for thyroid transcription factor-1 (3+), and napsin A (3+).



**Figure S2** One exceptional case of p40-positive solid lung adenocarcinoma (1+). The tumor cells were immunohistochemically stained negative for glypican-1 and cytokeratin 5/6 but were positive for thyroid transcription factor-1 (2+) and napsin A (3+).