

Supplementary Online Content

Yang P, Chiang PW, Weleber RG, Pennesi ME. Autosomal dominant retinal dystrophy with electronegative waveform associated with a novel *RAX2* mutation. *JAMA Ophthalmol*. Published online March 19, 2015. doi:10.1001/jamaophthalmol.2015.0357.

eFigure 1. Electroretinogram Component Overlay of Patients IV-4, III-12, and III-5

eFigure 2. Fundus Autofluorescence of Patients III-12 and III-5

eFigure 3. Multifocal Electroretinogram of Patient III-5

This supplementary material has been provided by the authors to give readers additional information about their work.

eFigure Legends

eFigure 1: Electroretinogram Component Overlay of Patients IV-4, III-12, and III-5

Patient III-4's component overlay was not available. OD, right eye. OS, left eye. μV , microvolts. ms, milliseconds.

eFigure 2: Fundus Autofluorescence of Patients III-12 and III-5

y/o, years old.

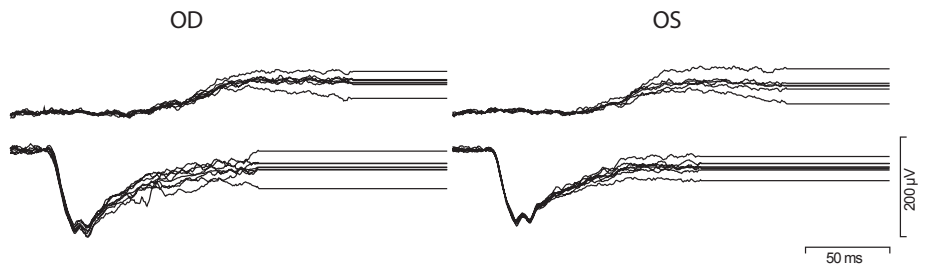
eFigure 3: Multifocal Electroretinogram of Patient III-5

OD, right eye. OS, left eye. nV, nanovolts. ms, milliseconds.

IV-4

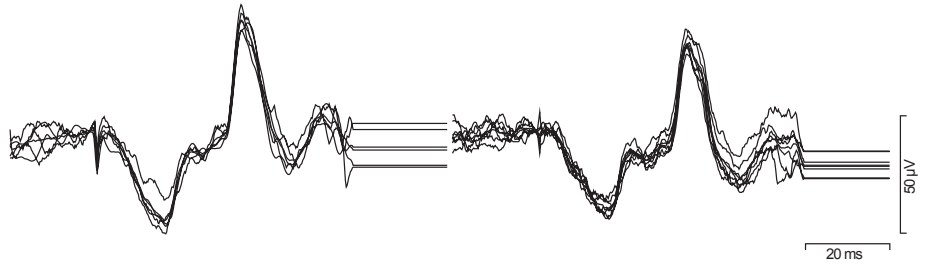
Scotopic Single Flash

Dim White
Bright White



Photopic Single Flash

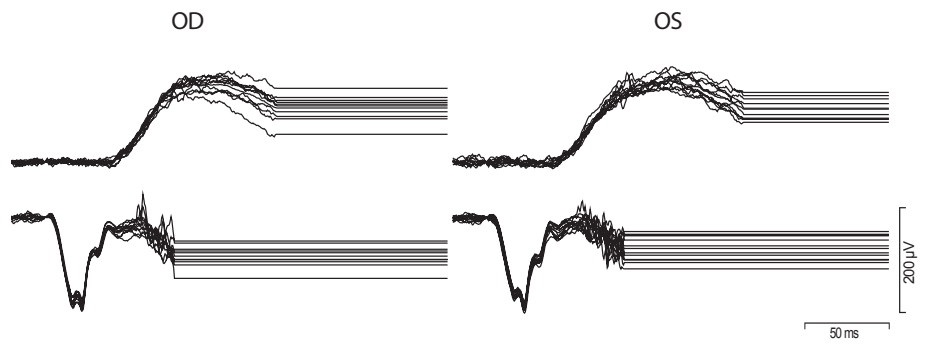
Bright White



III-12

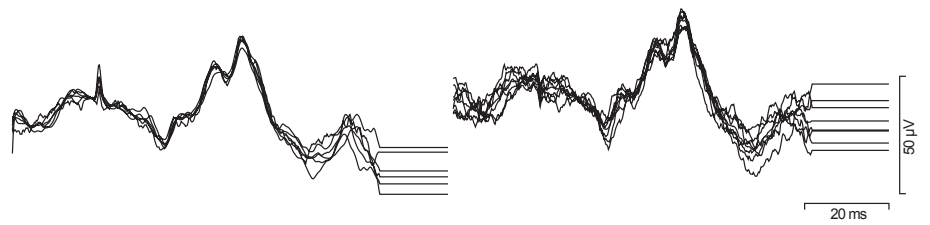
Scotopic Single Flash

Dim White
Bright White



Photopic Single Flash

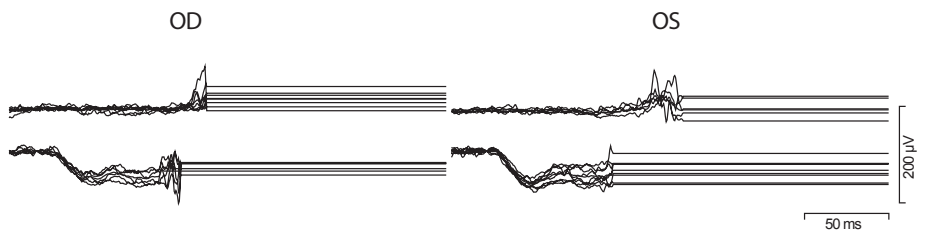
Bright White



III-5

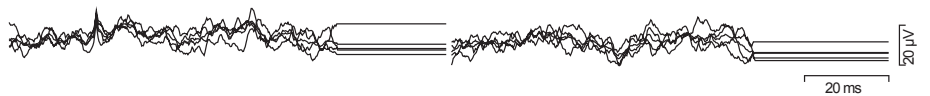
Scotopic Single Flash

Dim White
Bright White

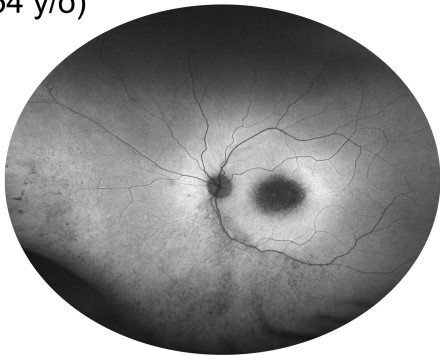
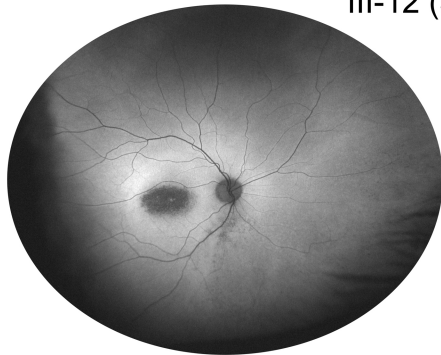


Photopic Single Flash

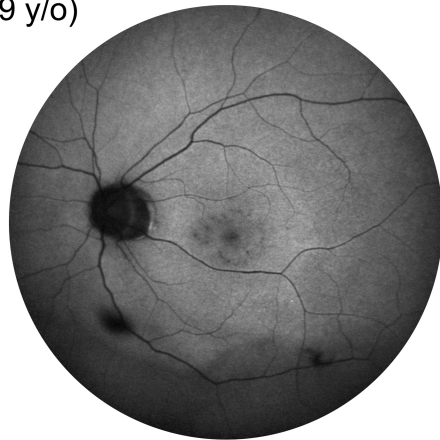
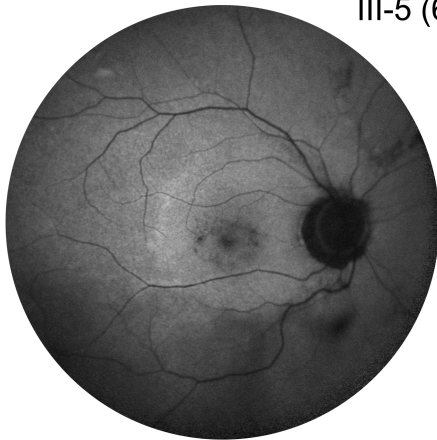
Bright White



III-12 (54 y/o)




III-5 (69 y/o)



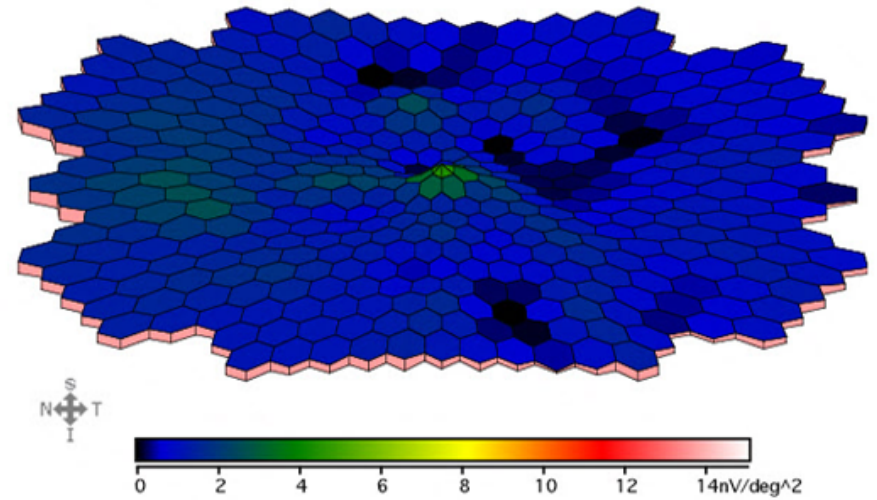
III-5

First Order Summary - OD

Traces




Amplitude Density



First Order Summary - OS

Traces



Amplitude Density

