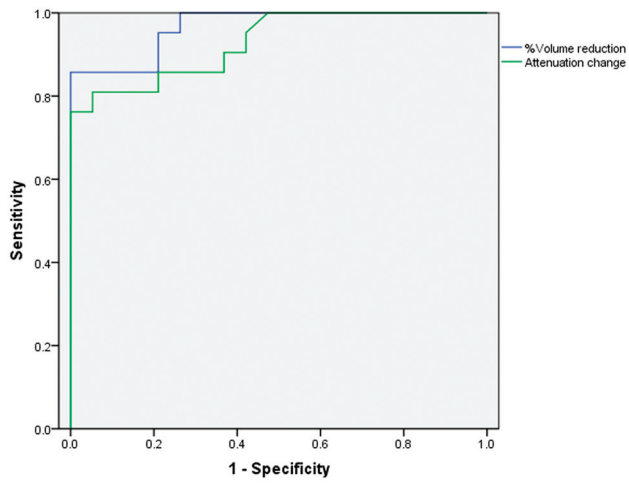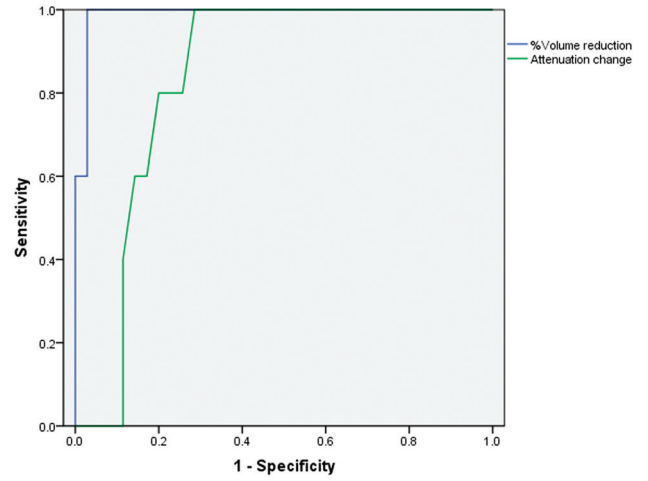


On-line Fig 1: The ROC curves of the volume reduction % and attenuation change to diagnose severe dysfunction of the parotid gland.



On-line Fig 2: The ROC curves of volume reduction % and attenuation change to diagnose severe dysfunction of the submandibular gland.