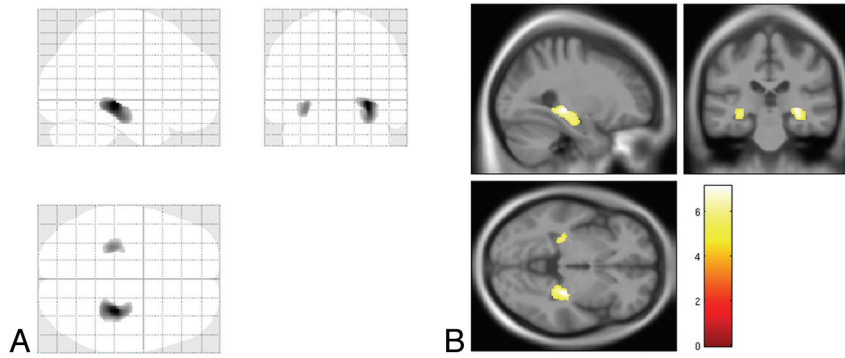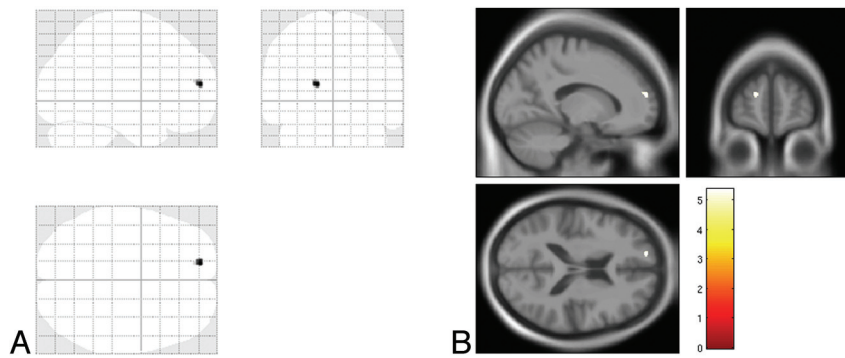


ON-LINE FIG 1. SPM8 “glass brain” representation of voxel-based morphometry analysis showing significant clusters of cortical GM atrophy in the right and left hippocampus and parahippocampal gyrus, in patients with Alzheimer disease as compared with healthy control subjects ($P < .05$, with family-wise error rate correction) in A. Superimposition of the clusters in B onto T1 template.



ON-LINE FIG 2. SPM8 “glass brain” representation of voxel-based morphometry analysis showing a significant cluster of cortical GM atrophy in the left superior frontal gyrus in patients with amnesic mild cognitive impairment as compared with healthy control subjects ($P < .05$, with family-wise error rate correction) in A. Superimposition of the cluster in B onto T1 template.