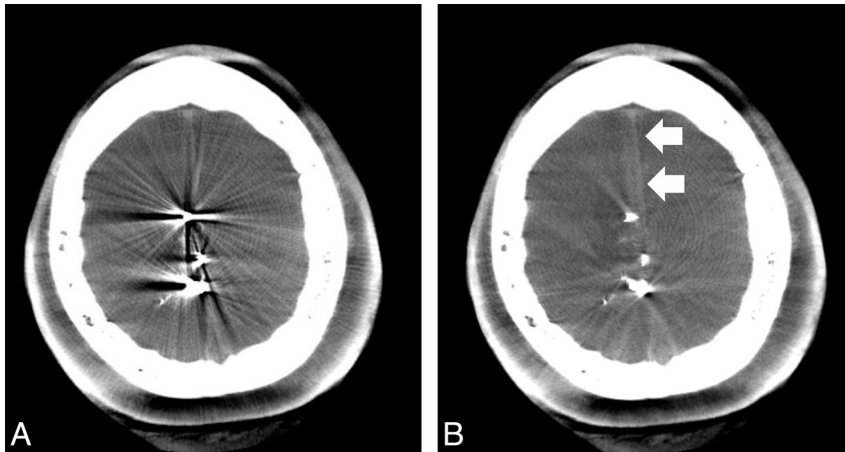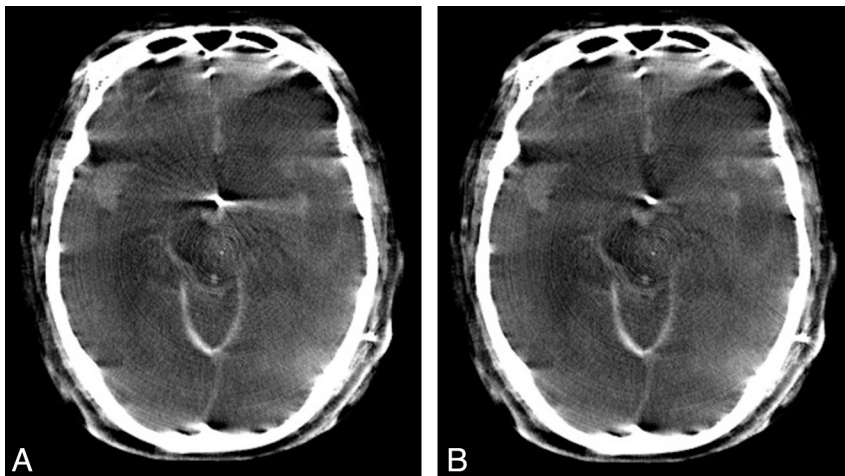


**ON-LINE FIG 1.** Illustrative case 2. FDCT without MAR (A) and with MAR (B) after Onyx embolization of a right-sided frontal AVM. The streak artifacts are substantially reduced after MAR correction, allowing better visualization of adjacent parenchyma and subdural hemorrhage (arrows).



**ON-LINE FIG 2.** Illustrative case 3. FDCT without MAR (A) and with MAR (B) after shunt drainage for subarachnoid hemorrhage–related hydrocephalus. The streak artifacts are substantially reduced, but the postcorrected image does not provide additional diagnostic information.