


Patient n°2



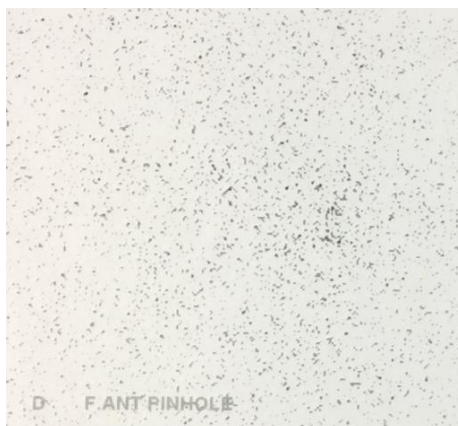Patient n°8




Patient n°11



Patient n°14



Patient n°16



Supplementary Figure

123 iodine thyroid scintigraphy of patients with type 2 AIT.