

COX-2 in non- malignant tissue of vulva

S1

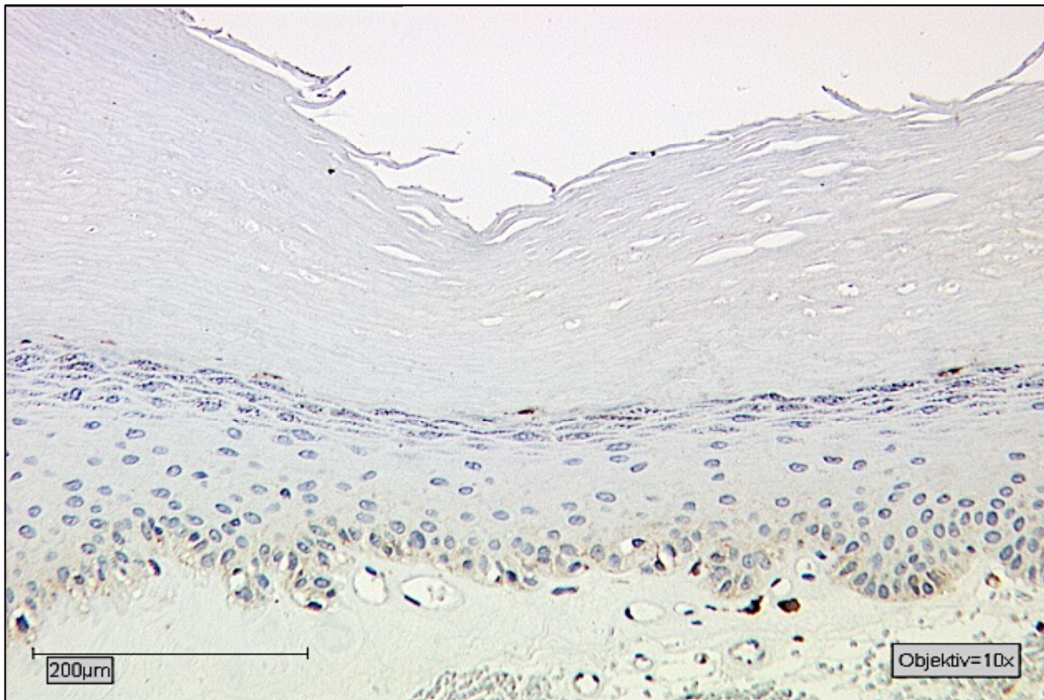


Figure S1
Immunohistochemistry staining of COX-2 (10× magnification) showing staining behavior in non-malignant vulvar tissue of patient without vulvar cancer manifestation.

PPAR γ in non- malignant tissue of vulva

S2

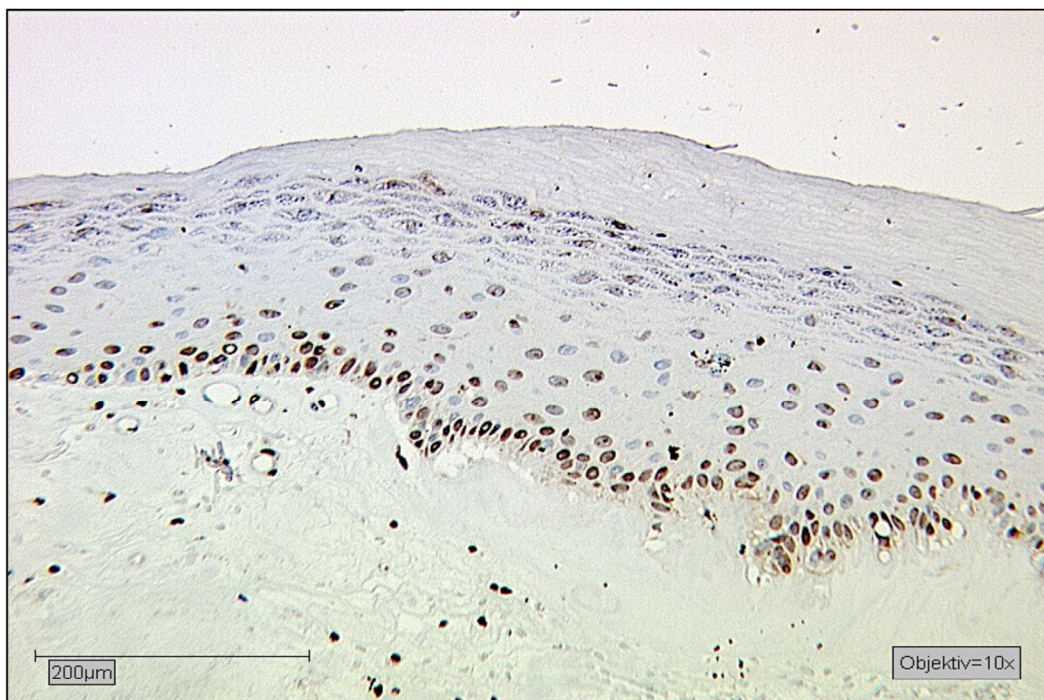


Figure S2
Immunohistochemistry staining of PPAR γ (10× magnification) showing staining behavior in non-malignant vulvar tissue of patient without vulvar cancer manifestation.