

Supplemental data

***SPEN* haploinsufficiency causes a neurodevelopmental disorder overlapping proximal 1p36 deletion syndrome with an epismature of X chromosomes in females**

Francesca Clementina Radio, Kaifang Pang, Andrea Ciolfi, Michael A. Levy, Andrés Hernández-García, Lucia Pedace, Francesca Pantaleoni, Zhandong Liu, Elke de Boer, Adam Jackson, Alessandro Bruselles, Haley McConkey, Emilia Stellacci, Stefania Lo Cicero, Marialetizia Motta, Rosalba Carrozzo, Maria Lisa Dentici, Kirsty McWalter, Megha Desai, Kristin G. Monaghan, Aida Telegrafi, Christophe Philippe, Antonio Vitobello, Margaret Au, Katheryn Grand, Pedro A. Sanchez-Lara, Joanne Baez, Kristin Lindstrom, Peggy Kulch, Jessica Sebastian, Suneeta Madan-Khetarpal, Chelsea Roadhouse, Jennifer J. MacKenzie, Berrin Monteleone, Carol J. Saunders, July K. Jean Cuevas, Laura Cross, Dihong Zhou, Taila Hartley, Sarah L. Sawyer, Fabíola Paoli Monteiro, Tania Vertemati Secches, Fernando Kok, Laura E. Schultz-Rogers, Erica L. Macke, Eva Morava, Eric W. Klee, Jennifer Kempainen, Maria Iascone, Angelo Selicorni, Romano Tenconi, David J. Amor, Lynn Pais, Lyndon Gallacher, Peter D. Turnpenny, Karen Stals, Sian Ellard, Sara Cabet, Gaetan Lesca, Joset Pascal, Katharina Steindl, Sarit Ravid, Karin Weiss, Alison M.R. Castle, Melissa T. Carter, Louisa Kalsner, Bert B.A. de Vries, Bregje W. van Bon, Marijke R. Wevers, Rolph Pfundt, Alexander P.A. Stegmann, Bronwyn Kerr, Helen M. Kingston, Kate E. Chandler, Willow Sheehan, Abdallah F. Elias, Deepali N. Shinde, Meghan C. Towne, Nathaniel H. Robin, Dana Goodloe, Adeline Vanderver, Omar Sherbini, Krista Bluske, R. Tanner Hagelstrom, Caterina Zanus, Flavio Faletra, Luciana Musante, Evangeline C. Kurtz-Nelson, Rachel K. Earl, Britt-Marie Anderlid, Gilles Morin, Marjon van Slegtenhorst, Karin E.M. Diderich, Alice S. Brooks, Joost Gribnau, Ruben G. Boers, Teresa Robert Finestra, Lauren B. Carter, Anita Rauch, Paolo Gasparini, Kym M. Boycott, Tahsin Stefan Barakat, John M. Graham Jr., Laurence Faivre, Siddharth Banka, Tianyun Wang, Evan E. Eichler, Manuela Priolo, Bruno Dallapiccola, Lisenka E.L.M. Vissers, Bekim Sadikovic, Daryl A. Scott, Jimmy Lloyd Holder Jr., and Marco Tartaglia

SUPPLEMENTAL MATERIALS: CASE REPORTS

Subject 1

The proband, a female, is the second child of healthy non-consanguineous Italian parents. Family history was unremarkable. She was born beyond the term of a pregnancy complicated by treatment of abortion. Birth weight was 3,500 g (62th pctl, +0.31 SD). Length, OFC and Apgar scores were not available. Perinatal period was complicated by feeding and swallowing difficulties due to hypotrophy of masticatory muscles. Developmental milestones were delayed (she walked alone at 30 months, first words at 3 years). She presented with gross and fine motor delays and auto-aggressive and repetitive/stereotypic behaviors. The average IQ total score was 48 (scale unavailable).

Clinical evaluation at 6 years disclosed hypotonic face, high anterior hairline, bitemporal narrowing and frontal bossing, lateral sparse eyebrows, hypertelorism, deep-set eyes, bilateral epicanthus, small palpebral fissures, low-set ears with large uplifted earlobe, bulbous nose and flattened nasal bridge, long philtrum with thick columns, thin upper lip, mild micrognathia, rounded chin, high narrow palate. Brachydactyly with low-implanted thumbs, bilateral pes cavus, mild pseudo-valgus deformity of tibia, hemangioma planum of the right subclavian region, dry-skin and nails hypoplasia were noted. At the last evaluation, height was 114 cm (42nd pctl, -0.2 SD), weight 29 kg (>99th pctl, +2.6 SD) and OFC 52.5 cm (69th pctl, +0.51 SD). Episodic urinary incontinence and constipation were reported.

Brain MRI, bone age assessment and abdominal ultrasound were normal. Echocardiography showed mild mitral insufficiency. Audiological examination by pure tone audiometry was normal. No seizure had been reported.

Biochemical and metabolic screening as well as postnatal genetic analyses including array-CGH were normal.

Subject 2

The proband, a female, was the second child of healthy non-consanguineous parents. She was born at 39 WG after an uneventful pregnancy; her birth weight was 4,500 g (98th pctl, +2.14 SD). She soon presented with respiratory distress, hypotonia and an EEG evidenced cerebral impairment. Transfontanellar ultrasound identified an ependymal hemorrhage that was initially ascribed to the neonatal ischemia. She had developmental delay (she sat at age 15 months, walked at 23 months) and had language delay (she spoke a few words at age 5 years). At age 10 years, clinical examination identified coarse oval face with synophrys, bulbous nose, anteverted nares, prominent lips, macroglossia, macrodontia with poorly implanted teeth, high arched palate, camptodactyly of all fingers and stretch marks. Neurological exam evidenced buccofacial apraxia. At the last evaluation, the height was 170 cm (85th pctl, +1.05SD), weight 105 kg (>99th pctl, +3.37SD) and OFC 57.5 cm (98th pctl, +1.98SD). Her mother reported episodically aggressive behavior. Brain MRI evidenced cerebellar atrophy. High-resolution karyotype, fragile X syndrome, Angelman syndrome, Prader-Willi syndrome, Rett syndrome, Coffin-Lowry syndrome, and CDG syndrome analyses were negative, array-CGH and metabolic test were normal. At age 15 years, gynoid obesity and cutaneous infiltration appeared.

Subject 3

The proband, a male, is the first child of healthy non-consanguineous Western European parents. Family history was unremarkable. He was the product of a single gestation to a 27-year-old mother and 39-year-old father. The pregnancy history was unremarkable. He was born at 42 weeks gestation via emergent cesarean section when the mother's blood pressure dropped. The born weight was 4,140 g (92th pctl, +1.43 SD) and length 50.8 cm (38th pctl, -0.31 SD). OFC and Apgar scores are not available. Perinatal period was complicated by feeding difficulties. He soon presented with low muscle tone, weakness of trunk and legs with gross motor delay. Developmental milestones were delayed (he rolled at 6 months, sat at 9 months, and was very unsteady when weight bearing at 15 months). Due to the delays first noted at the age of 9 months, he started physical and occupational therapy for hypotonia, trunk and leg weakness, and gross motor delays. Clinical evaluation at 15 months disclosed bilateral epicanthal folds, medial flaring of eyebrows, flattened nasal bridge, and broad upturned triangular nasal tip with long philtrum. He had overfolded superior helices, which were posteriorly angulated, and prominent antihelices, a slightly small jaw, a rounded chin, and small teeth with erupting premolars in the lower jaw. He had a prominent xiphoid tip with normal palm and finger creases and relatively small 5th toenails with bilateral clinodactyly. Neurologic exam was significant for persistent hypotonia, mainly in the lower extremities. He made good eye contact and was interested in the surroundings but experienced rapid mood changes: he became upset easily but quieted when soothed by a care provider. At age 21.5 months, height was 85.6 cm (57th pctl, +0.16 SD), weight 12.3 kg (71th pctl, +0.56 SD), and head circumference 49.5 cm (76th pctl, +0.7 SD). He had bilateral epicanthal folds, a broad flat nasal bridge and prominent nasal tip, slightly over-folded superior helices, and crowded dentition in the small lower jaw. Neurologic examination was significant for mild global intellectual disability, which affected both motor and speech development. He had generalized hypotonia in the lower extremities with tight heel cords, and upon standing with support, he stood on his tip toes. He had a short attention span and stereotypical movements consisting of hand flapping, head shaking, and hyperventilation. He was estimated with a developmental delay corresponding at around age 11 months when he was at 21.5 months.

Brain MRI and tandem mass spectroscopy newborn screening were normal. Urine organic acids, plasma amino acids were not suggestive of any specific metabolic defect; T4 and pyruvate were within normal limits. He had a slightly elevated lactic acid and CK. SNP Array, Prader-Willi/Angelman methylation analysis, and Fragile X testing were normal. Mitochondrial genome analysis was normal.

Subject 4

The proband, a male, is the first child of non-consanguineous Hispanic parents. Family history was unremarkable. He was the product of a single gestation to a 31-year-old mother and 34-year-old father. Pregnancy history was unremarkable. He was born at 40 and 3/7 weeks gestation via spontaneous vaginal delivery. He weighed 3,289 g (32nd pctl, -0.46 SD) and measured 52.7 cm (90th pctl, +1.3 SD) in length at birth. He passed his newborn hearing screen and metabolic screening and was released at home on day 3 after birth.

Development was delayed; he sat at 9 months, crawled at 12 months, and walked at 14 months. His first words were at 14 months. He experienced speech regression. At last

evaluation at 4 years 9 months, he was able to follow instructions, was more interactive, could count to 10, and knew animal sounds. Due to his delays, he received physical and occupational therapy, as well as a child development program for 5 days/week 4 hours/day, and ABA therapy for 4 days/week 2 hours/day. Clinical evaluation at 4 years 8 months noted a low frontal hairline and synophrys. Height was 110.7 cm (74th pctl, +0.65 SD), weight 22 kg (95th pctl, +1.63 SD), and head circumference 51 cm (44th pctl, -0.14 SD).

Tandem mass spectroscopy newborn screening was normal. SNP Array and Fragile X testing were normal.

Subject 6

The proband is an 11-year-old male born to a 27-year-old G3 P2-3 mother at 37 weeks. He was jaundiced at birth, and required hospitalization for pneumonia and failure to thrive. He was born with left-sided polydactyly of the hand, which underwent surgical removal. On physical exam, notable features included bitemporal narrowing, arched eyebrows with synophrys, slight epicanthus, thin upper lip, teeth abnormalities, and high narrow palate with submucosal cleft. He also had a left preauricular ear tag, long eyelashes in a double row, coarse scalp hair, retromicrognathia with a severe overbite, wide palms, and cutis marmorata. He had DD (walked independently at 18 months of age, first words at 4 years of age) with notable ID in the absence of formal IQ testing. He was noted to have ADHD, autism spectrum disorder, and aggressive behavior requiring hospitalization on multiple occasions. He had a history of recurrent ear infections. Eye abnormalities included intermittent left sided esotropia, left sided amblyopia, astigmatism and hyperopia. His last evaluation noted poor growth parameters. Height was 136 cm (14^o pctl, -1.06 SD), weight 26.6 kg (4^o pctl, -1.73 SD), OFC 51 cm (3^o pctl, -1.95 SD) and BMI 14.38 (4^o pctl, -1.72SD). Due to sleep disordered breathing, he underwent adenoidectomy and tonsillectomy.

Chromosome array analysis, karyotype, FISH for 22q11.2 deletion syndrome, sterol panel, carbohydrate deficient transferrin analysis, bone age study, and skeletal survey were unremarkable. Maternal testing identified the *SPEN* variant found in the proband. Her mother was also reported to have speech issues, motor delays and learning disabilities.

Subject 7

This subject, a female, is the second child of non-consanguineous French Canadian/Serbian parents. The mother is healthy, and the father has well-controlled seizures. Family history is otherwise unremarkable. She was born at term after an uneventful pregnancy. Her birth weight was 3,250 g (43rd pctl, -0.18 SD), head circumference 33 cm (17th pctl, -0.97 SD), and length 49 cm (31st pctl, -0.50 SD). Apgar scores were 9 and 9 at 1 and 5 minutes. Heart murmur was discovered during the routine neonatal evaluation and cardiac echo confirmed a cardiac defect (PDA, PFO, VSD). She was assessed for multiple hemangiomas at 9 months of age.

She has a history of developmental delay. At 12 months, she was not yet crawling, and showed no interest in grabbing objects. By 15 months she was crawling and cruising. By 21 months, she was deemed to have caught up with gross and fine motor abilities and occupational activity and physiotherapy were discontinued. At 21 months, the proband

continued to have expressive language delay and at 3 years expressed herself with single words, and speech therapists were working on vocabulary and pronunciation.

Clinical evaluation at 2 years and 11 months revealed flare of the lateral third of eyebrows with mild synophrys, puffiness around the eyes with hypertelorism, telecanthus, long eyelashes, full lips, large frontal incisors, and pointed chin. Hypopigmented patches were noted at the lower extremities.

At last evaluation, height was 92.1 cm (28th pctl, -0.6 SD), weight 14.9 kg (75th pctl, +0.67 SD), and head circumference 48 cm (17th pctl, -0.95 SD).

Chromosomal microarray analysis provided normal results.

Subject 8

The proband, a male, is the first child of non-consanguineous parents of European descent, with a history of one spontaneous abortion following the proband's birth. Family history is only relevant for mom's Chiari malformation, hypercholesterolemia, and scoliosis. He was product of a single gestation to a 31-year-old mother and 30-year-old father. Pregnancy history was significant for mom's gestational diabetes that did not require any treatment.

He was born at 40 weeks 6 days gestation via spontaneous vaginal delivery. His APGAR scores were 9 at 1 minute and 9 at 5 minutes. He weighed 3,635 g (72th pctl, +0.57 SD), measured 52 cm in length (29th pctl, +0.56 SD), and head circumference of 33.75 cm (87th pctl, +1.12 SD) at birth. He passed his newborn hearing screen. He had a borderline TSH and T4 on his new born screening that was normal when repeated. He was released home on day 2 after birth.

His gross motor development was subsequently delayed, and he rolled over at 6-7 months, sat unsupported at 7 months, crawled at 10 months, and started walking alone at 16 months. His first words were at 12 months. He attends preschool 3 days a week and received physical therapy twice a week for 12 weeks. He was wearing Supra Malleolar Orthotics (SMOs) for his hyperflexible ankles. His initial evaluation was at 23 months of age. He presented with hypotonia and gross motor delay. He also had hypermobile ankles, and frequent falls. Physical examination revealed a height of 85.1 cm (27th pctl, -0.61 SD), a weight of 11.805 kg (46th pctl, -0.11 SD), and a head circumference of 48 cm (46th pctl, -0.09 SD). Bilateral epicanthal folds were noted. He was making words and had good eye contact. He was interacting with the surrounding and playful. His ankles were flexible, but he was able to walk and jump without SMOs. His gait was appropriate for his age.

He was reevaluated at age 4 years. He started making sentences at 3 years and was toilet trained at 3 years as well with no history of regression. He receives speech therapy once per week due to drooling, pronunciation issues, and low tone. His expressive language is delayed. He receives occupational therapy once per week due to poor hand use, difficulties with using pencil and utensils. He is about to begin to play therapy. He is in preschool and was noted to be slightly behind grade level. He has impulsivity as well as sensory craving problems. He has behavior issues such as hitting and grabbing classmates and has personal boundary issues.

He has had a normal echocardiogram. On repeat examination, height was 101 cm (Z score - 0.22), weight 16.7 kg (Z score 0.28), and OFC 49.5 cm (25-30 pctl). At clinical exam, he showed epicanthal folds, simplified and fleshy ear lobes bilaterally. Faint erythema on the forehead, and a hyperactive and friendly behavior.

He had a normal karyotype and CGH array. Whole exome sequencing sent to GeneDx found a heterozygous maternally inherited pathogenic variant in LDLR gene.

Subject 9

The subject, a female, was born at 37 weeks of gestation via spontaneous vaginal delivery to a 28-year-old G2P2 mother. Pregnancy was complicated by maternal obesity, placenta previa, and preeclampsia. The mother required weekly progesterone shots starting at 14 weeks gestation, and prenatal ultrasounds were concerning for poor fetal growth. Delivery was complicated by premature and prolonged rupture of the membranes. She was cyanotic at birth and about 10 minutes of positive pressure ventilation in addition to 24 hours of double bank phototherapy. She was discharged at 7 days of life due to maternal complications requiring blood transfusions and blood pressure management. She passed the newborn hearing and congenital heart disease screenings. Birth weight was 2,630 g (14th pctl, -1.07 SD), birth length 45.7 cm (6th pctl, -1.52 SD), and birth head circumference 32.4 cm (17th pctl, -0.95 SD).

She was diagnosed with mild laryngomalacia at around 4 months of age. At 9 months, she was diagnosed with gross motor delay. She did not roll over completely until after 8 months. She started army crawling at 12 months, crawling at 16 months, and walking at around 20-21 months. She started babbling at 15 months, and currently pronounces two words in Spanish. She started receiving physical therapy at 1 year of age and speech therapy at 2 years.

She was diagnosed with autism at age 2 years based on repetitive behaviors, speech delays and limited eye contact. She was scored using Childhood Autism Rating Scale-2 and Autism Diagnostic Observation Schedule, 2nd Edition, toddler module (ADOS-2).

At 23 months, the subject was hospitalized for acute cerebellar ataxia. Brain MRI showed a single punctate focus, likely the sequelae of grade 1 germinal matrix hemorrhage and an incidental developmental venous anomaly in the left basal ganglia. She had normal renal ultrasound and skeletal survey.

Family history is significant for a 6-year-old sister with ADHD and cognitive delays. Both parents are currently healthy. The rest of the family history was noncontributory.

At 2 years and 2 months of age, she presented for a genetic evaluation due to her history of global developmental delay, autism, and hypotonia. Her weight was 12.7 kg (70th pctl, +0.52 SD), height 84.4 cm (18th pctl, -0.91 SD), and head circumference 46 cm (4th pctl, -1.8 SD). On physical exam, she had bitemporal narrowing, a forehead hemangioma, long and bushy eyelashes, mild synophrys, upslanting palpebral fissures, and puffiness under her eyes with deep creases, bulbous nose, long philtrum, and microretrognathia. She had a soft systolic murmur, bilateral 5th finger clinodactyly, pes planus, a café au lait spot on her left leg, and hypotonia in lower extremities.

Previous negative etiologic testing included chromosome microarray, fragile X testing, plasma amino acids, urine amino acids, and plasma acylcarnitine profile.

Subject 10

The subject, a male, presented with a duplicated right thumb and developmental delays shortly after birth. Pregnancy history was remarkable only for maternal diclectin use. Prenatal testing was not performed; however, an US at 18 weeks was unremarkable. Further work up included brain MRI, which demonstrated bifrontal polymicrogyria. He had gastroesophageal reflux as an infant (now resolved), and has conductive hearing loss and is distinctive in appearance. He is currently in kindergarten at 4 years of age and requires a full-time aide. He has approximately 40-50 words, and the school is also using pictograms to communicate with him. He is also signing a little bit with his hands. He is able to walk up stairs but cannot hop on two feet. He fatigues after 15 minutes of walking. He is unable to dress independently and is not potty trained. He has some aggressive behaviors, such as hand banging, biting, and kicking; however, this is improving. Psychoeducational testing has not yet been done.

His growth parameters are within normal limits. At 4 years of age, his head circumference was 49 cm (21st pctl), height 99.8 cm (>14th pctl), and weight 15.8 kg (33th pctl). At last examination, he showed elongated eyebrows, deep-set eyes, and a wide mouth with prominent lower lip.

Investigations include a normal array and clinic exome sequencing, which did not identify any relevant variant in previously identified disease genes. He has also had a normal renal ultrasound and echocardiogram.

Subject 11

The proband is a 6-year-old female, the only child born to non-consanguineous parents, with a history of two spontaneous abortions after the proband's birth. Family history is only relevant for a paternal grandfather deceased due to lateral amyotrophic sclerosis.

She was born by cesarean section at 38 weeks of gestation, after an uneventful pregnancy. Her Apgar scores were 9 and 10 at 1 and 5 minutes; weight was 3,165 g (34th pctl, +0.40 SD), length 49 cm (31st pctl, +0.50 SD), and head circumference 31 cm (<3rd pctl, -2.61 SD). Approximately 24 hours after birth, she presented with jaundice needing phototherapy for one day. A neonatal echocardiogram disclosed multiple muscular ventricular septal defects and a patent foramen ovale, without hemodynamic repercussion. There were no other complications during the neonatal period, and she was released from the hospital 72 hours after birth.

Her neuropsychomotor development was subsequently delayed. She sat with support at 10 months and without support at 12 months, walked without support at 22 months. She was very delayed in speaking single words, and currently speaks only a few simple phrases. Her behavior is notable for excessively screaming and crying without reason, having difficulties coping with changes in routine, being too anxious and impatient, as well as occasionally aggressive, and presenting with some stereotypic behavior when too excited. She has no history of seizures.

Laboratory and imaging studies previously performed included normal karyotype and SNParray, an abdominal ultrasound disclosing no abnormalities, while a brain MRI revealing only small areas of signal alteration in T2 and FLAIR in the periventricular white matter, possibly representing gliosis.

Physical examination at 3 years and 9 months of age revealed a height of 107.5 cm (>99th pctl, +3.27 SD), a weight of 22.7 kg (>99th pctl, +3.54 SD), and a head circumference of 50 cm (71st pctl, +0.57 SD). Clinical evaluation disclosed coarse facies, prominent forehead with high anterior hairline, thick eyebrows, wave-shaped eyelids, mildly upslanting palpebral fissures, long and prominent ear lobes, bulbous tip of nose, short philtrum and full and everted upper and lower lips.

Subject 12

The proband is a 4-year-old female born to non-consanguineous parents with an unremarkable family history. The pregnancy was complicated by pleural effusion and polyhydramnios between 21 and 26 weeks. Apgar scores were 8 and 9 at one and five minutes. Perinatal complications included feeding difficulties with failure to thrive (weight below birth weight at 2 months of age). Global developmental delay and hypotonia were noted (first sat upright at 18 months, began walking at 2.5 years, childhood apraxia of speech). The proband was found to have a sacral dimple at 2 years of age when a tethered cord was discovered and surgically corrected.

Upon examination at 4 years of age, the proband continues to display feeding difficulties with reflux, constipation, and vomiting. She has learning difficulties, speech delay, and occasional shy or aggressive behavior. Dysmorphic features include oval face, hypoplastic midface, full supraorbital region, long thin eyebrows, epicanthal folds, long palpebral fissures, everted on the lateral side, flat nasal bridge, short triangular nose, and prominent and low-set ears. Other physical features include fifth finger clinodactyly, terminal phalanx shortening of fingers, hypoplastic nails, and eczema. At the last evaluation, her height was 95.30 cm (4th pctl, -1.73 SD), and her weight was 15.10 kg (33rd pctl, -0.45 SD).

An MRI at 2 years of age showed thinning of the corpus callosum and delayed myelination. A follow-up MRI at 4 years of age showed myelination within normal limits and no malformations. Biochemical and metabolic testing for organic acids, creatine, and lysosomal urine screen were all normal. CGH-array was normal.

Subject 13

The proband, aged 4 years and 5 months, is the first male child of a healthy 36-year-old Italian man and of a non-consanguineous 34-year-old Italian woman with a negative family history. He has a healthy brother. The pregnancy history was unremarkable. Labor was induced at 43 weeks of gestation using vacuum device. Birth weight and length were at the 75th centile, head circumference at the 97th centile, Apgar scores 9 and 10 at 1 and 5 minutes. In the first weeks, he had poor sucking. Subsequently, psychomotor and language retardation and drooling during the day were noticed. According to his parents, after the birth of his brother, he had temper tantrums and tendency to avoid contacts with children of the same age. His clinical diagnosis includes global developmental and expressive language delay, mild generalized muscular hypotonia, and dyspraxia. At the age of 5 years, she scored

60 on the Griffiths III Scale, with the lowest scores regarding the locomotor development (51) and the personal-social development (<50). At the age of 4 years, an audiometry test detected hyperacusia and at 4 years and 5 months retinal hypopigmentation was observed, and ocular albinism was suspected.

An array CGH test detected a 132 Kb duplication in 19q13.33 (48,162,474-48,294,793) (hg19) of maternal origin, classified as likely benign.

At 5 years and 4 months, weight was at 50-75th centile, height at 90-97th centile, and head circumference at the + 0.43 SD. Physical exam findings included mild dolichocephaly, frontal bossing and high forehead, mild synophrys, long palpebral fissures (+ 2 SD), long philtrum (mean +1 SD). He showed marked hyperextensibility at elbows, moderate hyperextensibility of wrist and fingers, and mild hirsutism.

Subject 14

The proband, a female, is the third child of healthy unrelated parents. She was born at term by cesarean section with birth weight 3,846 g (98th pctl, +2.08 SD). Soon after birth, she was diagnosed with a moderate perimembranous ventricular septal defect and secundum atrial septal causing cardiac failure that responded to medical therapy and by age 5 years had closed spontaneously.

Her development has been delayed since infancy. She walked and started speaking single words at the age of 3 years. She has sensory processing difficulties and difficulty mixing with other children. At the age of 7 years she displays difficulties with managing her behavior, emotional dysregulation, rigidity and inflexibility, intolerance of delays, and difficulties with social interactions and communication. Full-scale IQ has been measured at 65.

She has normal vision and a mild conductive hearing loss treated with grommets. Growth parameters show height and weight tracking near the 95th centile and head circumference near the 50th centile. She has a partial subluxation of the left hip.

An MRI scan at age 2 years showed mild ventriculomegaly and a generalized reduction in white matter volume. An EEG at age 3 years showed nonspecific abnormalities. Urine amino and organic acids, glycosaminoglycans, and chromosome microarray were normal.

She has some distinctive facial features comprising a relatively round face, broad forehead, mild plagiocephaly, periorbital fullness, hypertelorism, fine arched long eyebrows, long philtrum, and a relatively thin upper lip. She has pes planus and tight Achilles bilaterally, and slightly hypoplastic fifth fingers.

Subject 15

This subject is a 10-year-old female, the only child of non-consanguineous parents, the mother being of European descent and the father of North African descent. She was born at 42 weeks gestation after an uneventful pregnancy by emergency C-section for failure to progress and fetal distress. Birth weight was 3,590 g (66th pctl, +0.40 SD), and OFC 33 cm (11th pctl, -1.22 SD). She was slow to establish feeding and late in achieving motor milestones: sitting at 12 months, walking at 2 years. She continues manifesting coordination difficulties. Language development was slow and through childhood, she developed a behavior falling into the autistic spectrum. She has significant anxiety, but can be

inappropriately friendly to strangers, is prone to sudden tantrums, prefers known routines, and has sensory issues relating to touch and food. Overall, she is a happy child. At mainstream school she requires one-to-one support and is globally delayed but no formal IQ testing has been performed. She always manifested joint laxity, suffered recurrent UTIs, and was diagnosed with mild bilateral hydronephrosis at 7 years of age. She has had otitis media with perforated tympanic membranes and hyperacusis. No vision anomaly has been reported. No seizures have occurred. She has mild persisting capillary hemangiomas on her upper lip, above the right eye, and posterior neck; she has marked dental overcrowding. She has bitemporal narrowing, slightly downslanting palpebral fissures with mild epicanthal folds, slightly over-folded superior helices, absent ear lobes, slightly short philtrum, and rounded chin. Cohen syndrome has been suspected, but there is no evidence of neutropenia, no pigmentary retinopathy, and no variants were found in *VPS13B*. She has slightly tapering fingers, which are also slightly short, as are the toes, particularly the 5th digits. She has mild central obesity, with weight 47.8 kg (99th pctl,+2.5 SD) and height just less than 50th centile at the age of 9 years 4 months, while at the age of 8 years 11 months her OFC was 52.0 cm (42nd pctl, -0.21 SD). She showed signs of early breast development at age 7 years but has not yet reached menarche.

At 18 months, she had normal brain and spine MRI scans. Following normal chromosome microarray and negative tests for Cohen syndrome, trio exome analysis identified a de novo frameshift variant in *SPEN*, c.7373del, p.Pro2458Argfs*2.

Subject 16

The subject is a female fetus with a diagnosis of corpus callosum agenesis at 27 weeks of gestation. The mother is a 29-year-old healthy woman. It was the second pregnancy of unrelated parents who have had a first healthy boy of 7 years. Family history was marked by seizures (maternal sister), intellectual disability of unknown origin in four of six cousins of the mother's paternal aunt, and Down's syndrome and deafness in paternal nephews. Brain ultrasound findings, confirmed by brain fetal MRI, showed normal biometrics, complete corpus callosum agenesis in association with nodular subependymal heterotopias, and lack of Sylvian valley genesis. Microbiological analyses, fluorescence in situ hybridization and comparative genomic hybridization on amniotic fluid were normal. Fetopathological examination of the eutrophic female fetus, after termination at 29 weeks of gestation, confirmed the corpus callosum agenesis and the presence of a pericallosal artery and olivary heterotopias. Brain biometrics were normal. Facial dysmorphic features included hypertelorism, small mouth, thin upper lip, smooth philtrum, retrognathia, and well-implanted triangular ears, as well as left pulmonary isomerism with two lobes on each side. The placenta was hypotrophic and the placental cord had three normal vessels.

Subject 17

The proband, a boy, is the first child of healthy, distantly consanguineous Lebanese parents. He has two younger healthy sisters. Family history was unremarkable. He was born at term of a pregnancy complicated by frequent vaginal bleeding episodes and miscarriage symptoms. Anthropometric measurements at birth are not available. The postnatal period was reported to be uneventful. Developmental milestones were delayed (he walked independently at 30 months, and language is still limited to simple words or two-word

sentences). He presented gross and fine motor delay and aggressive, defiant, and impulsive behaviors and attention deficit. The average IQ total score was 50 (scale unavailable). Clinical evaluation at 5 7/12 years showed an elongated face, high anterior hairline, bitemporal narrowing, arched eyebrows with a medial flair, apparently wide-spaced eyes with bilateral epicanthus, up-slanting of palpebral fissures, low-set, simplified ears with large earlobes, bulbous nose with prominent nasal tip, flattened nasal bridge and anteverted nares, long flat philtrum, thin upper lip, mild micrognathia, pointed chin and high and narrow palate. Brachydactyly and nail hypoplasia were noted. At the last evaluation, height was 112.8 cm (45th pctl, -0.13 SD), weight 20.2 Kg (59th pctl, +0.24 SD) and head circumference 47.6 cm (<3rd pctl, -2.84 SD). Seizure had not been reported. Biochemical and metabolic screening, and genetic analyses including array-CGH, were normal.

Subjects 18 and 19

The proband is a 17-year-old boy, the second child of healthy non-consanguineous parents of mixed Jewish descent. He was born following an unremarkable pregnancy, via vaginal delivery. Birth weight was 3,250 g (29th pctl, -0.56 SD), and the neonatal course was unremarkable.

He first presented at the age of 3 months with seizures, characterized by staring, eye deviation and tonic posture. Initial electroencephalography (EEG) performed at the time of presentation was normal. Subsequent EEG showed normal background activity with multifocal epileptic discharges. MRI of the brain was normal. The seizures were well controlled with Lamotrigine. Repeated EEG studies were normal, and he stopped treatment at the age of 8 years.

He had delayed speech and cognitive milestones. Gross motor development was normal. He was diagnosed with autism and attention deficit disorder, and attended a special education school. The IQ was between borderline to mild intellectual disability range with higher scores in verbal abilities compared to other fields.

He had hypospadias with surgical correction at 8 years. He had lumbar spine disc herniation with surgical correction at the age of 14 years. At the age of 15 years he started again with seizures characterized by staring spells and drop attacks. EEG showed normal background with generalized 3Hz spike and wave complexes. Repeated brain MRI was normal. Lamotrigine was restarted, and he is currently seizure-free.

He underwent an extensive metabolic evaluation that was normal, including cerebrospinal fluid evaluation (for cell count, glucose, lactate and amino acids) and analysis of plasma amino acids, lactate, acylcarnitine profile, very long chain fatty acids and urine organic acids.

Chromosomal microarray and fragile X testing were normal.

General examination at 17 years disclosed a long face, high nasal bridge, periorbital fullness, bulbous nasal tip, and a pointed chin. At the last evaluation, the height was 168.5 cm (17th pctl, -0.94 SD), and OFC 53.8 cm (7th pctl, -1.5 SD).

Neurological examination was normal.

The proband's sister is 23-year-old and has borderline intellectual disability and communication disorder. The pregnancy was notable for recurrent bleeding. The birth was at term. At the age of 6 months, she was evaluated for hypotonia and strabismus. She had a

basic metabolic workup and brain MRI that were normal. She had motor and speech delay, and attended special education. There is no history of seizures. General examination at 23 years disclosed a long face without significant dysmorphisms. The height was 162 cm (43rd pctl, -0.18 SD), weight 78 kg (96th pctl, +1.76 SD) and OFC 57 cm (95th pctl, +1.63 SD).

Subject 20

The proband is a 20-year-old female of European descent. She is the second of three children of healthy, non-consanguineous parents. Family history was significant for a narcolepsy-cataplexy in her mother. She was born at term via spontaneous vaginal delivery after an unremarkable pregnancy. She did not require resuscitation or prolonged admission to hospital. Birth weight was 3,345 g (53rd pctl, +0.07 SD).

Developmental milestones were delayed. She had poor coordination and gait difficulties. By age 4 years, she was having frequent outbursts and behavioral concerns. At age 10 years, she was diagnosed with a non-verbal learning disorder on psychoeducational testing. At age 14 years, she presented with auditory and visual hallucinations, and was diagnosed with autism spectrum disorder and schizophrenia. She had a neurologic evaluation for ataxia/gait difficulties and tremors of unclear etiology.

On physical examination at age 20 years, her weight was 87.5 kg (99th pctl, +2.53 SD), height 155.7 cm (13rd pctl, -1.14 SD), and head circumference 58.5 cm (>99th pctl, +2.66 SD). She has thick curly hair with mild facial hirsutism (synophrys, hair on the upper lip). She has a short forehead with thick eyebrows. She has a Cupid's bow appearance to her upper lip with thick vermilion, retrognathia, and normal palate. Ears are normal. She has bilateral 5th finger clinodactyly and bilateral pes cavus. Neurological exam showed paucity of facial expression, but facial movement was preserved. Pupils were equal and reactive to light with full extraocular movements. Strength 4+/5 in all major muscle groups of upper and lower extremities. Tone grossly normal in upper limbs, perhaps slightly increased at the level of Achilles tendons in lower limbs. Gait is atypical as it is waddling but not wide-based; she was unable to perform tandem gait, but toe and heel walking were preserved. There was no truncal ataxia. Romberg was normal. Reflexes were preserved at the patellar, and Achilles tendons and Babinski was downgoing. A high amplitude, low-frequency tremor was noted both at rest and with movement. Bilateral finger to nose testing was impacted by tremor. There was a faded strawberry hemangioma with surrounding telangiectasia on the left flank.

She had a normal chromosomal SNP oligonucleotide microarray, FMR1/FMR2 analysis, plasma amino acids, urine organic acids, ammonia, and urine porphyrins.

Subject 21

The proband is a 2.5-year-old girl born to a G3P2>3 mother following a pregnancy notable for maternal treatment with lovonox for a history of prior deep vein thrombosis and acyclovir for a history of HSV. Delivery was vaginal at 28 and 1/7 weeks following the onset of preterm labor. Apgar scores were 8 and 9 at 1 and 5 minutes. Birth weight was 1,190 g (83rd pctl, +0.97 SD), and head circumference was 26 cm (70th pctl, +0.52 SD). The NICU course was fairly uncomplicated. She received CPAP support for 4 days and had normal screening head ultrasound.

She had a mild delay of milestones with walking at age 2 years and speech limited to single words, with an estimated 50-word vocabulary, at age 2.5 years, and she followed familiar commands. She had reduced eye contact and head-banging, and was diagnosed with autism spectrum disorder at 26 months of age.

On examination at age 2 years, she had relative microcephaly 45.6 cm (8th pctl, -1.36 SD) with height 83.8 cm (37th pctl, -0.34 SD) and weight 11.8 kg (40th pctl, -0.20 SD). She has down slanting palpebral fissures and slightly upturned nares. The exam was notable for mild hypotonia, and gait was abnormal with wide stance and arms in a flexed posture.

Echocardiogram showed a trivial VSD. Brain MRI, audiology evaluation, and CGH array were normal.

Subject 22

The subject is the only child of healthy unrelated parents. Family history is positive for dilated cardiomyopathy (paternal grandmother). Ultrasound examination of the heart in the father was unremarkable. Pregnancy was uneventful. The antenatal ultrasound evaluation did not show any congenital defects. Delivery was at term (39 weeks of gestational age) through cesarean section. Birth weight was 2,650 kg (9th pctl, -1.36 SD), length 47 cm (15th pctl, -1.02 SD), and head circumference 33.5 cm (37th pctl, -0.34 SD). APGAR score 9/10. At birth, a cardiac malformation consisting of two interatrial defects, and a complex upper limb anomaly with bilateral thumb agenesis, IV-V fingers syndactyly, with unique metacarpal bone, and bilateral short radius and ulna, with radio-humeral fusion at right elbow were detected. Her growth was normal (25th-50th centile for all parameters). The psychomotor development was considered normal. At last evaluation at the age of 3.7 years, with the WPPSI III scale disclosed a total IQ of 85, with a Verbal IQ of 92 and a performance IQ of 81. Visual and hearing problems have been excluded.

The child does not show gross facial dysmorphisms. She underwent surgical intervention in both hands. The right elbow has no mobility due to humero-radial synostosis, while the left elbow has limited mobility.

DEB test, CGH array, and *TBX5* gene analysis gave normal results.

Subject 23

The subject is a 14-year-old boy born after an uneventful pregnancy at 40 and 5/7 weeks with a birth weight of 4,500 g (>99th pctl, +2.84 SD). He had normal Apgar scores 9/10 and an uneventful neonatal period. His early development was normal, with normal developmental milestones. At the age of 3 years, he was noted to prefer to play on his own, and at the age of 6 years, he was officially diagnosed with autism spectrum disorder. He attended special school for children with behavioral problems. At the age of 14 years, his IQ was assessed as 67. He had normal hearing and eyesight and a normal eating and sleeping pattern. At the age of 14 years, he had a height of 178 cm (91st pctl, +1.32 SD, standard European growth chart), weight 59.5 kg (63th pctl, +0.34 SD, standard European growth chart), and head circumference of 56 cm (67th pctl, +0.43 SD, standard European growth chart). He had low-set eyebrows with deep-set eyes and periorbital fullness, broad nasal base with full nasal tip, normal formed palate. He had a flat thorax.

Subject 24

The subject, a female, presented with motor delay (sitting ability at 1y 6m, walking ability 2y 4m, not able to climb or run, difficulties in writing, physiotherapy and occupational therapy), autism spectrum disorder, wide-based gait, fatigue (requiring wheelchair use for longer distances) and incongruent IQ results (verbal IQ 81, performance IQ 72 at age 8y; verbal IQ 124, performance IQ 81 at age 5y). Brain MRI showed an arachnoid cyst in the left temporal lobe. Other symptoms include bronchial hyperreactivity, mild hypermetropia and astigmatism. No further problems in medical history. She was born after an uncomplicated pregnancy, by induced uncomplicated delivery at 42 weeks. Apgar scores were 9/10 after 1/5 minutes.

Physical examination showed normal growth, no facial dysmorphism, no thoracic abnormalities, abdominal fat disposition, normal vertebral column, hypermobility with Beighton score 9/9, no skin abnormalities.

Mitochondrial and metabolic workup did not lead to a diagnosis.

Subject 25

The proband, a male, presented with behavioral problems (concerns for autism spectrum disorder), developmental delay, and tall stature (+2.3 SD) with normocephaly. He was born to non-consanguineous parents, and has a healthy 5-year-old sister. During pregnancy, the mother had influenza or upper airway infection requiring antibiotics inducing premature contractions at 26 weeks. Vaginal delivery at 39+3 weeks was complicated by fetal distress. Birth weight was 3,800 g (88th pctl, +1.18 SD, standard European growth chart). No congenital abnormality was revealed. The neonatal period was characterized by unreasonable crying. Development was delayed, with impaired social interactions (poor eye contact), delayed speech and language skills (non-verbal, slight understanding of spoken language, communication via simple gestures such as pointing), and very selective eating (only specific baby food or porridge). Gross motor skills were normal, but walking was slightly uncoordinated. Epilepsy has not been documented, while mild sleep disturbances (awakes often) have been reported. He is easily fatigued and pale but not very prone to infections. He has a normal hearing ability and moderate hypermetropia (+3.00 Dpt). He uses macrogol for constipation.

A physical examination was performed via video; no evident facial dysmorphism was appreciated.

SNP-array and FMR1-gene analysis were both normal.

Subject 26

The proband is a 27-year-old male offspring of non-consanguineous parents of white British origin. He was born at 38 weeks of gestation by normal vaginal delivery following an uneventful pregnancy. At birth his weight was 2,690 g (11th pctl, -1.25 SD) and occipitofrontal circumference (OFC) was 34.5 cm (60th pctl, +0.26 SD). He struggled to regain birth weight due to poor feeding but did not require any intervention. He was noted to be hypotonic and had neonatal stridor.

He started sitting independently at 9 months and walked at 17 months but has always been described as clumsy, particularly with fine motor tasks. He had a significant speech delay, with a vocabulary of 4-5 words at 5 years of age. His hearing is normal as well as the ophthalmic examination, arranged due to suspicion of Cohen syndrome. He had vacant episodes as a child, but an EEG showed no abnormality and no treatment was required. He is overly sociable and prone to aggressive outbursts. His behavior is quite repetitive. He has been diagnosed with Attention Deficit Hyperactivity Disorder. He had a trial of methylphenidate which was discontinued due to side effects. He has struggled with making friendships as well as in busy scenarios. He has been diagnosed with Autism Spectrum Disorder.

At 5 years of age, the proband had difficulties with constipation and soiling that was treated with sodium picosulphate. A rectal biopsy was normal. He had a small ventricular septal defect, which did not require surgical management. He had an inguinal hernia, which was repaired surgically. He suffered with secondary enuresis at the age of 11 years, and was prescribed desmopressin tablets.

At 20 years, his weight was 82 kg (83rd pctl, +0.97 SD), height 175 cm (42nd pctl, -0.21 SD), and OFC 54 cm (4th pctl, -1.78 SD). He has coarse facial features with heavy eyebrows and long eyelashes. He has prominent maxilla and protruding central incisors with a high arched palate. He has a bulbous nasal tip and prominent nasal root with narrow palpebral fissures. He has slender tapered fingers. Examination of his lower limbs revealed bilateral pes cavus and tight Achilles tendons with very brisk reflexes and clonus. He also has thoracic kyphosis.

A full blood count and serum biochemistry were all within normal limits. There were no documented episodes of granulocytopenia. At the age of 14 years, the proband underwent an electroretinogram (ERG) examination. Although there was poor cooperation, there was some suggestion that responses were attenuated. He has been under follow-up with yearly ERGs, which have remained stable. He still has no problems with his eyesight, and fundal examination remains unremarkable.

Standard karyotype, fragile X screening, fluorescent in-situ hybridization for Smith-Magenis syndrome, chromosomal microarray (Affymetrix SNP6.0 Array, minimum resolution 50kb), and urine mucopolysaccharides were all reported to be normal. A retinal dystrophy panel including 176 genes did not identify any pathogenic mutations. He was recruited to the Deciphering Developmental Disorders (DDD) study for whole exome sequencing. This did not reveal any pathogenic mutations.

Subject 27

The proband is an 18-year-old male offspring of non-consanguineous parents of white British origin with no relevant family history. He was born at 42 weeks of gestation via an induced delivery after an uncomplicated pregnancy. His birth weight was 3,260 g (21st pctl, -0.81 SD). Length and birth OFC were not recorded. The neonatal period was unremarkable, apart from hypothermia for the first two days of life.

He smiled at 8 weeks, sat and rolled at 12 months, crawled at 13 months, and walked independently at 17 months. At the age of 2 years 8 months, he was using single words only. At the age of 28 months, Griffith's Developmental Assessment revealed a general IQ of 59 with a developmental age of 16.5 months. Hearing test demonstrated Eustachian tube dysfunction; however, he has not required hearing aids or intervention. His eyesight is

normal. He has not been reported to have seizures. He demonstrates aggressive outbursts and occasionally self-injurious behaviour being inclined to bang his head on the floor and pull his hair.

At the clinical evaluation at 2 years 8 months, his weight was 15.46 kg (84th pctl, 1.03 SD), and OFC was 45.8 cm (1st pctl, -2.23 SD). At the age of 10 years 10 months, his weight was 46.1 kg (89th pctl, 1.25 SD), height was 147.1 cm (73th pctl, 0.63 SD), and OFC 50.5 cm (<3rd pctl, -2.34 SD). He has marked brachycephaly, epicanthal folds, arched eyebrows with synophrys, upturned nasal tip, very long eyelashes, a large mouth with a short upturned philtrum, and creased lips. He has short transverse palmar creases with incurving of his 4th and 5th toes bilaterally. Systemic examination has been unremarkable other than brisk lower limb reflexes.

Urine amino acids and organic acids, urea and electrolytes, full blood count, liver and thyroid function were all within normal limits.

A standard karyotype was normal including FISH for Smith-Magenis syndrome. 7-dehydrocholesterol and creatine kinase levels were normal. Microarray analysis (OGT 8x60k with CytoSure Interpret v3.4.3, average resolution 180kb) showed no significant copy number variants. Fragile X screening by PCR showed less than 45 repeats hence within the normal range. He was recruited to the DDD study where WES identified a missense variant in *MYH3* (p.Arg799Ser), which was felt to be benign as he did not display any features of arthrogyriposis (MIM: 139700).

Subject 28

The proband, a female, was born at 39 weeks gestation via vacuum-assisted vaginal delivery following an uncomplicated pregnancy. She is the product of a non-consanguineous union between a 27-year-old mother and a 37-year-old father, both of Norwegian and German ancestry. The immediate neonatal period was unremarkable.

She was globally delayed, and it became apparent around 12 to 18 months of age. Early motor milestones were met on time (rolling over at 3 months of age, sitting unsupported at 6 months of age, and crawling at 11 months, walking at 17.5 months). Early language and social milestones were also met on time (first social smiles at 3 months of age, first babbling at 4-6 months of age, and first words at 10-12 months of age). However, her language development was delayed. Behaviorally, as a child, she had an overall happy demeanor and is noted to talk to herself. No stereotypical behavior, repetitive movements, or self-injurious behavior were seen. Throughout early childhood, she received supportive therapies including speech therapy, occupational therapy, and physical therapy, as well as a developmental program. At 9.5 years, she was evaluated with the Wechsler-IV Scale and found to have a full-scale IQ of 68. Ultimately, she was diagnosed with autism spectrum disorder. Additionally, she had precocious puberty starting at 9 years of age. Clinical evaluation at 13 years revealed an OFC of 53 cm (32nd percentile, -0.47 SD), weight of 46.7 kg (54th pctl, +0.10 SD), and a height of 169.5 cm (96th pctl, +1.80 SD). Craniofacial features showed mild dolichocephaly with a long and narrow face, prominent eyebrows with partial synophrys, mildly down-slanting palpebral fissures, long nose, broad mouth, prominent maxillary incisors, high arched and narrow palate, and bilateral small ear pits at the base of the antihelix. The tongue showed mild fasciculations. The musculoskeletal exam revealed long slender limbs with mild to moderate hypermobility in the moderate sized joints. Exam

of the back revealed significant kyphosis without scoliosis. The neurologic exam was notable for significant motor restlessness and tremulousness without clear choreoathetosis or myotonic jerks. Generalized hypotonia was also noted, axial more so than appendicular. Her coordinated was noted to be abnormal with mild finger ataxia, dysdiadochokinesis with alternating hand movements, and slowed rapid finger movements. The subject giggled frequently throughout the exam and tactile hypersensitivity was noted. Clinical evaluation at 14 years of age was prompted by her mother's concern for worsened tremulousness which interfered with her daily activities and required weights to help with handwriting at school. Of note, she had recently been sedated with Propofol and Ketamine for a dental procedure with continued involuntary movements despite sedation. The physical exam at that time revealed an OFC of 55 cm (79th pctl, +0.81 SD), a weight of 57.3 kg (73rd pctl, +0.62 SD), and a height of 172 cm (96th pctl, +1.76 SD). Previously noted craniofacial features were unchanged. Mild hirsutism was noted to the bilateral forearms, and a single café-au-lait macule to the left back. Additionally, the central incisors appeared to be less prominent. The neurologic exam revealed worsened tremulousness, and atypical involuntary movements were noted throughout the exam. These were described as episodic hyperkinetic movements triggered by spontaneous activity and often extended to other areas of her body, perhaps representing muscular hyperexcitability. The deep tendon reflexes were 2+ bilaterally throughout the upper and lower extremities. In particular, the patellar reflex showed secondary generalization of the reflex response. Her gait was described as unsteady.

Clinical evaluation at 18 years of age was prompted by concern for an evolving connective tissue phenotype. Of note, the previously concerning tremulousness and atypical involuntary movements had improved considerably by report and appeared quite improved by observation only. Since her visit 4 years prior, she had started Sertraline. Anthropometric parameters could not be obtained. Beyond the improvement of her neurologic features, her phenotype was relatively unchanged with the exception of her dermatologic presentation. Based on pictures submitted by her mother, she was noted to have diffuse, short, vertical, reddish purple striae over her posterior calves, thighs, and reportedly over her buttocks and low back. Skin hyperextensibility or translucency was not seen.

Prior genetic testing included karyotyping, which showed a 46,XX complement, and chromosomal microarray, fragile X testing, and methylation analysis for Angelman Syndrome, which provided normal results. A first trio-based WES analysis was also normal. Additionally, she had an MRI of the brain at age of 5 years, which showed "mild blush consistent with mild periventricular leukoencephalopathy not suggestive of periventricular or germinal matrix hemorrhage". Sleep study, ophthalmologic and hearing evaluations, EKG, and ECG were not informative. Past metabolic screening labs, including ESR, CPK, CMP, acylcarnitine, and free and total carnitine profiles were normal.

Subject 29

The proband, a 24 year-old male, is the third child of non-consanguineous American parents. Family history is unremarkable. Pregnancy was complicated by prenatal diagnosis of cystic hygroma. Amniocentesis was performed and chromosome analysis returned a normal chromosome complement (46,XY). He was delivered full term via emergent cesarean delivery due to fetal distress. Birth weight was 2,750 g (4th pctl, -1.81 SD) and length was approximately 50 cm (~34th pctl, -0.4 SD). Neonatal period was complicated by diagnosis of hypoplastic left heart syndrome and subsequent heart transplant at 13 days of life. He

required mechanical ventilation for 7 weeks following transplant. Perinatal period was complicated by hypotonia and feeding/swallowing difficulties. Brain MRI revealed hypoxic damage. He has a history of global developmental delays (walking independently around 26 months) and intellectual disability. Mother reports IQ testing many years ago revealed an IQ in the 70s. Exact number and scale used were not available.

Additional clinical history includes bilateral sensorineural hearing loss treated with a bone anchored hearing aid. He has myopia and wears glasses. He has a history of frequent recurrent infections and renal failure secondary to antirejection medications following heart transplant. He underwent kidney transplant at 17ys.

Prior work-up in the proband included 22q11.2 FISH analysis, Noonan panel (2007, number of genes unknown), telomere analysis, and BAC array. Results of this testing were all normal. At age 23ys, he was noted to have a long face with high anterior hairline, bitemporal narrowing and frontal bossing, small palpebral fissures, uplifted and large earlobes, bulbous nose with prominent nasal tip, thick vermilion border and a long philtrum, and pointed chin. He has undergone dental rehabilitation and previously had a history of gingival disease and overcrowded teeth. He was noted to have a high arched palate.

Array CGH using 4x180 oligo+SNP platform and exome sequencing were non-diagnostic.

Subject 30

The proband, a male, is the second child of healthy non-consanguineous parents of mixed European descent. Family history was unremarkable. He was born after induction at 36 weeks of pregnancy due to pre-eclampsia symptoms. Birth weight was 2,700 g (2-5th pctl, -1.4 SD), and Apgar scores of 9/9. Length, and OFC were not available. Perinatal period was complicated by difficulties with latching and regaining birth weight. Failure to thrive persisted until approximately 18 months. Developmental milestones were delayed, and he was referred for evaluation due to low tone and limited gain of milestones at 7 months. Ultimately, he walked alone at approximately 16 months, although at 26 months, his gait remains unsteady, and he continues to fall easily. At 26 months, he has 20+ words and is using rare two-word sentences with significant jargon. There are no concerns for regression. At approximately the time at which developmental delays were identified, microcephaly was noted, and evaluation by neurology and genetics was pursued.

Clinical evaluation at 26 months, via telehealth assessment, identified a normal general examination with microcephaly and without significant dysmorphisms. A neurologic telehealth examination was remarkable for single word utterances with significant jargon and mild truncal hypotonia. Gait was fluent, deep tendon reflexes were normal, and plantar responses were down-going. Fine-motor control in picking up small objects demonstrates a normal pincer grasp. At the last evaluation, his height was 88 cm (43rd pctl, -0.15 SD), weight 12.8 kg (43rd pctl, -0.10 SD) and OFC 46.2 cm (3rd pctl, -2 SD).

Brain MRI revealed some multifocal white matter abnormalities with enlarged perivascular spaces. Creatinine kinase, lactate, pyruvate, carnitine, ammonia, amino acids, acylcarnitines, and newborn screening results were unremarkable.

Subject 31

The proband, a boy, is the first child of healthy non-consanguineous Bosnian parents. Family history was unremarkable. After an uneventful pregnancy, he was born at term of gestation. Birth weight was 3,400 g (43rd pctl, -0.18 SD), length 51 cm (58th pctl, +0.2 SD). OFC and Apgar scores are not available. He presented with a delay in motor milestones acquisition (sitting at 9 months, walking at 14 months). Expressive language was delayed and impaired. He presented gross and fine motor delay. At the age of 16, he moved from Bosnia to Italy, and one year later, he was scored using the non-verbal Raven scale with an average IQ of 62.

Phenotypic evaluation at 20 years disclosed high anterior hairline, arched eyebrows, synophrys, enlarged earlobes, thick vermilion, and long philtrum.

At 10 years, he developed kyphoscoliosis, and a 1.5 cm leg-length discrepancy was observed. At 13 years, he was diagnosed with hypothyroidism with normal thyroid morphology at ultrasound examination. At the last evaluation, the height was 170 cm (18th pctl, -0.9 SD), weight 72 kg (55th pctl, +0.11 SD), and OFC 54 cm (4th pctl, -1.78 SD).

At 10 months, he developed seizures with head drop in cluster which was controlled with valproic acid. The antiepileptic drug therapy was maintained. The EEG at the age of 18 years showed a normal organization and focal epileptic paroxysm in the right frontal area in wakefulness and sleep. To exclude morphological abnormalities in the brain structure, MRI was performed, which revealed a normal structure. Echocardiography was normal. SNPs array revealed a duplication of 13q22.2-q22.3 inherited from unaffected mother.

Subject 32

The proband, a boy, is the first child of healthy non-consanguineous Italian parents. Family history was unremarkable. During the pregnancy choroid plexus cysts and a nasal bone hypoplasia were detected. He was born at 41st gestational weeks with a birth weight of 3,520 g (56th pctl, +0.14 SD), and length of 52 cm (58th pctl, +0.2 SD). OFC and Apgar scores were not available. He presented with microcephaly at 6 months, and delayed motor milestones acquisition (sitting at 8 months, walking at 18 months). Expressive language was delayed and impaired. He presented with gross and fine motor delay. He also showed dysphagia and chronic constipation. Psychomotor evaluation detected moderate intellectual disability. Brain MRI disclosed parietal and occipital cortical atrophy while echocardiography and abdominal ultrasound were normal. The EEG disclosed non-specific pattern abnormalities, and the hand and wrist X-ray showed an advanced bone age (1.5 y).

Phenotypic evaluation at 5 years and 3 months presented with low frontal hairline, arched eyebrows, mild epicanthus, bulbous nose, thick vermilion, high palate, and pointed chin. At the last evaluation, weight was 20 kg (35th pctl, -0.4 SD), height was 116.4 cm (39th pctl, -0.29 SD), and head circumference 48 cm (<3rd pctl, -2.8 SD).

SNPs array analysis and a NGS panel for Angelman-like syndromes were normal.

Subject 33

The subject is a 6-year-old multiracial non-Hispanic female. She was born vaginally at 38 weeks. Vaginal bleeding (spotting) of two-day duration was reported during the second trimester; no other pregnancy complications were reported. Labor was induced with Pitocin

due to failure to progress. Her head circumference at birth was reportedly smaller than average. Birth weight was 3,005 g (21st pctl, -0.8 SD), and birth length was 53 cm (98th pctl, +2.03 SD). At birth, she presented with hyperbilirubinemia, which was not treated. As an infant, she was described as irritable/inconsolable/colicky. At last measurement, her height was in the above average range (128 cm; 92nd pctl, +1.41 SD), and weight was in the well above average range (40 kg; >97th pctl, +3.27 SD). Head circumference was in the average range (51 cm; 34th pctl, -0.42 SD).

She was diagnosed with autism spectrum disorder (confirmed with ADOS, ADI, and clinical judgment using DSM-IV criteria). She uses complex speech with recurrent grammatical errors. The subject shows autism-related impairments in social communication, including minimal sharing or requesting of information, difficulty reporting past events, poor eye contact, limited understanding of emotions and relationships, and reduced frequency and quality of social overtures and responses. Some repetitive behaviors were noted, including stereotyped speech, unusual sensory interests, sensory sensitivities, and complex mannerisms.

Her cognitive abilities are in the average to above average range as measured with the Differential Abilities Scale-II (Verbal IQ = 99, Nonverbal IQ = 119, Full-Scale IQ = 101). Her adaptive abilities fall in the moderately low range as measured with the Vineland-II (Adaptive Composite = 72), and her receptive language skills fall in the low average range as measured with the Peabody Picture Vocabulary test (Standard Score = 87). Proband's parent endorses significant externalizing behavior problems (aggressive behavior, conduct problems, and oppositional defiant problems) and internalizing behavior problems (anxiety problems, mood problems, somatic complaints, and thought problems).

Abnormalities were first noted in her behavior at 28 months of age. She first walked independently at 36 months of age. She first used single words at 8 months of age and first used phrases at 11 months; however, significant regression in language, motor, and social communication skills was reported at age 28 months.

She has a history of gastrointestinal problems, including chronic gastroesophageal reflux disorder (GERD), chronic constipation, problematic diarrhea, bloody stools, and vomiting. She also has a history of corrected vision problems and motor coordination problems. Respiratory problems were suspected but have not been diagnosed. She has no reported history of seizures, neurological problems, or sleep problems. She has been prescribed a mood-stabilizing medication and was previously prescribed a stimulant medication. The proband's father has a history of speech delay and stuttering.

Subject 34

The proband is a 13-year-old male. At last measurement, his height was in the well above average range (179 cm; >97th pctl, +3.09 SD), his weight was in the above average range (72.6 kg; >97th pctl, +2.18 SD), and his head circumference was in the average range (54.6 cm; 48th pctl, -0.05 SD). He was diagnosed with autism spectrum disorder (confirmed with ADOS, ADI, and clinical judgment using DSM-IV criteria) and met criteria for intellectual disability (confirmed with cognitive and adaptive testing). He primarily speaks in phrases. He shows autism-related impairments in social communication, including difficulty sharing and asking for information, limited reciprocal conversation, poor eye contact, inappropriate social overtures, and difficulty engaging in reciprocal interactions. Restricted and repetitive

behaviors were noted, including difficulty tolerating change, restricted interests, and sensory sensitivities.

His cognitive abilities fall in the very low range as measured with the Wechsler Intelligence Scale for Children-IV (Verbal IQ = 73, Nonverbal IQ = 66, Full-Scale IQ = 63), and his adaptive abilities also fall in the very low range as measured with the Vineland-II (Adaptive Composite = 62). He had a speech delay; first used single words at 48 months of age, and first phrases at 72 months. Abnormalities were first noted in his development at 12 months of age. He first walked independently at 18 months. Regression was denied. A history of self-injurious behavior and aggression was reported.

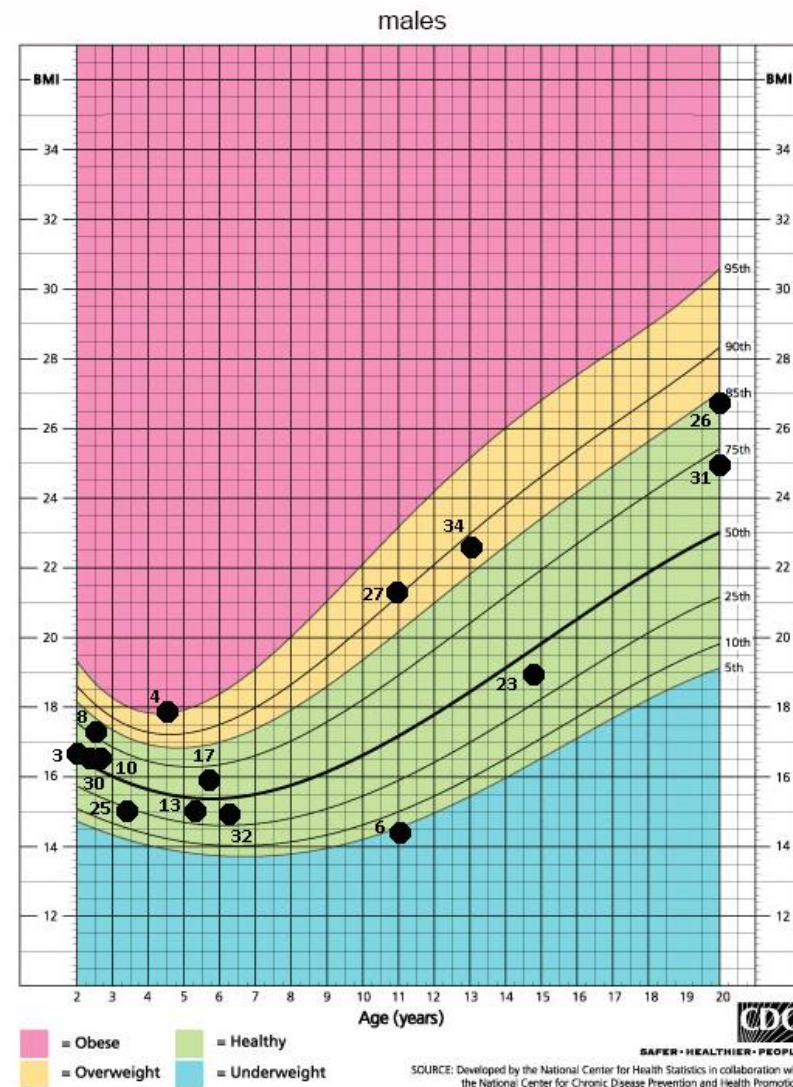
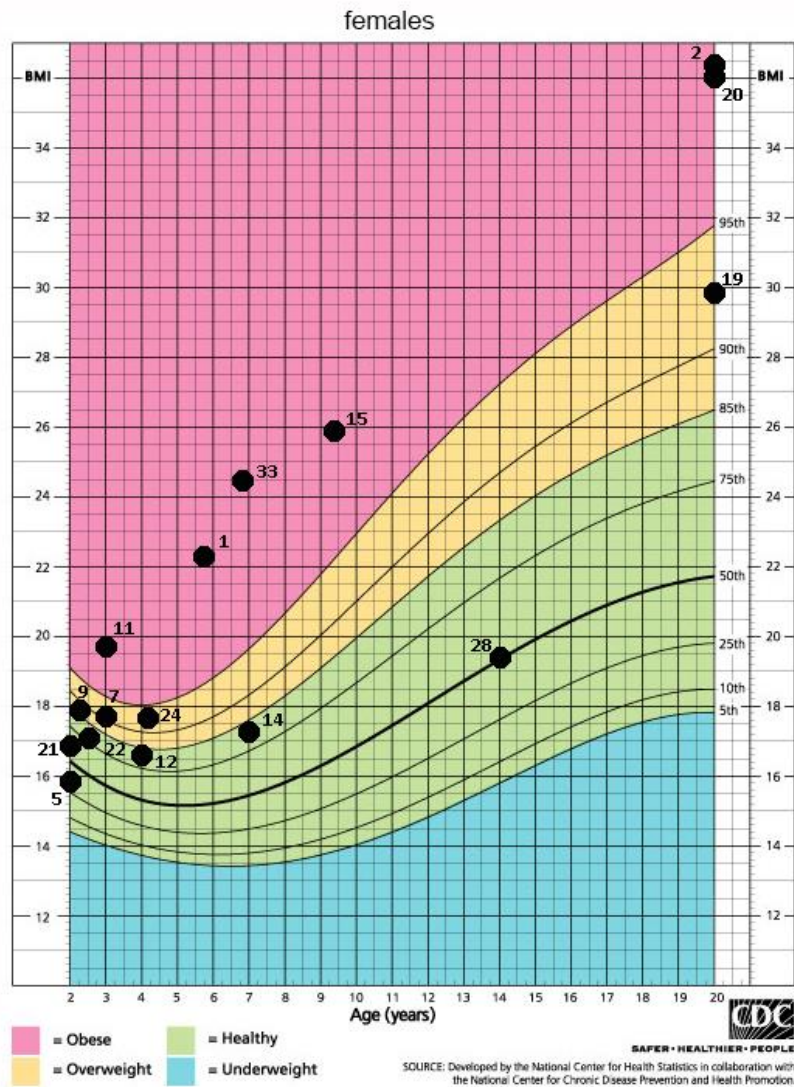


Figure S1. BMI charts/BMI distribution within the cohort. BMI values are plotted on the 2000 CDC growth charts (Kuczmarski et al. 2002).

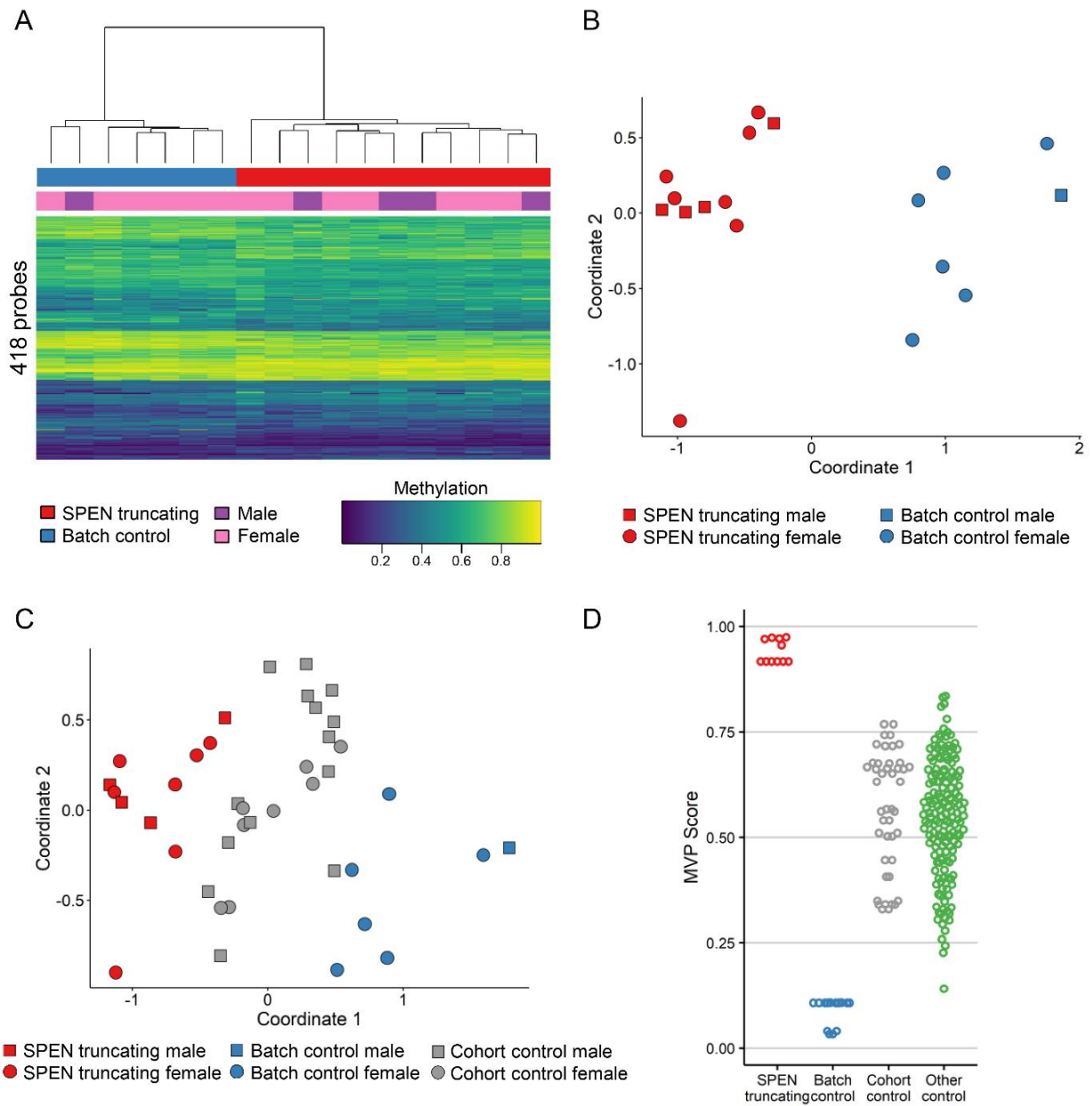


Figure S2. Episignature detection in subjects with *SPEN* truncating mutations. Samples from male and female individuals were compared to samples from healthy controls processed alongside the *SPEN* mutated samples (batch controls) and CpGs on all autosomes were analyzed. The identified probe set was able to separate *SPEN* mutated samples from controls as shown by hierarchical clustering (**A**) and multidimensional scaling (**B**). Multidimensional scaling analysis (**C**) and support vector machine-based methylation variant pathogenicity (MVP) scores (**D**) show that when the episignature was applied to additional controls either processed in the same lab (cohort controls) or in other labs (other controls), they do not cluster or score with the batch controls used for training.

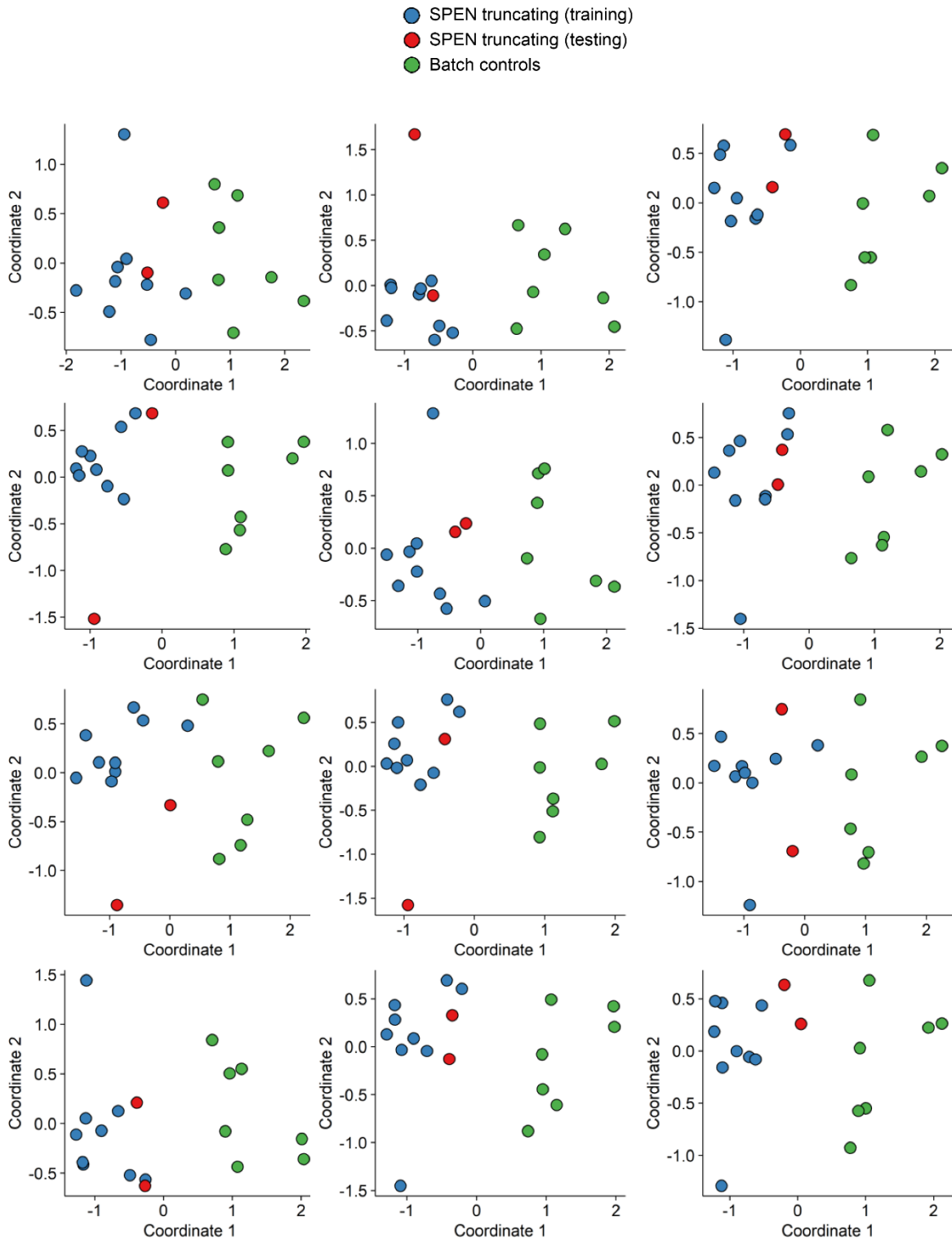


Figure S3: Leave-2-out cross validation of the male and female samples plotted using the autosome episignature. For each round of validation, nine of the eleven samples with *SPEN* truncating mutations were used for probe selection along with the batch control samples and two *SPEN* mutated samples were saved for testing. Multidimensional scaling was used to cluster the samples. Each time the two testing samples clustered with the other samples with *SPEN* mutations. This was repeated for each combination of *SPEN* mutated samples (55 times), the first 12 are shown here.

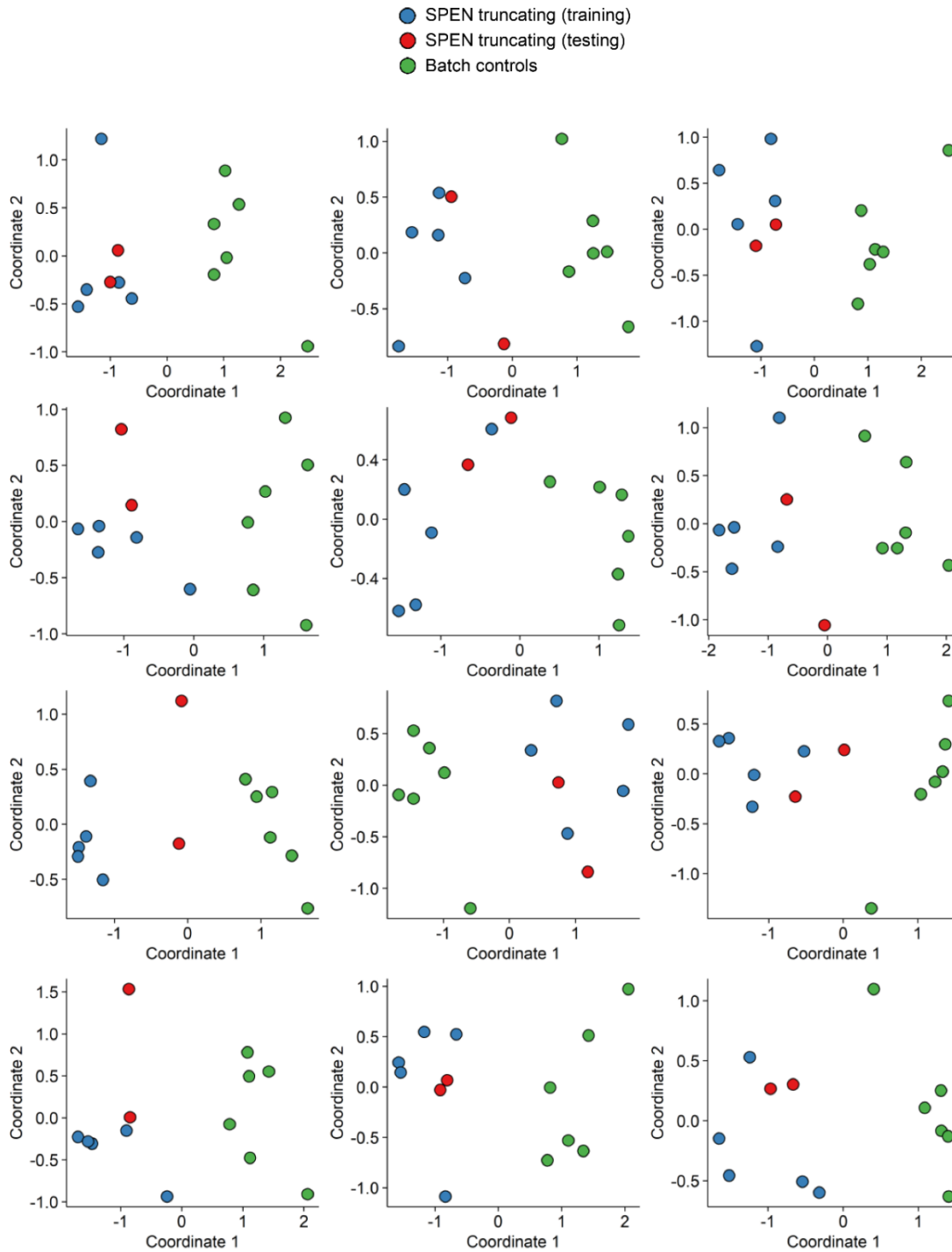


Figure S4: Leave-2-out cross validation of female samples plotted using the X chromosome epigenature. For each round of validation, five of the seven females with *SPEN* truncating mutations were used for probe selection along with the female batch control samples and two females with truncating *SPEN* mutations were saved for testing. Multidimensional scaling was used to cluster the samples. Each time the two testing samples clustered with the other *SPEN* mutated samples. This was repeated for each combination of *SPEN* mutated samples (21 times), the first 12 are shown here.

METHODS

Methylation analysis

Peripheral blood DNA from a cohort of subjects with truncating *SPEN* variants was extracted using standard techniques. The cohort consisted of 11 individuals with *SPEN* truncating mutations (7 females, 4 males), 7 healthy “batch” controls processed with the samples with *SPEN* truncating variants (6 females, 1 males), and 22 “cohort” controls (7 females, 15 males) processed separately.

500 ng of DNA was used as input material from peripheral blood samples. After treatment with bisulfite, each sample was whole-genome amplified (WGA) and enzymatically fragmented. The bisulfite-converted WGA-DNA samples were purified and applied to Illumina Infinium Human Methylation EPIC BeadChip (EPIC) arrays. Methylated and unmethylated allele-specific primer annealing was followed by single-base extension using DNP- and biotin-labeled ddNTPs. After extension, the array was fluorescently stained and scanned (Illumina iScan microarray platform).

Data analysis was performed essentially as previously described (Aref-Eshghi et al. 2019, 2020) and is summarized here. IDAT files containing methylated and unmethylated signal intensity were imported into R 3.6.2 for analysis. Normalization was performed using the Illumina normalization method with background correction using the minfi package (Aryee et al. 2014). Probes with detection p-value >0.01 , which contained SNPs at the CpG interrogation or single nucleotide extension sites, which are known to cross-react with other genomic locations, had methylation levels of 0, or (except for X chromosome-specific analysis) located on the X and Y chromosomes, were removed. Methylation levels (beta values) were logit transformed and the transformed values used for linear regression modeling using the limma package (Ritchie et al. 2015), estimated blood cell proportions (Houseman et al. 2012) were added to the model matrix as confounding variables. To identify the most informative probes we used the interaction between the effect size and p value: the absolute mean methylation difference between *SPEN* and batch controls was multiplied by the negative log of the p value and the top 1000 probes were selected. Receiver’s operating curve characteristic analysis was performed to identify the top 500 of these 1000 probes, then probes with a pairwise correlation >0.9 were removed. Hierarchical clustering was performed using the gplots package. Multidimensional scaling (MDS) was performed by scaling of the pair-wise Euclidean distances between samples. The e1071 R package was used to train a support vector machine (SVM) and for construction of a prediction model to calculate what we refer to as methylation variant pathogenicity (MVP) scores.

Transcriptome analysis

To understand the developmental expression trajectory of *SPEN* in the human brain, developing human brain RNA-Seq data were downloaded from the BrainSpan database (<http://www.brainspan.org>) (Kang et al., 2011). The RNA-Seq data were summarized to GENCODE 10 gene-level reads per kilobase of transcript, per million mapped reads (RPKM) values (Harrow et al., 2006). This dataset covers 16 brain regions, including 11 neocortex areas, and spans developmental periods from the 8th post-conceptual week to the 40th postnatal year. Only those samples from neocortical regions that have RNA integrity numbers ≥ 8 were used for analysis. The gene-level RPKM expression values were further

transformed to \log_2 (RPKM+1) values. To explore the temporal expression pattern of *SPEN* in the cortex, the samples from the same developmental time point were grouped together and the expression values across those grouped samples were averaged. Genes with expression level ≥ 1 in at least 50% of the ungrouped cortical samples were defined as genes expressed in human cortex.

The neurodevelopmental disorder (NDD) gene set includes 159 genes with at least three *de novo* loss-of-function mutations (nonsense, frameshift, and canonical splice-site mutations) in distinct individuals with NDDs (including autism spectrum disorder, epilepsy, intellectual disability, and developmental delay) and no *de novo* loss-of-function mutation in controls from the denovo-db v.1.6.1 database (Turner et al. 2017) and nonredundant *de novo* mutation data (Satterstrom et al. 2020).

To calculate the correlation with NDD genes in the ungrouped cortical samples, genes expressed in human cortex were used as background genes. For any NDD gene in the background gene set, the correlation with NDD genes for the gene was defined as the average Spearman's correlation coefficients between the gene and the other NDD genes. For any non-NDD gene in the background gene set, the correlation with NDD genes for the gene was defined as the average Spearman's correlation coefficients between the gene and NDD genes. Based on the correlation with NDD genes for any background gene, we obtained the distribution of correlations with NDD genes for all the background genes and calculated the percentile of the correlation with NDD genes for *SPEN*.

Human fetal prefrontal cortical single-cell RNA sequencing data (Zhong et al. 2018) were downloaded from the NCBI Gene Expression Omnibus under the accession number GSE104276. Detailed processing was described previously (Pang et al. 2020). A similar analysis was performed to calculate the correlation with NDD genes in the vRG-to-IPC transition at gestational week 10 using genes expressed in neural progenitor cells as background genes. To calculate the combined rank of a gene within 1p36 region, the two ranks of Spearman's correlation in the two conditions were averaged and ranked.

REFERENCES

- Aref-Eshghi, E., Bend, E.G., Colaiacovo, S., Caudle, M., Chakrabarti, R., Napier, M., Brick, L., Brady, L., Carere, D.A., Levy, M.A., et al. (2019). Diagnostic Utility of Genome-wide DNA Methylation Testing in Genetically Unsolved Individuals with Suspected Hereditary Conditions. *American journal of human genetics*. 104, 685–700.
- Aref-Eshghi, E.J., Kerkhof, V.P., Pedro, D.I.F., Groupe, M., Barat-Houari, N., Ruiz-Pallares, J.C., Andrau, D., Lacombe, J., Van-Gils, P., Fergelot, C., et al. (2020). Evaluation of DNA Methylation Episignatures for Diagnosis and Phenotype Correlations in 42 Mendelian Neurodevelopmental Disorders. *Am. J. Hum. Genet.* 106, 356-370.
- Aryee, M.J., Jaffe, A.E., Corrada-Bravo, H., Ladd-Acosta, C., Feinberg, A.P., Hansen, K.D., Irizarry, R.A. (2014) Minfi: a flexible and comprehensive Bioconductor package for the analysis of Infinium DNA methylation microarrays. *Bioinformatics*. 30, 1363-1369.
- Harrow, J., Denoeud, F., Frankish, A., Reymond, A., Chen, C.K., Chrast, J., Lagarde, J., Gilbert, J.G., Storey, R., Swarbreck, D., et al. (2006) GENCODE: producing a reference annotation for ENCODE. *Genome Biol.* 7 Suppl 1, S4.1-9.
- Houseman, E.A., Accomando, W.P., Koestler, D.C., Christensen, B.C., Marsit, C.J., Nelson, H.H., Wiencke, J.K., Kelsey, K.T. (2012) DNA methylation arrays as surrogate measures of cell mixture distribution. *BMC Bioinformatics*. 13, 86.
- Kang, H.J., Kawasawa, Y.I., Cheng, F., Zhu, Y., Xu, X., Li, M., Sousa, A.M., Pletikos, M., Meyer, K.A., Sedmak, G., et al. (2011) Spatio-temporal transcriptome of the human brain. *Nature*. 478, 483-489.
- Kuczumski, R.J., Ogden, C.L., Guo, S.S., Grummer-Strawn, L.M., Flegal, K.M., Mei, Z., Wei, R., Curtin, L.R., Roche, A.F., Johnson, C.L. (2002) 2000 CDC Growth Charts for the United States: methods and development. *Vital Health Stat* 11. 246, 1-190.
- Pang, K., Wang, L., Wang, W., Zhou, J., Cheng, C., Han, K., Zoghbi, H.Y., Liu, Z. (2020) Coexpression enrichment analysis at the single-cell level reveals convergent defects in neural progenitor cells and their cell-type transitions in neurodevelopmental disorders. *Genome Res*. 30, 835-848.
- Ritchie, M.E., Phipson, B., Wu, D., Hu, Y., Law, C.W., Shi, W., Smyth, G.K. (2015) limma powers differential expression analyses for RNA-sequencing and microarray studies. *Nucleic Acids Res*. 43, e47.
- Satterstrom, F.K., Kosmicki, J.A., Wang, J., Breen, M.S., De Rubeis, S., An, J.Y., Peng, M., Collins, R., Grove, J., Klei, L., et al. (2020) Large-Scale Exome Sequencing Study Implicates Both Developmental and Functional Changes in the Neurobiology of Autism. *Cell*. 180, 568-584.
- Turner, T.N., Yi, Q., Krumm, N., Huddleston, J., Hoekzema, K., Stessman, H.A.F., Doebley, A.-L., Bernier, R.A., Nickerson, D.A., Eichler, E.E. (2017) denovo-db: a compendium of human de novo variants. *Nucleic Acids Res*. 45, D804-D811.
- Zhong, S., Zhang, S., Fan, X., Wu, Q., Yan, L., Dong, J., Zhang, H., Li, L., Sun, L., Pan, N., et al. (2018) A single-cell RNA-seq survey of the developmental landscape of the human prefrontal cortex. *Nature*. 555, 524-528.