

SUPPORTING INFORMATION

This supplementary material contains:

- Search string replicable in PubMed
 - Table 1. Excluded studies with respective reason.
 - Table 2. Risk of bias assessment
 - Table 3. Sensitivity analysis
 - Table 4. Laboratory findings of included cases
 - Figure 1. Funnel plots for studies addressing cerebral venous thrombosis among patients hospitalized with SARS-CoV-2 (A) and among patients hospitalized with SARS-CoV-2 infection and referred with a cerebrovascular event (B)
 - References for supplementary material
-

Search String for PubMed:

("COVID"[All Fields] OR "coronavirus"[All Fields] OR "SARS-Cov-2"[All Fields] OR "coronavirus" [MeSH Terms]) AND ("sinus thrombosis, intracranial"[MeSH Terms] OR "cerebral venous thrombosis"[All Fields] OR "cerebral venous thrombosis" [All Fields] OR "cranial sinus thrombosis" [All Fields]).

Search was limited to humans, 1st January 2020 – 1st September 2020.

Supplementary material Table 1. Excluded studies with respective reason.

Author	Year	Reason for exclusion/details
Benger ¹	2020	no CVT reported, only intraparenchymal hemorrhage, normal CT angiography in all cases
Bhatia ²	2020	no original data
Cheruiyot ³	2020	review on arterial thrombosis
Chougar ⁴	2020	no original data on CVT (only 1 case already published)
Divani ⁵	2020	review, no CVT reported
Elnahry ⁶	2020	no original data
Etkin ⁷	2020	no CVT reported
Fara ⁸	2020	no CVT reported
Fatima ⁹	2020	no original data
Favas ¹⁰	2020	review, no original data
Jiménez-Ruiz ¹¹	2020	no original data
Kadono ¹²	2020	CVT and epilepsy presented 6 months before COVID
Klein ¹³	2020	no original data
Klok ¹⁴	2020	no CVT reported, study of incidence of thrombotic complications in severe COVID infection
Klok ¹⁵	2020	no CVT reported
Koralnik ¹⁶	2020	review, no original data
Kow ¹⁷	2020	no original data
Kremer ¹⁸	2020	venous thrombosis is an exclusion criteria, only non-vascular lesions
Kulick-Soper ¹⁹	2020	case report on hypoxic-ischemic brain injury
Li ²⁰	2020	no CVT reported
Lodigiani ²¹	2020	no CVT reported, only DVT/MI
Manolis ²²	2020	review (no original data)
Mi ²³	2020	no CVT reported, only DVT (deep venous thrombosis)
Patel ²⁴	2020	no CVT reported (case report on cerebellar infarction)
Román ²⁵	2020	review, no original data
Roy-Gash ²⁶	2020	duplicate
Shakibajhromi ²⁷	2020	no original data on CVT
Speeckaert ²⁸	2020	no original data
Suri ²⁹	2020	review, no CVT reported
Sweid ³⁰	2020	case series with ischemic stroke, aneurysm and CVT, no data available
Vinayagam ³¹	2020	Review on thrombophilia in COVID-19, CVT not specifically reported
Warkentin ³²	2020	review (no original data)
Zavras ³³	2020	no CVT reported
Zhou ³⁴	2020	review, no original data

Legend. CT: computerized tomography; CVT: cerebral venous thrombosis; DVT: deep venous thrombosis; MI: myocardial infarction.

Supplementary material Table 2. Risk of bias assessment

Author	Year	Selection		Ascertainment		Comparability	Outcome and reporting			Score	Overall quality
		Representativeness	Selection of the cohort	Ascertainment of exposure	Baseline assessment		Assessment of outcome	Follow-up length	Adequacy of ascertainment		
Baudar ³⁵	2020	0	1	1	1	0	1	0	0	4	low
Bolaji ³⁶	2020	0	1	1	1	0	1	1	0	5	low
Cavalcanti ³⁷	2020	0	1	1	1	0	1	1	1	6	moderate
Chougar ³⁸	2020	0	1	1	1	0	1	1	0	5	low
Chow ³⁹	2020	0	1	1	1	0	1	1	0	5	low
Dahl-Cruz ⁴⁰	2020	0	1	1	1	0	1	0	0	4	low
Essajee ⁴¹	2020	0	1	1	1	0	1	1	0	5	low
Garaci ⁴²	2020	0	1	1	1	0	0	0	0	3	low
Haroon ⁴³	2020	0	1	1	0	0	0	0	0	2	Low
Hemasian ⁴⁴	2020	0	1	1	1	0	1	0	0	4	low
Hoelscher ⁴⁵	2020	0	1	1	1	0	1	1	0	5	low
Hughes ⁴⁶	2020	0	1	1	1	0	1	0	0	4	low
Kananeh ⁴⁷	2020	0	1	1	0	0	1	1	1	5	low
Keaney ⁴⁸	2020	0	0	0	1	0	1	0	0	2	low
Klein ⁴⁹	2020	0	1	1	1	0	1	0	0	4	low
Koh ⁵⁰	2020	1	1	1	1	0	1	0	0	5	low
Malentacchi ⁵¹	2020	0	1	1	1	0	1	1	0	5	low
Mowla ⁵²	2020	1	1	1	1	1	1	0	0	6	moderate
Poillon ⁵³	2020	0	1	1	1	0	1	0	0	4	low
Rifino ⁵⁴	2020	1	1	1	1	0	1	0	0	5	low
Rouyer ⁵⁵	2020	0	1	0	0	0	0	0	0	1	low
Roy-Gash ⁵⁶	2020	0	1	0	1	0	1	1	0	4	low
Shahjouei ⁵⁷	2020	1	1	1	1	0	1	0	0	5	low
Siegler ⁵⁸	2020	1	1	0	1	0	0	0	0	3	low
Sugiyama ⁵⁹	2020	0	1	1	1	0	1	0	0	4	Low
Thompson ⁶⁰	2020	0	1	0	1	0	1	0	0	3	low
Trimaille ⁶¹	2020	1	0	1	1	0	1	0	0	4	low
Tu ⁶²	2020	0	1	1	0	0	1	1	0	4	low

Supplementary material – Table 3. Sensitivity analysis.

Analysis	Lowest/highest prevalence (95%CI)	Study left out	I²	P_{heterogeneity}
CVT among patients hospitalized	0.03 % (0.02-0.06) 0.13% (0.01-1.41)	Trimaille ⁶¹ Siegler ⁵⁸	0% 92%	0.64 0.006
CVT among cerebrovascular diseases	2.82% (1.52-5.16) 5.67% (1.67-17.51)	Koh ⁵⁰ Siegler ⁵⁸	0% 70%	0.48 0.04

Leave-one out paradigm applied to meta-analysis of proportions, with reported highest and lowest prevalence according to study left out.

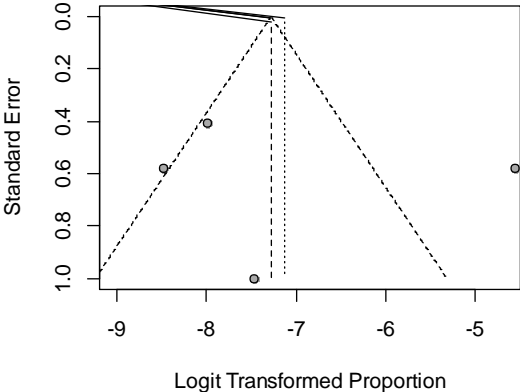
Supplementary material Table 4 – Laboratory findings of included.

Author	Year	Laboratory work-up	Fibrinogen (mg/dl)	D-dimer (ng/ml)	Screening for thrombophilia	Thrombophilia detected	LAC	anti-cardiolipin	anti-β2 glycoprotein I
Baudar ³⁵	2020	abnormal	420	902	factor II, antithrombin III, protein C, protein S, activated protein C resistance, antiphospholipid antibodies, ANCA	no	negative	negative	negative
Bolaji ³⁶	2020	abnormal	568	477	factor V, antithrombin III, protein C, protein S, antiphospholipids, ANA	yes	positive	negative	negative
Cavalcanti ³⁷	2020	abnormal		18902.33	NA				
Chougar ³⁸	2020	NA	NA	NA	yes (undefined)	no	NA	NA	NA
Chow ³⁹	2020	abnormal	352	2020	NA	NA	NA	NA	NA
Dahl-Cruz ⁴⁰	2020	abnormal	NA	6100	NA	NA	NA	NA	NA
Essajee ⁴¹	2020	abnormal	520	14800	NA	NA	NA	NA	NA
Garaci ⁴²	2020	abnormal	NA	5975	NA	NA	NA	negative	negative
Haroon ⁴³	2020	abnormal	NA	1020	normal	no	NA	NA	NA
Hemasian ⁴⁴	2020	normal	NA	NA	yes (undefined)	no	NA	NA	NA
Hoelscher ⁴⁵	2020	NA	NA	NA	yes (undefined)	no	NA	NA	NA
Hughes ⁴⁶	2020	abnormal	490	NA	NA	NA	NA	NA	NA
Kananeh ⁴⁷	2020	abnormal	429	7873	LAC	yes	positive	NA	NA
Keaney ⁴⁸	2020	abnormal (n=1)			NA	NA	NA	NA	NA
Klein ⁴⁹	2020	abnormal	NA	2876	AT-III, factor V, anti-phospholipids	yes	negative	positive	positive
Koh ⁵⁰	2020	abnormal (n=2)		NA	NA	NA	NA	NA	NA
Malentacchi ⁵¹	2020	abnormal	539	2017	NA	NA	NA	NA	NA
Mowla ⁵²	2020	abnormal	NA	1533	NA	NA	NA	NA	NA
Poillon ⁵³	2020	abnormal (n=2)		1890	NA	NA	NA	NA	NA
Rifino ⁵⁴	2020	NA	NA	NA	NA	NA	NA	NA	NA
Rouyer ⁵⁵	2020	NA	NA	NA	NA	NA	NA	NA	NA
Roy-Gash ⁵⁶	2020	abnormal	720	NA	factor V, antithrombin III, protein C, protein S, antiphospholipids	no	negative	negative	negative
Shahjouei ⁵⁷	2020	NA	NA	NA	NA	NA	NA	NA	NA
Siegler ⁵⁸	2020	NA	NA	NA	NA	NA	NA	NA	NA
Sugiyama ⁵⁹	2020	normal	NA	1100	NA	NA	NA	NA	NA
Thompson ⁶⁰	2020	abnormal	380	NA	LAC, anti-cardiolipin, anti-β2 glycoprotein I	yes	negative	positive	negative
Trimaille ⁶¹	2020	NA	NA	NA	NA	NA	NA	NA	NA
Tu ⁶²	2020	abnormal (n=1)	NA	4600	unspecified	yes (n=1)	positive (n=1)	negative	negative
Overall		35/41 (85.4%) abnormal	490.8± 112.9	7812.4± 15062.7	8/38 (21.1%)	5/12 (41.7%)	3/8 (37.5%)	2/8 (25%)	0/8 (0%)

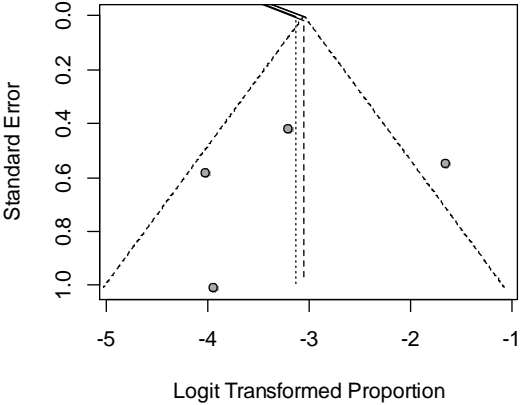
Legend. ANA: antinuclear antibodies; ANCA: anti-neutrophil cytoplasm antibodies; LAC: Lupus anti-coagulant; NA: not available.

Figure 1. Funnel plots for studies addressing cerebral venous thrombosis among patients hospitalized with SARS-CoV-2 (A) and among patients hospitalized with SARS-CoV-2 infection and referred with a cerebrovascular event (B)

A



B



References for supplementary material

1. Bengler M, Williams O, Siddiqui J, Sztrihla L. Intracerebral haemorrhage and COVID-19: Clinical characteristics from a case series. *Brain Behav Immun*. Elsevier; Epub 2020.:0–1.
2. Bhatia R, Srivastava MVP. COVID-19 and Stroke: Incidental, Triggered or Causative. *Ann Indian Acad Neurol*. 2020;23:318–324.
3. Cheruiyot I, Kipkorir V, Ngure B, Misiani M, Munguti J, Ogeng'o J. Arterial Thrombosis in Coronavirus Disease 2019 Patients: A Rapid Systematic Review. *Ann Vasc Surg*. Epub 2020 Aug.
4. Chougar L, Shor N, Weiss N, et al. Retrospective Observational Study of Brain Magnetic Resonance Imaging Findings in Patients with Acute SARS-CoV-2 Infection and Neurological Manifestations. *Radiology*. Epub 2020 Jul.:202422.
5. Divani AA, Andalib S, Di Napoli M, et al. Coronavirus Disease 2019 and Stroke: Clinical Manifestations and Pathophysiological Insights. *J Stroke Cerebrovasc Dis*. 2020;29.
6. Elnahry AG, Elnahry GA. Management of Idiopathic Intracranial Hypertension during the COVID19 Pandemic. *Rev Recent Clin Trials*. 2020;15.
7. Etkin Y, Conway AM, Silpe J, et al. Acute Arterial Thromboembolism in Patients with COVID-19 in the New York City Area. *Ann Vasc Surg*. Epub 2020 Aug.
8. Fara MG, Stein LK, Skliut M, Morgello S, Fifi JT, Dhamoon MS. Macrothrombosis and stroke in patients with mild Covid-19 infection. *J. Thromb. Haemost*. 2020. p. 2031–2033.
9. Fatima N, Saqqur M, Qamar F, Shaukat S, Shuaib A. Impact of COVID-19 on neurological manifestations: an overview of stroke presentation in pandemic. *Neurol Sci Off J Ital Neurol Soc Ital Soc Clin Neurophysiol*. 2020;41:2675–2679.
10. Favas TT, Dev P, Chaurasia RN, et al. Neurological manifestations of COVID-19: a systematic review and meta-analysis of proportions. *Neurol Sci Off J Ital Neurol Soc Ital Soc Clin Neurophysiol*. Epub 2020 Oct.:1–34.
11. Jiménez-Ruiz A, García-Grimshaw M, Ruiz-Sandoval JL. Neurological manifestations of COVID-19. *Gac Med Mex*. Mexico; 2020;156.
12. Kadono Y, Nakamura Y, Ogawa Y, et al. A case of COVID-19 infection presenting with a seizure following severe brain edema. *Seizure*. Elsevier; 2020;80:53–55.
13. Klein DE, Libman R, Kirsch C, Arora R. Author's response to Letter to the Editor: Anticoagulant approach in COVID-19 patients with cerebral venous thrombosis. *J Stroke Cerebrovasc Dis*. Epub 2020 Jul.:105227.
14. Klok FA, Kruip MJHA, van der Meer NJM, et al. Incidence of thrombotic complications in critically ill ICU patients with COVID-19. *Thromb Res*. Elsevier; 2020;191:145–147.
15. Klok FA, Kruip MJHA, van der Meer NJM, et al. Confirmation of the high cumulative incidence of thrombotic complications in critically ill ICU patients with COVID-19: An updated analysis. *Thromb Res*. Elsevier; Epub 2020.:1–3.
16. Koralnik IJ, Tyler KL. COVID-19: A Global Threat to the Nervous System. *Ann Neurol*. 2020;88:1–11.
17. Kow CS, Zaihan AF, Hasan SS. Anticoagulant approach in COVID-19 patients with cerebral venous thrombosis. *J Stroke Cerebrovasc Dis*. Epub 2020 Aug.:105222.
18. Kremer S, Lersy F, de Sèze J, et al. Brain MRI Findings in Severe COVID-19: A Retrospective Observational Study. *Radiology*. Epub 2020.:202222.
19. Kulick-Soper C V, McKee JL, Wolf RL, et al. Pearls & Oy-sters: Bilateral globus pallidus lesions in a patient with COVID-19. *Neurology*. 2020;95:454–457.
20. Li Y, Li M, Wang M, et al. Acute cerebrovascular disease following COVID-19: a single center,

retrospective, observational study. *Stroke Vasc Neurol*. Epub 2020.:1–6.

21. Lodigiani C, Iapichino G, Carenzo L, et al. Venous and arterial thromboembolic complications in COVID-19 patients admitted to an academic hospital in Milan, Italy. *Thromb Res*. Elsevier Ltd; 2020;191:9–14.
22. Manolis AS, Manolis TA, Manolis AA, Papatheou D, Melita H. COVID-19 Infection: Viral Macro- and Micro-Vascular Coagulopathy and Thromboembolism/Prophylactic and Therapeutic Management. *J Cardiovasc Pharmacol Ther*. Epub 2020 Sep 14.:107424842095897.
23. Mi B, Chen L, Tong D, et al. Delayed surgery versus nonoperative treatment for hip fractures in post-COVID-19 arena: a retrospective study of 145 patients. *Acta Orthop*. Epub 2020 Sep 8.:1–5.
24. Patel HN, Syed A, Lobel JS, et al. Cerebellar infarction requiring surgical decompression in patient with COVID 19 pathological analysis and brief review. *Interdiscip. Neurosurg. Adv. Tech. case Manag*. 2020. p. 100850.
25. Román GC, Spencer PS, Reis J, et al. The neurology of COVID-19 revisited: A proposal from the Environmental Neurology Specialty Group of the World Federation of Neurology to implement international neurological registries. *J Neurol Sci*. 2020;414:116884.
26. Roy-Gash F, De Mesmay M, Devys J-M, Vespignani H, Blanc R, Engrand N. Correction to: COVID-19-associated acute cerebral venous thrombosis: clinical, CT, MRI and EEG features. *Crit Care*. 2020;24:528.
27. Shakibajahromi B, Borhani-Haghighi A, Haseli S, Mowla A. Cerebral venous sinus thrombosis might be under-diagnosed in the COVID-19 era. *eNeurologicalSci*. 2020;20:14–16.
28. Speeckaert MM, Speeckaert R, Delanghe JR. Potential underlying mechanisms of cerebral venous thrombosis associated with COVID-19. *J Neuroradiol*. Elsevier Masson SAS; Epub 2020.:1033–1034.
29. Suri JS, Puvvula A, Biswas M, et al. COVID-19 pathways for brain and heart injury in comorbidity patients: A role of medical imaging and artificial intelligence-based COVID severity classification: A review. *Comput Biol Med*. 2020;124:103960.
30. Sweid A, Hammoud B, Bekelis K, et al. EXPRESS: Brain ischemic and hemorrhagic complications of COVID-19. *Int J Stroke*. Epub 2020.:1747493020937189.
31. Vinayagam S, Sattu K. SARS-CoV-2 and coagulation disorders in different organs. *Life Sci*. 2020;260:118431.
32. Warkentin TE, Kaatz S. COVID-19 versus HIT hypercoagulability. *Thromb Res*. 2020;196:38–51.
33. Zavras PD, Kabarriti R, Mehta V, Goel S, Billett HH. Clinical Thrombosis Rate was not Increased in a Cohort of Cancer Patients with COVID-19. *medRxiv Prepr Serv Heal Sci*. Epub 2020 Sep 18.
34. Zhou Z, Kang H, Li S, Zhao X. Understanding the neurotropic characteristics of SARS-CoV-2: from neurological manifestations of COVID-19 to potential neurotropic mechanisms. *J Neurol*. Springer Berlin Heidelberg; 2020;267:2179–2184.
35. Baudar C, Duprez T, Kassab A, Miller N, Rutgers MP. COVID-19 as triggering co-factor for cortical cerebral venous thrombosis? *J Neuroradiol*. Elsevier Masson SAS; Epub 2020.
36. Bolaji P, Kukoyi B, Ahmad N, Wharton C. Extensive cerebral venous sinus thrombosis: a potential complication in a patient with COVID-19 disease. *BMJ Case Rep*. 2020;13.
37. Cavalcanti DD, Raz E, Shapiro M, et al. Cerebral venous thrombosis associated with COVID-19. *Am J Neuroradiol*. United States; 2020;41:1–7.
38. Chougar L, Mathon B, Weiss N, Degos V, Shor N. Atypical Deep Cerebral Vein Thrombosis with Hemorrhagic Venous Infarction in a Patient Positive for COVID-19. *Am J Neuroradiol*. United States; 2020;41:1–3.
39. Chow LC, Chew LP, Leong TS, Mohamad Tazuddin EE, Chua HH. Thrombosis and Bleeding as

Presentation of COVID-19 Infection with Polycythemia Vera. A Case Report. *SN Compr Clin Med*. Epub 2020.

40. Dahl-Cruz F, Guevara-Dalrymple N, López-Hernández N. [Cerebral venous thrombosis and SARS-CoV-2 infection]. *Rev. Neurol. Spain*; 2020. p. 391–392.
41. Essajee F, Solomons R, Goussard P, Van Toorn R. Child with tuberculous meningitis and COVID-19 coinfection complicated by extensive cerebral sinus venous thrombosis. *BMJ Case Rep*. 2020;13:e238597.
42. Garaci F, Di Giuliano F, Picchi E, Da Ros V, Floris R. Venous cerebral thrombosis in COVID-19 patient. *J Neurol Sci*. Elsevier; 2020;414:116871.
43. Haroon KH, Muhammad A, Hussain S, Patro SN. COVID-19 Related Cerebrovascular Thromboembolic Complications in Three Young Patients. *Case Rep Neurol*. Epub 2020.:321–328.
44. Hemasian H, Ansari B. First case of Covid-19 presented with cerebral venous thrombosis: A rare and dreaded case. *Rev Neurol (Paris)*. Elsevier Masson SAS; 2020;176:521–523.
45. Hoelscher C, Sweid A, Ghosh R, et al. Cerebral deep venous thrombosis and COVID-19: case report. *J Neurosurg*. Epub 2020 Sep.:1–4.
46. Hughes C, Nichols T, Pike M, Subbe C, Elghenzai S. Cerebral Venous Sinus Thrombosis as a Presentation of COVID-19. *Eur J case reports Intern Med*. 2020;7:1691.
47. Kananeh MF, Thomas T, Sharma K, et al. Arterial and venous strokes in the setting of COVID-19. *J Clin Neurosci Off J Neurosurg Soc Australas*. 2020;79:60–66.
48. Keaney K, Mumtaz T. Cerebral venous thrombosis in patients with severe COVID-19 infection in intensive care. *Br J Hosp Med*. 2020;81:1–4.
49. Klein DE, Libman R, Kirsch C, Arora R. Cerebral venous thrombosis: A typical presentation of COVID-19 in the young. *J Stroke Cerebrovasc Dis*. Elsevier Inc.; 2020;29:104989.
50. Koh JS, De Silva DA, Quek AML, et al. Neurology of COVID-19 in Singapore. *J Neurol Sci*. 2020;418:117118.
51. Malentacchi M, Gned D, Angelino V, et al. Concomitant brain arterial and venous thrombosis in a COVID-19 patient. *Eur J Neurol*. 2020;27.
52. Mowla A, Shakibajahromi B, Shahjouei S, et al. Cerebral venous sinus thrombosis associated with SARS-CoV-2; a multinational case series. *J Neurol Sci*. 2020;419:117183.
53. Poillon G, Obadia M, Perrin M, Savatovsky J, Lecler A. Cerebral venous thrombosis associated with COVID-19 infection: Causality or coincidence? *J. Neuroradiol. = J. Neuroradiol*. 2020.
54. Rifino N, Censori B, Agazzi E, et al. Neurologic manifestations in 1760 COVID-19 patients admitted to Papa Giovanni XXIII Hospital, Bergamo, Italy. *J Neurol*. Epub 2020 Oct 7.
55. Rouyer O, Pierre-Paul I-N, Balde A, et al. High prevalence of deep venous thrombosis in non-severe COVID-19 patients hospitalized for a neurovascular disease. *medRxiv*. Epub 2020.:2020.09.03.20187344.
56. Roy-Gash F, Marine DM, Jean-Michel D, Herve V, Raphael B, Nicolas E. COVID-19-associated acute cerebral venous thrombosis: Clinical, CT, MRI and EEG features. *Crit Care. Critical Care*; 2020;24:1–3.
57. Shahjouei S, Naderi S, Li J, et al. Risk of stroke in hospitalized SARS-CoV-2 infected patients: A multinational study. *EBioMedicine*. 2020;59:102939.
58. Siegler JE, Cardona P, Arenillas JF, et al. Cerebrovascular events and outcomes in hospitalized patients with COVID-19: The SVIN COVID-19 Multinational Registry. *Int J stroke Off J Int Stroke Soc*. Epub 2020 Sep.:1747493020959216.
59. Sugiyama Y, Tsuchiya T, Tanaka R, et al. Cerebral venous thrombosis in COVID-19-associated

coagulopathy: A case report. *J. Clin. Neurosci. Off. J. Neurosurg. Soc. Australas.* 2020. p. 30–32.

60. Thompson A, Morgan C, Smith P, et al. Cerebral venous sinus thrombosis associated with COVID-19. *Pract Neurol.* Epub 2020 Oct 8.
61. Trimaille A, Curtiaud A, Marchandot B, et al. Venous thromboembolism in non-critically ill patients with COVID-19 infection. *Thromb Res.* 2020;193:166–169.
62. Tu TM, Goh C, Tan YK, et al. Cerebral Venous Thrombosis in Patients with COVID-19 Infection: a Case Series and Systematic Review. *J Stroke Cerebrovasc Dis.* 2020;29:1–9.