

Supplementary Materials

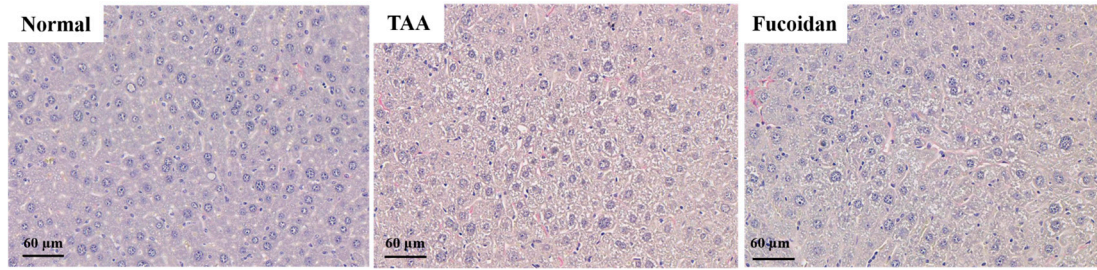


Figure 1. Changes of liver histology by sirius red staining (magnification, 200×).

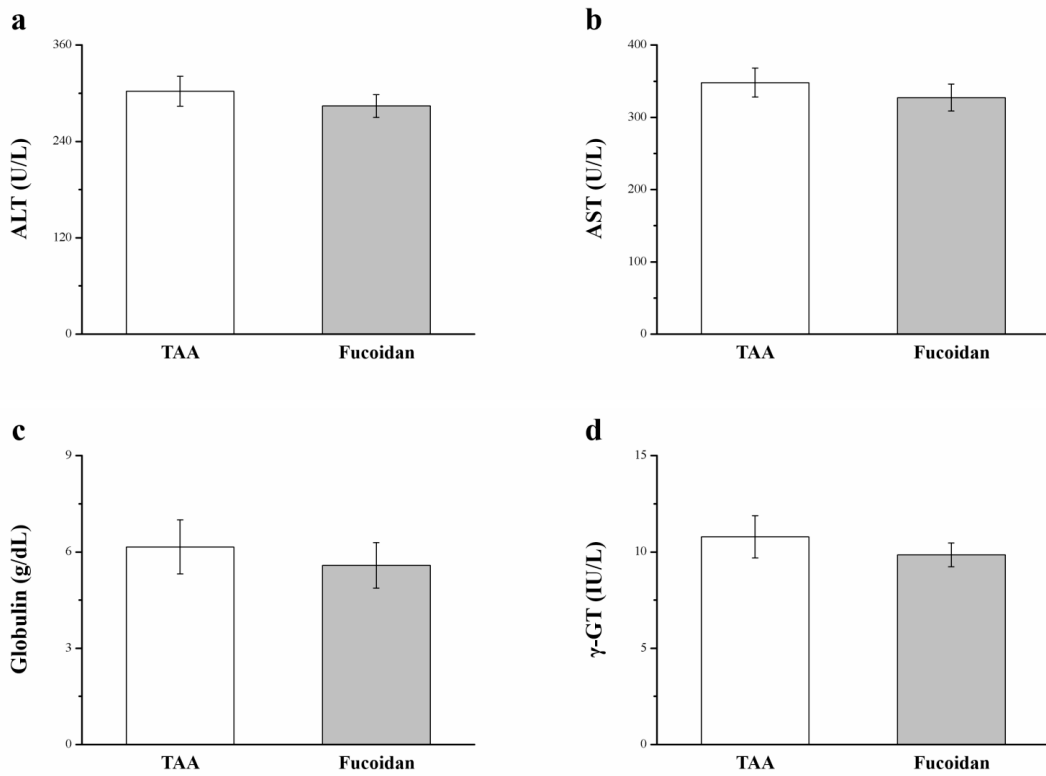


Figure 2. Changes of serum ALT, AST, globulin, and γ -GT levels in TAA-induced liver injury mice, and fucoïdan (10 mg/kg)-treated mice with TAA-induced liver injury, over a period of 42 days.