

**iScience, Volume 24**

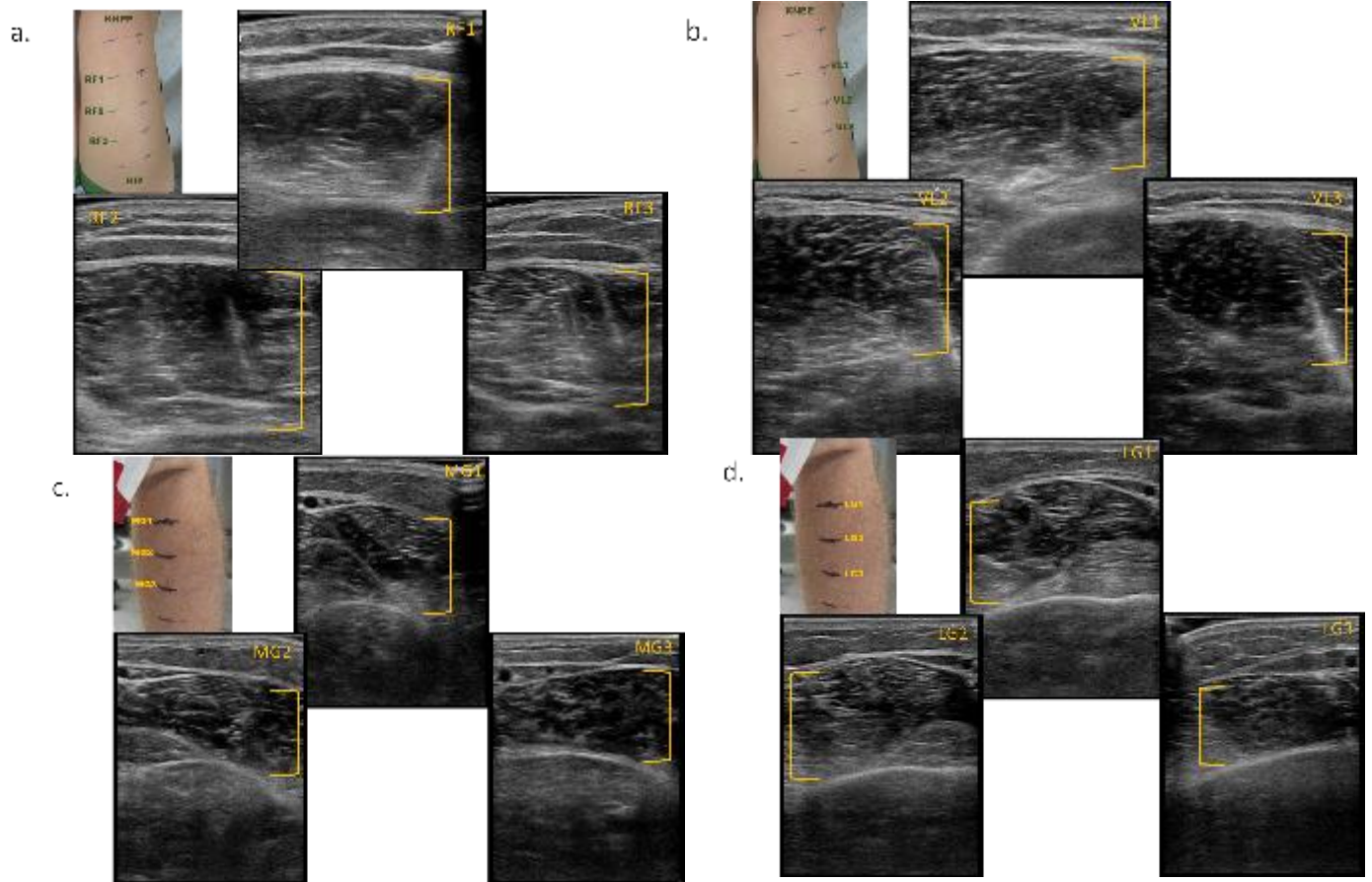
**Supplemental information**

**Teleguided self-ultrasound scanning  
for longitudinal monitoring of muscle  
mass during spaceflight**

**Jessica M. Scott, Meghan Downs, David S. Martin, Erik Houglund, Laura Sarmiento, Natalia Arzeno, Donald R. Pettit, Robert Ploutz-Snyder, David Cunningham, Lee W. Jones, Richard Do, and Lori Ploutz-Snyder**

## Supplemental Information

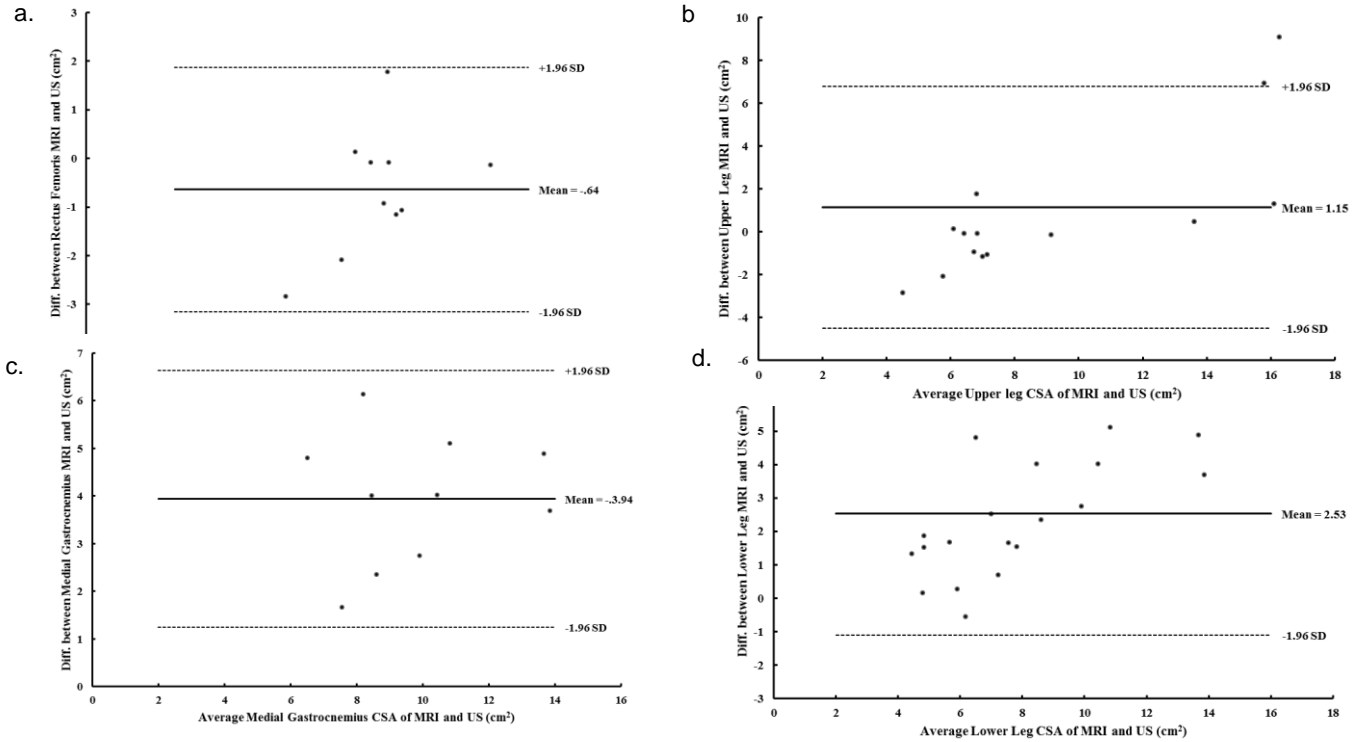
**Figure S1a-d. Muscle Thickness Acquisition Along Upper and Lower Leg.** (a) Rectus Femoris. (b) Vastus Lateralis. (c) Gastrocnemius Medialis. (d) Gastrocnemius Lateralis. **Related to Transparent Methods and Figure 1.**



**Figure S2a-b. Ultrasound Guide Prototype.** (a) Flexible kitchen cutting board. (b) Slices and Velcro straps to affix to leg. Related to Transparent Methods and Figure 2.

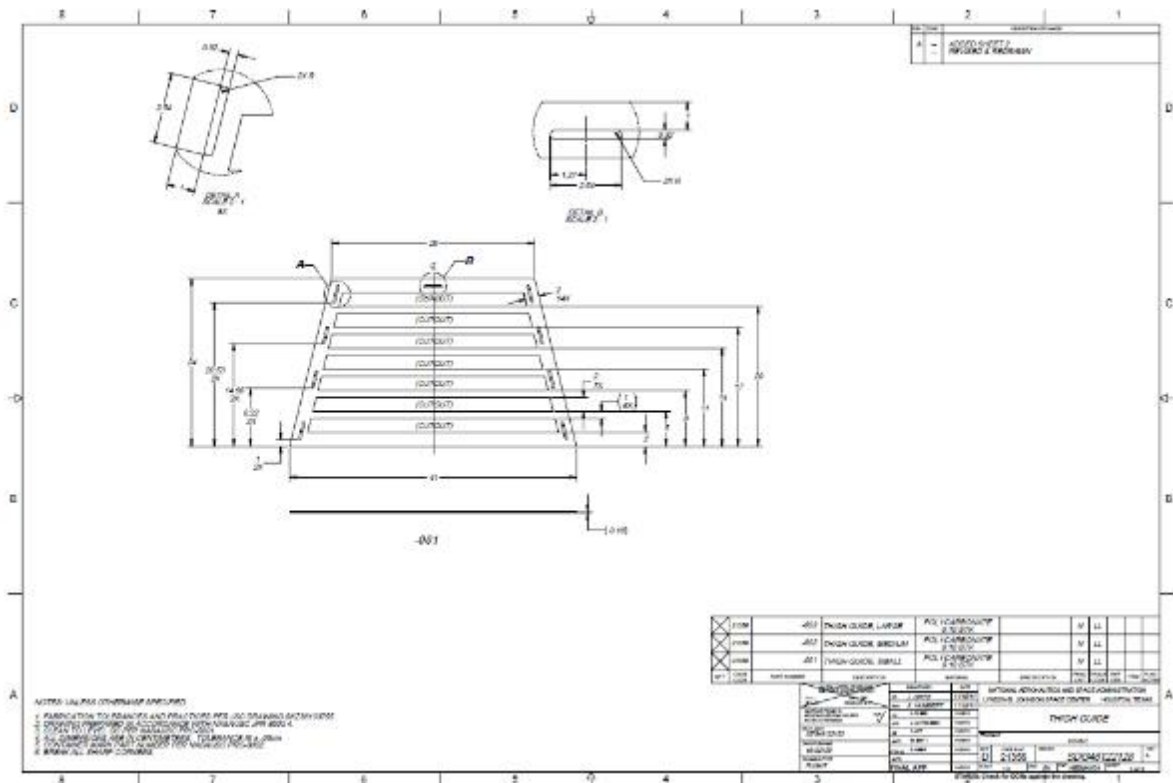


**Figure S3a-d. Bland Altman Plots of Panoramic Ultrasound Against MRI. (a) Rectus Femoris. (b) Vastus Lateralis. (c) Gastrocnemius Medialis. (d) Gastrocnemius Lateralis. Related to Transparent Methods and Figure 2.**

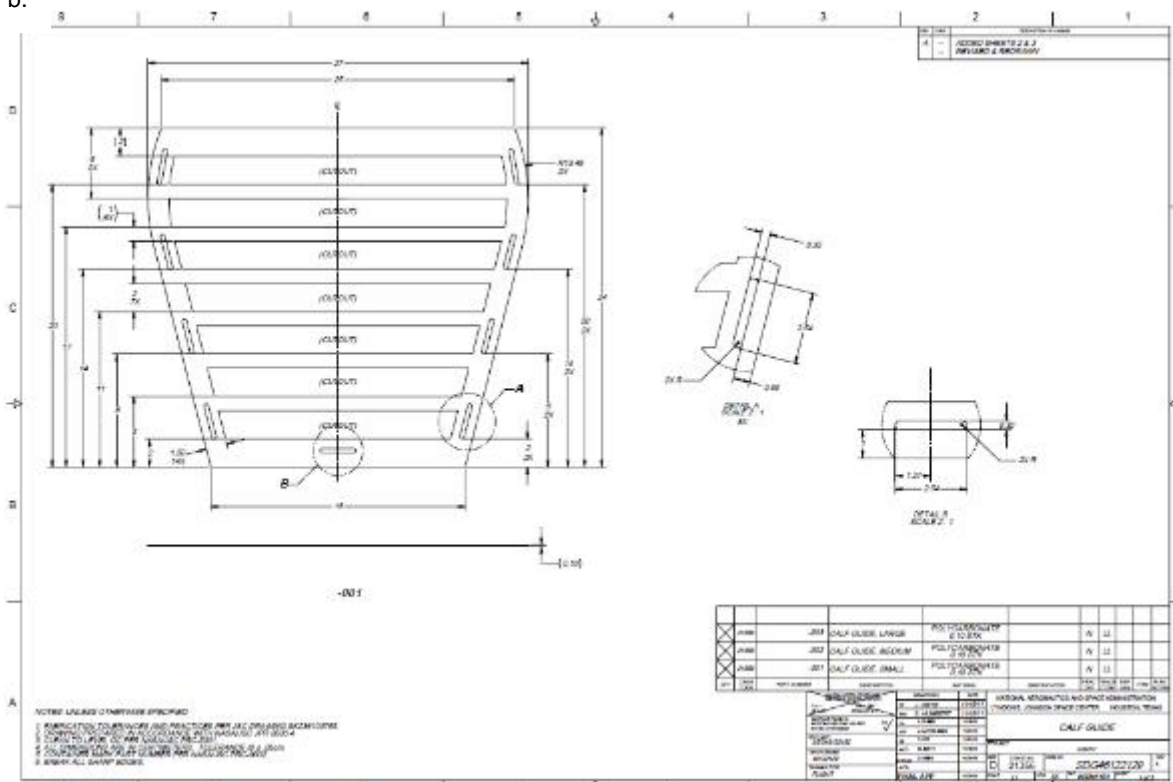


**Figure S4. Upper and Lower Leg Ultrasound Guides. (a) Thigh guide. (b) Calf guide. Related to Figure 2, Transparent Methods, and Results.**

a.

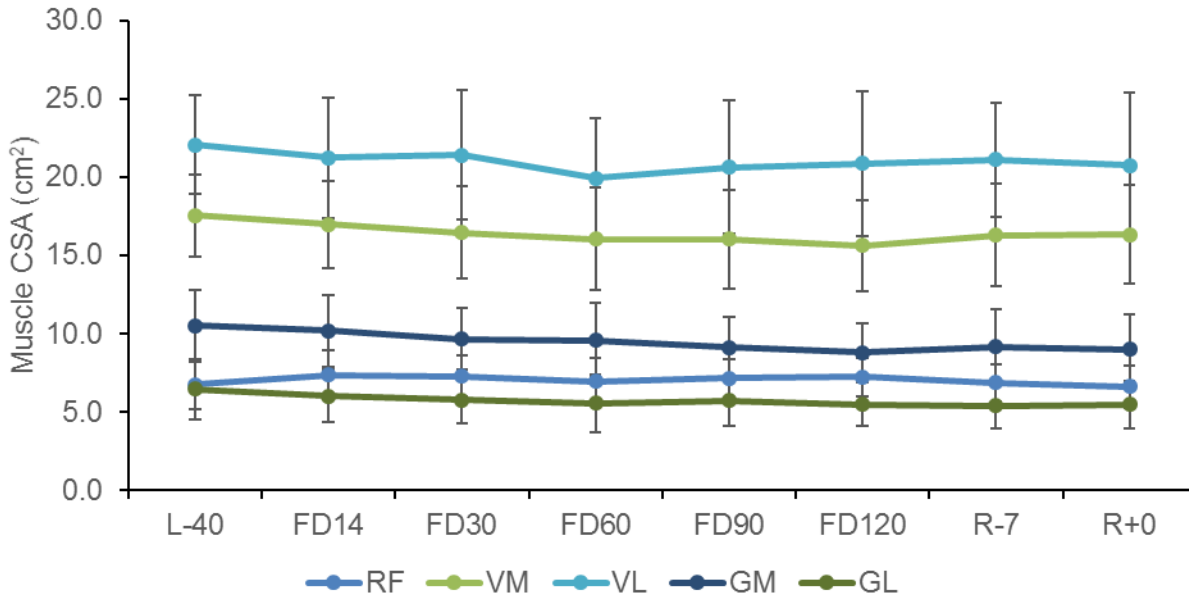


b.



**Figure S5. Time Course of Muscle Cross Sectional Area Change.**

Abbreviations: CSA, cross sectional area; RF, rectus femoris; VM, vastus medialis; VL, vastus lateralis; GM, gastrocnemius medialis; GL, gastrocnemius lateralis; L, launch; FD, flight day; R, recovery. **Related to Figure 2, Transparent Methods, and Results.** Data are mean  $\pm$  standard deviation.



**Table S1. Reliability of Ultrasound and MRI. Related to Transparent Methods and Figure 2.**

<b>MRI</b>					
	<b>RF</b>	<b>VL</b>	<b>GM</b>	<b>GL</b>	
<b>CV</b>	2.86	3.38	2.82	3.76	
<b>ICC</b>	0.986	0.962	0.976	0.946	

<b>Ultrasound</b>					
	<b>RF</b>	<b>VL</b>	<b>GM</b>	<b>GL</b>	
<b>CV</b>	2.39	2.79	3.11	4.05	
<b>ICC</b>	0.963	0.987	0.991	0.962	

Abbreviations: MRI, magnetic resonance imaging; CV, coefficient of variation; ICC, intraclass coefficient; RF, rectus femoris; VM, vastus medialis; VL, vastus lateralis; GM, gastrocnemius medialis; GL, gastrocnemius lateralis.

**Table S2. Tele-SUS Acquisition Time in Non-Astronaut Participant. Related to Transparent Methods and Figure 2.**

<b>Action</b>	<b>Time (min)</b>
Change Settings	2:00
Measure Marks	2:00
Don Thigh Guide	3:30
Don Calf Guide	1:30
Localize Muscles	3:30
RF Acquisition	8:20
VM Acquisition	10:40
VL Acquisition	12:00
Remove Thigh Guide	3:30
GM Acquisition	12:25
GL Acquisition	4:35
Remove Calf Guide	1:45
<b>TOTAL TIME</b>	<b>64</b>

Abbreviations: MRI, magnetic resonance imaging; CV, coefficient of variation; ICC, intraclass coefficient; RF, rectus femoris; VM, vastus medialis; VL, vastus lateralis; GM, gastrocnemius medialis; GL, gastrocnemius lateralis.



**Table S3. Tele-SUS Acquisition Time in Astronauts. Related to Figure 2, Transparent Methods, and Results.**

	<b>Thigh</b>	<b>Calf</b>	<b>Total</b>
<b>Average</b>	0:38:48	0:19:37	0:55:37
<b>Std. Dev.</b>	0:11:31	0:06:20	0:11:46
<b>Median</b>	0:36:44	0:17:58	0:55:40
<b>Minimum</b>	0:19:29	0:11:26	0:32:58
<b>Maximum</b>	1:09:56	0:33:42	1:22:43

**Table S4. Coefficient of Variation Between Raters. Related to Transparent Methods and Figure 2.**

Muscle	L-40	FD14	FD30	FD60	FD90
RF	8.0	8.7	5.3	5.6	4.1
VM	6.2	7.3	3.4	3.7	3.9
VL	9.5	7.8	5.3	5.0	3.7
GM	8.1	8.6	9.8	5.8	3.6
GL	9.3	4.8	12.2	7.4	10.6

Abbreviations: MRI, magnetic resonance imaging; CV, coefficient of variation; ICC, intraclass coefficient; RF, rectus femoris; VM, vastus medialis; VL, vastus lateralis; GM, gastrocnemius medialis; GL, gastrocnemius lateralis; L, launch; FD, flight day.

## Transparent Methods

### Muscle Thickness Tele-SUS Experiment

All National Aeronautics and Space Administration (NASA), Canadian Space Agency (CSA), European Space Agency (ESA), and Japan Aerospace Exploration Agency (JAXA) astronauts assigned to an International Space Station (ISS) flight were eligible and self-selected to participate in the study. The study was approved by the Institutional Review Board at NASA Johnson Space Center, the Japan Aerospace Exploration Agency (JAXA) Institutional Review Board, the European Space Agency (ESA) Medical Board, and the Human Research Multilateral Review Board; all participants provided written informed consent before participation in the study. A certified sonographer acquired ultrasound images of muscle thickness at four points along four muscles (RF, VL, GM, and GL; **Figs. 1a-b; Figs. S1a-d**) approximately 40 days before flight and one day post-flight, using B-mode axial-plane ultrasound (GE, Vivid q, Milwaukee, WI) with a 9-MHz linear-array probe (50-mm width). Axial spin-echo T2-weighted MRI images were acquired within 5 days of ultrasound from the level of the ankle mortise to the iliac crest supine in a 1.5-T scanner (Signa Horizon LX, General Electric, USA). Images of the upper and lower leg were collected by using a repetition time of 2000 ms, echo time of 51 ms, slice thickness of 10 mm, and a gap between slices of 10 mm. A matrix size of 512 × 512 was used for all scans, and the field of view was varied to maximize in-plane resolution for each scan. The Tele-SUS protocol was developed by a six-member team of sonographers, ultrasound experts, and remote guidance specialists that consisted of three phases: pre, during, and post ultrasound (**In-flight teleguided self-ultrasound scanning muscle thickness protocol**). A standardized Tele-SUS training module consisting of two, 60-minute didactic sessions was delivered to one astronaut prior to launch. Training included: (1) accurate placement of ultrasound probe along the leg, (2) techniques for acquiring muscle images of upper and lower leg, and (3) a full run-through of the Tele-SUS protocol in ISS training module. The astronaut also received approximately three hours of ultrasound training as part of standard flight procedures that included general ultrasound principles, appropriate ultrasound probe handling, and “knobology.” The in-flight Tele-SUS protocol was performed by a ground-based team located at the Telescience Support Center (TSC) at NASA’s Johnson Space Center Mission Control Center, Marshall Space Flight Center in Huntsville, Alabama, and an astronaut located on the ISS on flight days 90, 133, and 156 (**Fig. 2c**). The TSC team included a human research facility (HRF) Payload Systems Engineer that was responsible for configuration of the ISS HRF rack, monitoring status of HRF rack and equipment (e.g., ultrasound, laptop), and coordinating downlink of all images captured from ultrasound. An Operations Lead managed all activities in the TSC and coordinated the required resources with the Payload Operations and Integration Center (POIC) located at the Marshall Space Flight Center in Huntsville, Alabama. A Hardware Support Engineer (HSE) was tasked with monitoring and providing status and inputs for the Ultrasound unit on ISS, including managing the data transfer activities. An Experiment Support Scientist (ESS) supported the Remote Guider (RG) and relayed operational information between the RG and the rest of the TSC team during the activity to ensure the session met all necessary requirements. One-way video from the ISS to the TSC and two-way voice communication depended on Ku-band and S-band satellite availability. Video included cabin video of the astronaut and direct images from the ultrasound machine. The astronaut was instructed to: (1) use at least 0.5cm of gel on ultrasound probe, (2) keep probe perpendicular to skin, and (3) place probe lightly on skin to avoid compressing muscle. Images were saved, transferred to ISS computer resources, downlinked to the TSC team, and analyzed off-line. One rater manually evaluated all images (Image-J, National Institutes of Health, Bethesda, MD, USA, version 1.42) to determine muscle thickness (ultrasound) and leg muscle cross sectional area (CSA; MRI).

### IN-FLIGHT TELEGUIDED SELF-ULTRASOUND SCANNING MUSCLE THICKNESS PROTOCOL

#### SCANNING PREP

#### **CAUTION**

1. Keep the probe perpendicular to the skin.
2. Always keep the purple dot on the probe to the subject’s right. See Figure 2 for dot location on Scanhead.
3. Make sure there is at least 0.5 cm of Ultrasound Gel between the L12-5 Scanhead and the skin while scanning.

#### NOTE

1. Echo Gel Bottle is acceptable substitute for HRF Ultrasound Echo Gel.
2. Ultrasound Gel can be reused to scan multiple marks.

3. If the desired image is just missed after pressing "Freeze", it is possible to slide the track ball to the left to go back up to 150 previous images to find desired image to "Print".

- 6.1 Retrieve HRF Ultrasound Echo Gel and Dry Wipes.
- 6.2 Subject should use restraint device(s) of choice (foot straps, etc.) to ensure the right leg is bent at a relaxed 90° angle and they are positioned to reach the keyboard and view the HRF FSD and the Ultrasound Reference Picture.

If you wish to reference your specific ultrasound images from preflight baseline data collection, see execution note for private OCA message.

- 6.3 Remove L12-5 Scanhead cover

Apply at least 0.5 cm of gel to L12-5 Scanhead, covering entire Scanhead length..

## 7. REMOTE GUIDANCE SETUP

- 7.1 If remote guidance will be utilized

~

Unstow and setup COL lab video camera (VCA 1 or VCA 2) on Multi-Use Bracket (Bogen arm) with view showing subject and probe position on subject. Ensure COL lab video camera is capable of real time video downlink (required for this activity).

ATU/HCU

Check VOX configured for sound.

When setup is completed and crew has confirmed private video and voice are configured for the real-time remote guidance session with ground team

✓**POIC**

τ

### **On POIC GO**

Perform a verbal five count while tapping gelled L12-5 Scanhead and looking into the camera to synchronize private voice and video.

Perform step 8-12 with remote guidance from Sprint team on privatized Space-to-Ground loop to assist as needed and confirm correct capture of images.

## 8. PERFORM RECTUS FEMORIS SCANS

- 8.1 pb Text A → Press to annotate RF1.
- 8.2 Ensure there is at least 0.5 cm of gel on Scanhead. Begin scanning at the RF1 mark with the purple dot to the subject's right (the first mark will not be scanned).

Place Scanhead lightly on skin so that the wall of the muscle is not depressed.

- 8.3 Ensure rectus femoris is the correct position in the center of the screen.
- 8.4 pb Freeze → Press (Ultrasound Reference Picture, Section G) to capture image.

✓Image is satisfactory.

If not, pb Freeze → Press to unfreeze. Repeat step 8.3 until image is satisfactory.

- 8.5 pb Print → Press (Ultrasound Reference Picture, Section G) to store image.
- 8.6 pb Text A → Press to annotate next scan position (RF2, then RF3, then RF4).

- 8.7 pb Freeze → Press to unfreeze
- 8.8 Repeat steps 8.2 to 8.7 for RF2, RF3, and RF4 scans.
- 8.9 pb Erase Text → Press (Ultrasound Reference Picture, Section F, upper right) to delete annotation.

9. PERFORM VASTUS LATERALIS SCANS

- 9.1 pb Text B → Press to annotate VL1.
- 9.2 Ensure there is at least 0.5 cm of gel on Scanhead. Begin scanning at the VL1 mark with the purple dot to the subject's right (the first mark will not be scanned).  
  
Place Scanhead lightly on skin so that the wall of the muscle is not depressed.
- 9.3 Locate where vastus lateralis meets the rectus femoris.
- 9.4 Slide the probe laterally (right) so the Vastus/Rectus line is on the right edge of the screen.
- 9.5 pb Freeze → Press to capture image.  
  
√Image is satisfactory.  
  
If not, pb Freeze → Press to unfreeze. Repeat step 9.4 until image is satisfactory.
- 9.6 pb Print → Press to store image.
- 9.7 pb Text B → Press to annotate next scan position (VL2, then VL3, then VL4).
- 9.8 pb Freeze → Press to unfreeze
- 9.9 Repeat steps 9.2 to 9.8 for VL2, VL3, and VL4 scans.
- 9.10 pb Erase Text → Press to delete annotation.

10. PERFORM MEDIAL GASTROCNEMIUS SCANS

- 10.1 pb Text C → Press to annotate MG1.
- 10.2 Ensure there is at least 0.5 cm of gel on Scanhead. Begin scanning at the MG1 mark with the purple dot to the subject's right.  
  
Place Scanhead lightly on skin so that the wall of the muscle is not depressed.
- 10.3 Find the lesser saphenous vein where the lateral gastrocnemius (right) and medial gastrocnemius (left) meet.
- 10.4 Slide the probe medially (left) until the lesser saphenous vein is at the very edge of the screen.
- 10.5 pb Freeze → Press to capture image.  
  
√Image is satisfactory.  
  
If not, pb Freeze → Press to unfreeze. Repeat step 10.4 until image is satisfactory.

- 10.6 pb Print → Press to store image.
- 10.7 pb Text C → Press to annotate next scan position (MG2, then MG3, then MG4).
- 10.8 pb Freeze → Press to unfreeze
- 10.9 Repeat steps 10.2 to 10.8 for MG2, MG3, and MG4 scans.
- 10.10 pb Erase Text → Press to delete annotation.

## 11. PERFORM LATERAL GASTROCNEMIUS SCANS

- 11.1 pb Text D → Press to annotate LG1.
- 11.2 Ensure there is at least 0.5 cm of gel on Scanhead. Begin scanning at the LG1 mark with the purple dot to the subject's right.
- 11.3 Find the lesser saphenous vein where the lateral gastrocnemius and medial gastrocnemius meet.
- 11.4 Slide the probe laterally (right) until the lesser saphenous vein is at the very edge of the screen.
- 11.5 pb Freeze → Press to capture image.  
  - ✓Image is satisfactory.
  - If not, pb Freeze → Press to unfreeze. Repeat step 11.4 until image is satisfactory.
- 11.6 pb Print → Press to store image.
- 11.7 pb Text D → Press to annotate next scan position (LG2, then LG3, then LG4).
- 11.8 pb Freeze → Press to unfreeze
- 11.9 Repeat steps 11.2 to 11.8 for LG2, LG3, and LG4 scans.
- 11.10 pb Erase Text → Press to delete annotation.

## 12. POST SCANNING ACTIVITY

- 12.1 Wipe leg clean with Dry Wipes.
- Ultrasound Keyboard 12.2 pb END EXAM → Press (Ultrasound Reference Picture, Section A, top right) to close out patient file.
- 12.3 Wipe clean transducer end of HRF Ultrasound L12-5 Scanhead with Dry Wipes.
- HRF USND Replace L12-5 Scanhead Transducer cover.
- 12.4 If remote guidance was utilized  
 ~ Turn off video camera and VOX.

## 13. FILE TRANSFER CHECK

Ultrasound Keyboard 13.1 pb NET/DISK → Press (Ultrasound Reference Picture, Section A, fourth row)

HRF FSD 13.2 **Net/Disk**  
sel Hard Disk

**NOTE**  
A temporary window will appear: '**Reading patient exams ...**'

13.3 **Exam Directory: Hard Disk**

Verify 'Sent' column displays 'Yes' for the Exam file(s) created in this session.

If 'Yes' hasn't yet appeared in 'Sent' column,

↓ sel Close

sel Close

Wait five minutes and repeat step 13.1.

If after five minutes 'Yes' still hasn't appeared,

↓ ✓**POIC**

↑

sel Close

13.4 **Net/Disk**  
sel Close

### Panoramic Ultrasound Experiments

We performed three studies evaluating panoramic ultrasound. First, panoramic imaging was evaluated in 10 healthy individuals (5 male, 5 female; age:  $32.2 \pm 12.0$  years; body mass:  $63.7 \pm 21.3$  kg). The study was approved by the Committee for the Protection of Human Subjects at Johnson Space Center, and all participants provided written informed consent prior to the experiment. Ultrasound (Phillips iE33) images were acquired with a 9-MHz linear-array probe in panoramic mode by an expert sonographer. To obtain the images, a prototype ultrasound guide (**Figs. S2a-b**) was placed on the thigh and calf. The slice gaps on the guide provided a channel that the ultrasound probe could be guided through, allowing the operator to focus on the resulting image being compiled on the screen. A continuous, single view was taken by moving the probe transversely across the thigh and calf within each guide slice in ~4 s to acquire images of the RF, VL, MG, and LG. A consistent, minimal pressure was applied with the probe to the skin to avoid compression of the muscle aided by the application of a transmission gel to improve acoustic coupling. T2-weighted MRI images were acquired from the ankle mortise to the iliac crest in a 1.5-T scanner (Signa Horizon LX, General Electric, USA). Images were collected using a repetition time of 2000 ms, echo time of 51 ms, with slice thickness and gap between slices of 10 mm. and a matrix size of  $512 \times 512$ . To match ultrasound with corresponding with MRI images, oil-filled capsules were taped to the skin. Two observers manually traced images from all participants (ultrasound: MATLAB, Mathworks, USA; MRI: Image-J, National Institutes of Health, Bethesda, MD, USA, version 1.42). The average of the analyzed slices was used to calculate muscle CSA. (Trappe et al., 2007) The inter-examiner reliability for MRI and US was calculated using the coefficient of variation (CV), intraclass coefficient (ICC) (**Table S1**), and visually assessed with Bland-Altman plots (**Fig. S3a-d**).

For the second study, we developed customized ultrasound guides to maintain probe position during acquisition of ultrasound images (**Figs. S4a-b**). Guides consisted of five to eight 1.5-cm slices with a 1.5-cm gap between slices with four straps to fix the guide in place. (Scott et al., 2012) This study was approved by the Committee for the Protection of Human Subjects at Johnson Space Center. In brief, panoramic imaging was evaluated in 9 healthy individuals (8 male, 1 female; age:  $34.5 \pm 8.2$  years; body mass:  $74.7 \pm 10.5$  kg; height:  $177.1 \pm 5.5$  cm) participating in a 14-day bed rest with exercise study. Bed rest is an internationally recognized analog of spaceflight. (Sundblad et al., 2016) Both ultrasound and MRI images were acquired on the right leg in the morning on days 1, 7, and 14 of bed rest. To ensure ultrasound guide placement was identical, on day 1 the distance from the footplate to the guide was measured and reproduced on days 7

and 14. Ultrasound (images Phillips iE33) were acquired with a 9-MHz linear-array probe in panoramic mode by a trained sonographer. MRI images were acquired as previously described with oil-filled capsules taped to the skin. Two observers manually traced images (ultrasound: MATLAB, Mathworks, USA; MRI: Image-J, National Institutes of Health, Bethesda, MD, USA, version 1.42). (Arbeille et al., 2009; Trappe et al., 2007). The average of the analyzed slices was used to calculate CSA for ultrasound and MRI. (Trappe et al., 2007) Inter-examiner reliability for MRI and ultrasound was calculated using CV, and ICC was calculated using a one-way random effects model. Modified Bland-Altman plots were used to assess the difference between MRI and ultrasound (Bland and Altman, 2007), and repeated MRI and ultrasound measures (days 1, 7, 14) were submitted to a mixed-effects linear regression.

Finally, we assessed the validity of panoramic ultrasound to detect change in quadriceps and gastrocnemius size in comparison with MRI in participants randomized to 70 days of bedrest with or without exercise. (Cromwell et al., 2018; Scott et al., 2017) The study was approved by both the NASA Johnson Space Center and University of Texas Medical Branch institutional review boards and all subjects provided written informed consent (ClinicalTrials.gov Identifier: NCT00891449). Briefly, 27 participants (26 male, 1 female; age:  $34.6 \pm 7.8$  years; body mass:  $77.5 \pm 10.0$  kg; body mass index (BMI):  $24.2 \pm 2.8$  kg/m<sup>2</sup>; height:  $179.1 \pm 6.9$  cm) completed 70 days of bed rest. Both MRI and ultrasound images were acquired on the right leg in the morning before (BR-6), during (BR3, 7, 11, 15, 22, 29, 36, 53, 69), and after (BR+3, +6, +10) BR. The quadriceps including VM, vastus intermedius, VL, and RF, and gastrocnemius including GM, and GL were assessed using panoramic ultrasound (Phillips iE33) and MRI (3-T scanner, Signa Horizon LX, General Electric, USA). MRI and ultrasound images from all participants (ultrasound: MATLAB, Mathworks, USA; MRI: Image-J, National Institutes of Health, USA, version 1.42) were manually traced with the average of analyzed slices used to determine CSA. (Arbeille et al., 2009; Scott et al., 2012; Trappe et al., 2007) The. (Scott et al., 2012; Trappe et al., 2007) Bland-Altman plots using bootstrapped standard error estimates to accommodate the multiple measurements within subjects. Concordance in absolute change in CSA from BR-3 measured by ultrasound and MRI was assessed by Lin's concordance correlation coefficient (CCC), (Carrasco and Jover, 2003) and MRI and ultrasound change scores were dichotomized into atrophy or hypertrophy. Sensitivity was defined as the percent of true muscle atrophy observations that ultrasound identified; specificity was defined as the percent of true muscle hypertrophy observations that ultrasound identified.

### **Tele-SUS Panoramic Imaging Experiment**

We modified the original muscle thickness Tele-SUS protocol for acquisition of panoramic ultrasound images (**In-flight teleguided self-ultrasound scanning panoramic imaging protocol**). We first piloted the Tele-SUS protocol with one non-astronaut participant in ISS training module and found that acquisition time was 64 mins (**Table S2**). Scheduling for in-flight Tele-SUS was based on this time. All National Aeronautics and Space Administration (NASA), Canadian Space Agency (CSA), European Space Agency (ESA), and Japan Aerospace Exploration Agency (JAXA) astronauts assigned to an International Space Station (ISS) flight were eligible and self-selected to participate in the study. The study was approved by the Institutional Review Board at NASA Johnson Space Center, the Japan Aerospace Exploration Agency (JAXA) Institutional Review Board, the European Space Agency (ESA) Medical Board, and the Human Research Multilateral Review Board; all participants provided written informed consent before participation in the study. A certified sonographer acquired pre- and post-flight panoramic images as previously described. (Scott et al., 2012; Scott et al., 2017) Approximately 40 days before flight and one day post-flight, B-mode axial-plane ultrasound (GE, Vivid q, Milwaukee, WI) images were acquired with a 9-MHz linear-array probe (50-mm width) in panoramic mode. (Scott et al., 2012; Scott et al., 2017) Depending on participant leg length, one of three thigh and one of three calf guides were used (small, medium, or large). To ensure the ultrasound guide placement was the same at each time point, the placement of the ultrasound guide was measured during the first session and reproduced at subsequent sessions. A consistent, minimal pressure was applied with the probe to the skin to avoid compression of the muscle. No visually identifiable muscle compression could be detected on the scans. Targeted image references for each slice on the ultrasound guide and each muscle were created for each participant using pre-flight images. Axial spin-echo T2-weighted MRI images were acquired from the level of the ankle mortise to the iliac crest while subjects lay supine in a 3-T scanner (Signa Horizon LX, General Electric, USA). Images of the upper and lower leg were collected using a repetition time of 2000 ms, echo time of 51 ms, slice thickness of 10 mm, and a gap between slices of 10 mm. A matrix size of 512 x 512 was used for all scans.

#### *Tele-SUS Protocol and Training*

All participants received approximately 3 hours of ultrasound training as part of standard flight procedures that included general ultrasound principles, appropriate ultrasound probe handling, and "knobology." A six-member Tele-SUS muscle team of sonographers, ultrasound experts, and remote guidance specialists designed a standardized procedure manual (**Transparent Methods**) that consisted of three phases: pre, during, and post ultrasound. All members of the Tele-SUS team completed NASA's Principles of Remote Guidance Training Class and conducted all participant training. A standardized training module consisting of two, 60-minute didactic sessions was delivered to all participants. Training included: (1) measuring placement of ultrasound guides, (2) donning, doffing, and cleaning of the ultrasound guides, (3) techniques for acquiring panoramic muscle images of upper and lower leg, and (4) a full run-through of Tele-SUS protocol in mock ISS.



### *In-Flight Ultrasound Acoustic Medium: Ultrasound Gel versus Water*

Ultrasound gel, an impedance coupling fluid, creates a liquid layer at the probe-skin interface. Without this impedance coupling layer, more than 99% of the ultrasonic energy would be reflected at the probe-air interface thus this coupling fluid is essential in transferring the ultrasound from the probe tip into the tissue and subsequently sensing the returned signal. A wide variety of fluids will work, however, due to gravitational forces in Earth based clinics, common fluids such as water will not remain at the probe-skin interface where they are needed. Ultrasound gels, water-based solutions of high molecular weight polyethylene glycol or methyl cellulose, are thick, sticky, and not only remain in the probe-skin interface but add some degree of lubrication easing the probe movement. With current ultrasound capability on ISS, it was only natural to bring a supply of the Earth-standard ultrasound gel; however, the estimated cost per pound to deliver scientific materials to the ISS was \$8,000 USD.

We hypothesized that due to molecular adhesion in microgravity, water reclaimed from the Water Recovery System (WRS) could be used as an alternative acoustic medium. Water, when placed on skin in microgravity, adheres to that location as an undulating blob. When trapped between the probe-skin interface, water behaves much like ultrasound gel on Earth. Crew working with the mission control diagnostics team established that in microgravity, water alone could be used as an ultrasound impedance coupling fluid and that warm water from the galley dispenser offered a small pleasantry beyond that of cold ultrasound gel. On orbit, the water comes from the WRS. The WRS consists of a Urine Processor Assembly and a Water Processor Assembly. The system was delivered to ISS on STS-126 on November 14, 2008, with the UPA activated on November 20, 2008, and the WPA activated on November 22, 2008. The reclaimed water must meet stringent purity standards before it can be utilized to support the crew, laboratory animals, extravehicular, and payload activities. Regenerative water supply via the galley (75% of water in urine recovered) and is processed through a distillation apparatus, a series of charcoal filters, particulate filters, deionizing resin beds, a catalytic oxidizer, with measured total organic carbon less than 285 ppb (detection limit) and total inorganic carbon of 600 to 650 ppb.

The use of water as an ultrasound impedance coupling fluid allowed clean up with a simple towel, where the evaporative from the towel was reclaimed by the regenerative life support systems. Leg muscle ultrasound imagery where large quantities of impedance coupling medium are required and the cleanup of the ultrasound guide as well as the leg was significantly facilitated by the use of water as the impedance coupling fluid, particularly in an environment where there is no running water, sinks, or drains. Water eliminated the post-data collection discomfort in an environment lacking normal personal hygiene clean up capabilities and reducing the needed launch mass of supplies on orbit.

### *In-flight Tele-SUS*

The Tele-SUS protocol was performed as previously described with 3 major modifications. First, panoramic ultrasound with customized leg guides was used to acquire images (**Fig. 2a-b**). Second, water reclaimed from the Water Recovery System was used as the ultrasound acoustic medium. Finally, we only captured images during Ku-band availability and checked images against pre-flight image references. We repeated acquisition until image quality was sufficiently comparable to image references or acquisition window ended. Panoramic muscle ultrasound images of the right RF, VM, VL, GM, and GL (**Figs. 2a-b**) were acquired approximately monthly during spaceflight. The Tele-SUS protocol was performed as previously described by a ground-based team located at the TSC at NASA's Johnson Space Center Mission Control Center and an astronaut located on the ISS (**Fig 2c**).

The HRF rack containing the Ultrasound System was configured through ground commands by HRF personnel on console in the TSC. The astronaut set up ISS cabin video connection, unstowed and connected the ultrasound and probe, executed the ultrasound power-up sequence, and donned ultrasound guide per written procedures. The Tele-SUS team monitored set-up and participant positioning with cabin video. One-way video from the ISS to the TSC and two-way voice communication depended on Ku-band and S-band satellite availability. Video included cabin video of the participant and direct images from the ultrasound machine. The certified sonographer instructed the participant on probe placement, knobology, and image starting, translation across the muscle, and stopping locations. Tele-SUS was designed to obtain ultrasound images that corresponded to pre-flight data. Accordingly, ultrasound images were only acquired during Ku-band availability and were checked against pre-flight targeted image references. Acquisition was repeated until image quality was sufficiently comparable to target image references or until acquisition window ended. Images were saved, transferred to ISS computer resources, downlinked to the TSC team, and analyzed off-line. The participant doffed, cleaned, and stowed the ultrasound guide, executed the ultrasound power-down sequence, and stowed the ultrasound machine and probe per written procedures. Ultrasound and MRI images from all participants were manually traced and the average of analyzed slices was used to calculate muscle CSA. (Scott et al., 2012) Feasibility was evaluated by the number of Tele-SUS images that were of comparable quality to those obtained by a certified sonographer, number of attempts to obtain quality images, and acquisition time. Characterization of spaceflight-induced change in lower body muscle size, difference in muscle CSA 7 days prior to landing and on landing day, and change in CSA from pre-flight to post-flight in MRI and ultrasound were assessed. We explored the data using descriptive statistics and graphical methods using means and medians and plotting the data to explore longitudinal trends.

# IN-FLIGHT TELEGUIDED SELF-ULTRASOUND SCANNING PANORAMIC IMAGING PROTOCOL

## OBJECTIVE:

Set up camera and video, configure the Ultrasound 2, place reference marks on calf and thigh of right leg, don Sprint (Integrated Resistance and Aerobic Training Study) Thigh and Calf Guides, and perform thigh and calf scans with guidance from the Sprint ground team. After scan is complete, perform data transfer from Ultrasound 2 to Ultrasound 2 USB Drive.

## TOOLS:

Fine Point Sharpie

Short Duration Foot Restraint

## PARTS:

12L-RS Probe

Dry Wipes

HRF Ultrasound Echo Gel (one bottle) Sprint Guide Kit

## NOTE

1. S, Ku, and Video are required during Step 8 (Thigh and Calf Scan) to meet remote guiding requirements. Step 8 begins approximately 45 minutes into this activity.
2. Crew and Ground will coordinate activities to maintain resource availability within the timeline throughout this activity

### 1. CAMERA AND VIDEO SETUP

- 1.1 ✓COL lab video camera (VCA 1or VCA 2) is set up on Multi-Use Bracket so that the FOV will show subject and probe position on subject
- 1.2 Configure restraint device(s) of choice (e.g., foot loops, bungees, straps, etc.) in preparation for maintaining a relaxed 90 degree angle bend of right leg during scan (to be performed later in activity).

### 2. ULTRASOUND2 PROBE INSTALLATION

12L-RS Probe - 103848-001

#### 2.2 Remove Probe Connector Cover.

Ultrasound 2

#### 2.3 ✓Probe Lever on side of Ultrasound 2 is in down position

12L-RS Probe P1 →|← Ultrasound 2 DATA J1 port on side of Ultrasound 2

Place Probe Lever in up position to secure 12L-RS Probe

#### 2.4 Tmpy stow scanhead end of 12L-RS Probe with 12L-RS Scanhead Cover on.

#### 2.5 ✓'12L-RS' is displayed on top of screen next to date and time. If '12L-RS' is not displayed,

Remove probe currently connected to Ultrasound 2.

✓Probe Lever on side of Ultrasound 2 is in down

12L-RS Probe P1 →|← Ultrasound 2 DATA J1 port on side of Ultrasound 2 (

Place Probe Lever in up position to secure 12L-RS Probe

### 3. ULTRASOUND 2 CONFIGURATION

#### NOTE

The 'Set' button on the Ultrasound 2 keyboard (trackball area) is used to select options on the Ultrasound 2 software. Procedures will inform crew when double click of the 'Set' button is required to make a selection.

#### Ultrasound 2

##### 3.1 pb Patient → Press (Pink 1)

If 'OPERATOR LOGIN' window appears, sel USR (from 'Operator' optionsLeave

'Password' section empty (no password required).

sel Log on

##### 3.2 sel Create New Patient/New Exam

##### 3.3 SEARCH/CREATE PATIENT

'Last Name'

Input Crew ID as identified per Execution Note.

pb Create Patient → Press (Purple 3 up)

If the 'Warning!' message 'An exam already exists for this date. Do you want to continue the existing exam?' appears,

√POIC

##### 3.4 √Crew ID is displayed on top left of Ultrasound 2 screen.

If Crew ID is not correct, pb Patient → Press (Pink 1)

sel End Exam

If the 'Warning!' message 'Request to end exam. Are you sure this is what you want to do?' appears, sel Yes

√Crew ID is no longer displayed on top left of Ultrasound 2 screen.

Repeat step\_3.1 to step\_3.4.

##### 3.5 √SPRINT is shown under '12L-RS' at top of Ultrasound 2 screen.

If SPRINT is not shown,~

pb Application → Press (Pink 2)

Probes

sel 12L-RS Applications

sel SPRINT - Msc Skel

If SPRINT- Msc Skel not available,

√POIC

√SPRINT is shown under '12L-RS'.

##### 3.6 √All GAIN slider bars (to right of Ultrasound 2 keyboard) are centered.

#### NOTE

VOX mode is required by operator so that hands are free for simultaneous scanning and keyboard use.

- 3.7 Check VOX configured for sound.
4. THIGH MARKING
  - 4.1 Refer to private message identified in Execution Notes for personal preflight measurements and guide size (message will be referenced throughout this procedure).
  - 4.2 Short Duration Foot Restraint →|← hand rail per crew preference near Ultrasound 2 setup location
  - 4.3 Place right bare foot into Short Duration Foot Restraint.
  - 4.4 Place metal edge of 60" Tape Measure (Sprint Guide Kit) that starts at 0 cm underneath the right foot and position 60" Tape Measure so that the 10 cm mark is facing up and on the edge of the big toe nail
  - 4.5 Place right knee and ankle in a relaxed 90 degree angle.
  - 4.6 While keeping 60" Tape Measure taut, continue measuring from the tip of the big toe, over the patella (knee cap) and place a one cm perpendicular mark on the center of the right thigh at XX.X cm (where 'X' represents measurements from private message) [Fine Point Sharpie]
  - 4.7 While keeping 60" Tape Measure taut, continue measuring from the tip of the big toe, over the patella (knee cap) and mark a parallel line in the center of the right thigh from XX.X cm to YY.Y cm (where 'X' and 'Y' represent measurements from private message) [Fine Point Sharpie]
5. CALF MARKING
  - 5.1 Per crew preference, adjust right foot position so that 60" Tape Measure can be inserted under foot.
  - 5.2 Place metal edge of 60" Tape Measure that starts at 0 cm on top of the right foot and position 60" Tape Measure so that the 10 cm mark is facing up and on the edge of the big toe nail. Continue wrapping 60" Tape Measure under the heel and up to the right calf
  - 5.3 Resecure right foot with wrapped 60" Tape Measure in the Short Duration Foot Restraint.
  - 5.4 Place right knee and ankle in a relaxed 90 degree angle.
  - 5.5 While keeping 60" Tape Measure taut, continue measuring from the tip of the big toe, under the foot and place a one cm perpendicular mark on the center of the right calf at XX.X cm (where 'X' represents measurements from private message) [Fine Point Sharpie]
  - 5.6 While keeping 60" Tape Measure taut, continue measuring from the tip of the big toe, under the foot and mark a parallel line in the center of the right calf from XX.X cm to YY.Y cm (where 'X' and 'Y' represent measurements from private message) [Fine Point Sharpie]
  - 5.7 Remove right bare foot from Short Duration Foot Restraint.
  - 5.8 Stow 60" Tape Measure in Sprint Guide Kit.
6. THIGH GUIDE DONNING
  - 6.1 Unstow Thigh Guide (Large, Medium, or Small, as identified in private message) (in Sprint Guide Kit).
  - 6.2 ✓All four Guide Straps are attached to Thigh Guide on opposite side of buckle  
If all Guide Straps are not attached to Thigh Guide,  
Unstow required number of Guide Straps needed to fill all four slots on Thigh Guide from Sprint Guide Kit.

Insert Guide Strap so that folded edge goes into slot on transparent border on opposite side of Thigh Guide from black buckles.

Repeat as necessary until four Guide Straps are inserted. Notify POIC of number of extra Guide Straps used.

Stage Ziplock Bag(s) from Guide Straps for trash.

- 6.3 If required, run Guide Straps around thigh and attach green end of strap to black buckle located on the opposite side of the Thigh Guide
- 6.4 Loosely position Thigh Guide on right thigh with the orange rubber bumpers down so that the perpendicular mark on the thigh is centered in the reference slot of the Thigh Guide and the parallel line is in the second scanning slice of the guide
- 6.5 Rotate Thigh Guide to the right so that the scanning slice numbers are just visible on the inner thigh (vertical reference mark should remain in the second scanning slice and the horizontal reference mark should remain parallel with the reference slot at the bottom of the Thigh Guide)
- 6.6 Tighten Guide Straps so that Thigh Guide is secure but thigh muscle is not deformed.

## 7. CALF GUIDE DORNING

- 7.1 Unstow Calf Guide (Large, Medium, or Small, as identified in private message) (in Sprint Guide Kit).

- 7.2 ✓ All four Guide Straps are attached to Calf Guide on opposite side of buckle  
If all Guide Straps are not attached to Calf Guide,

Unstow required number of Guide Straps needed to fill all four slots on Calf Guide from Sprint Guide Kit.

Insert Guide Strap so that folded edge goes into slot on transparent border on opposite side of Calf Guide from black buckles.

Repeat as necessary until four Guide Straps are inserted. Notify POIC of number of extra Guide Straps used.

Stage Ziplock Bag(s) from Guide Straps for trash.

- 7.3 If required, run Guide Straps around calf and attach green end of strap to black buckle located on the opposite side of the Calf Guide
- 7.4 Position Calf Guide on back of right calf with the orange rubber bumpers down so that the perpendicular mark on the calf is centered in the reference slot of the Calf Guide and the parallel line is in the seventh scanning slice of the guide

Bottom of the Calf Guide should be tighter than the top as those scanning slices may not be utilized during the scanning activity.

- 7.5 Tighten Guide Straps so that Calf Guide is secure but calf muscle is not deformed.

### NOTE

For crew ease, Sprint Guide Kit and Short Duration Foot Restraint should remain in a near-by Tmpy Stow location for upcoming scanning activity.

- 7.6 Tmpy Stow:  
Short Duration Foot Restraint Sprint Guide Kit
- 7.7 Stow:  
Fine Point Sharpie

## 8. SCANNING ACTIVITY

### CAUTION

1. In order to ensure acceptable data collection, these points must be followed while scanning:
  - a. 12L-RS Probe should be perpendicular to the skin (failure to do so will adversely affect scan's image quality).
  - b. 12L-RS Probe reference marker (raised plastic line) should be oriented to the subject's right (failure to do so will adversely affect scan's image quality).
  - c. 12L-RS Probe should be placed lightly on skin so that the wall of the muscle is not depressed.
2. 60 minutes of S, Ku, and Video are required for the scanning activity because of remote guiding requirements.
  - 8.1 Subject should use restraint device(s) of choice to ensure the right leg is bent at a relaxed 90 degree angle and subject is positioned to reach the Ultrasound 2 keyboard while viewing the Ultrasound 2 screen.

If subject wishes to view their specific Ultrasound images from preflight baseline data collection while scanning,  
See execution note for private OCA message.
  - 8.2 When setup is completed and crew is ready for scanning,  
√POIC (to confirm private video and voice are configured for the real-time remote guidance session with ground team)  
On POIC GO 12L-RS Probe
  - 8.3 Remove 12L-RS Scanhead Cover.

Apply at least 0.5 cm of HRF Ultrasound Echo Gel or water to 12L-RS Probe scanhead, covering entire scanhead length.  
Maintain 0.5 cm of gel or water on scanhead throughout scan.
  - 8.4 Perform scan activities per ground instructions with remote guidance from Sprint team on privatized Space-To-Ground loop.
  - 8.5 √Scan is complete with Remote Guiding Team.

## 9. POST SCANNING ACTIVITY

### Ultrasound 2

9.1 pb Patient → Press (Pink 1)

sel End Exam

If the 'Warning!' message 'Request to end exam. Are you sure this is what you want to do?' appears,

sel Yes

9.2 √Crew ID is no longer displayed on top left of Ultrasound 2 screen.

9.3 Doff Thigh Guide and Calf Guide.

9.4 Clean Thigh Guide and Calf Guide using Dry Wipes.

9.5 Attach green end of strap to black buckle located on the opposite side of the Thigh Guide (to aid in stowage) Repeat for Calf Guide.

### 12L-RS Probe

9.6 Wipe clean scanhead end of 12L-RS Probe [Dry Wipes].

Replace 12L-RS Scanhead Cover.

## Ultrasound 2

- 12L-RS Probe
- 9.7 Place Probe Lever in down position to release 12L-RS Probe (section B of Figure 3).
  - 9.8 12L-RS Probe P1 ←|→ Ultrasound 2 DATA J1 port on side of ultrasound 2.
  - 9.9 Attach Probe Connector Cover to 12L-RS Probe P1.
  - 9.10 Stow in Sprint Guide Kit: Thigh Guide  
Calf Guide
  - 9.11 Stow:  
12L-RS Probe  
HRF Ultrasound Echo Gel  
Sprint Guide Kit  
Short Duration Foot Restraint

### 10. DATA TRANSFER

- 10.1 Go to [2.003 ULTRASOUND 2 DATA EXPORT TO ULTRASOUND 2 USB DRIVE](#)

## Supplemental References

- Arbeille, P., Kerbeci, P., Capri, A., Dannaud, C., Trappe, S.W., and Trappe, T.A. (2009). Quantification of muscle volume by echography: comparison with MRI data on subjects in long-term bed rest. *Ultrasound Med Biol* 35, 1092-1097.
- Bland, J.M., and Altman, D.G. (2007). Agreement between methods of measurement with multiple observations per individual. *J Biopharm Stat* 17, 571-582.
- Carrasco, J.L., and Jover, L. (2003). Estimating the generalized concordance correlation coefficient through variance components. *Biometrics* 59, 849-858.
- Cromwell, R.L., Scott, J.M., Downs, M., Yarbough, P.O., Zanello, S.B., and Ploutz-Snyder, L. (2018). Overview of the NASA 70-day Bed Rest Study. *Med Sci Sports Exerc.*
- Scott, J.M., Martin, D.S., Ploutz-Snyder, R., Caine, T., Matz, T., Arzeno, N.M., Buxton, R., and Ploutz-Snyder, L. (2012). Reliability and validity of panoramic ultrasound for muscle quantification. *Ultrasound Med Biol* 38, 1656-1661.
- Scott, J.M., Martin, D.S., Ploutz-Snyder, R., Matz, T., Caine, T., Downs, M., Hackney, K., Buxton, R., Ryder, J.W., and Ploutz-Snyder, L. (2017). Panoramic ultrasound: a novel and valid tool for monitoring change in muscle mass. *J Cachexia Sarcopenia Muscle* 8, 475-481.
- Sundblad, P., Orlov, O., Angerer, O., Larina, I., and Cromwell, R. (2016). Standardization of bed rest studies in the spaceflight context. *J Appl Physiol* (1985) 121, 348-349.
- Trappe, T.A., Burd, N.A., Louis, E.S., Lee, G.A., and Trappe, S.W. (2007). Influence of concurrent exercise or nutrition countermeasures on thigh and calf muscle size and function during 60 days of bed rest in women. *Acta Physiol (Oxf)* 191, 147-159.