

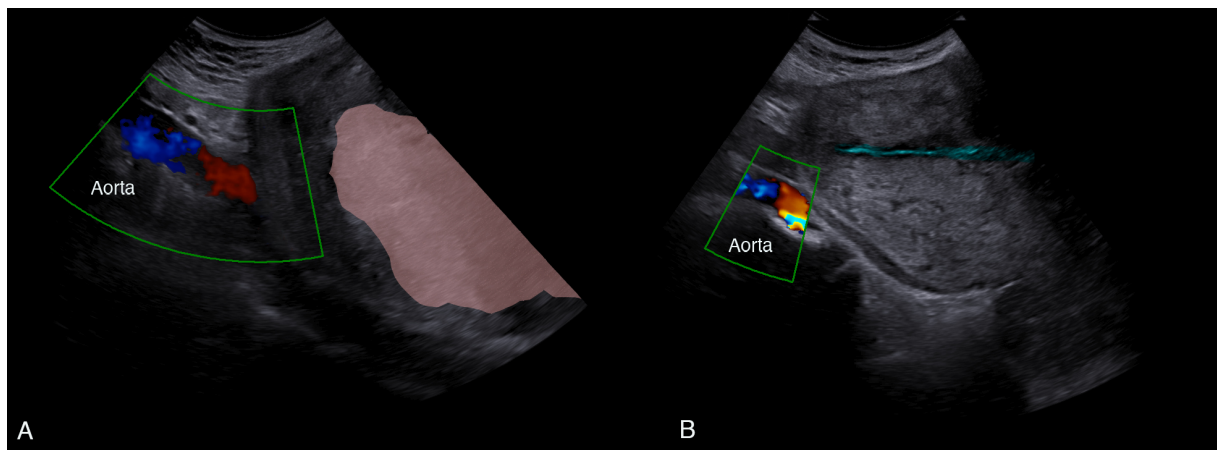
SUPPLEMENTARY INFORMATION

Title: Using shear wave elastography to assess uterine tonicity after vaginal delivery

Joanna SICHITIU MD,¹ Jean-Yves MEUWLY MD,² David BAUD MD-PhD,¹

David DESSEAUVÉ MPH MD PhD¹

Figure S1 Midsagittal view of the uterus



A. Before placental expulsion. B After placental expulsion. Pink outline illustrates the placenta. Blue outline illustrates the uterine cavity.