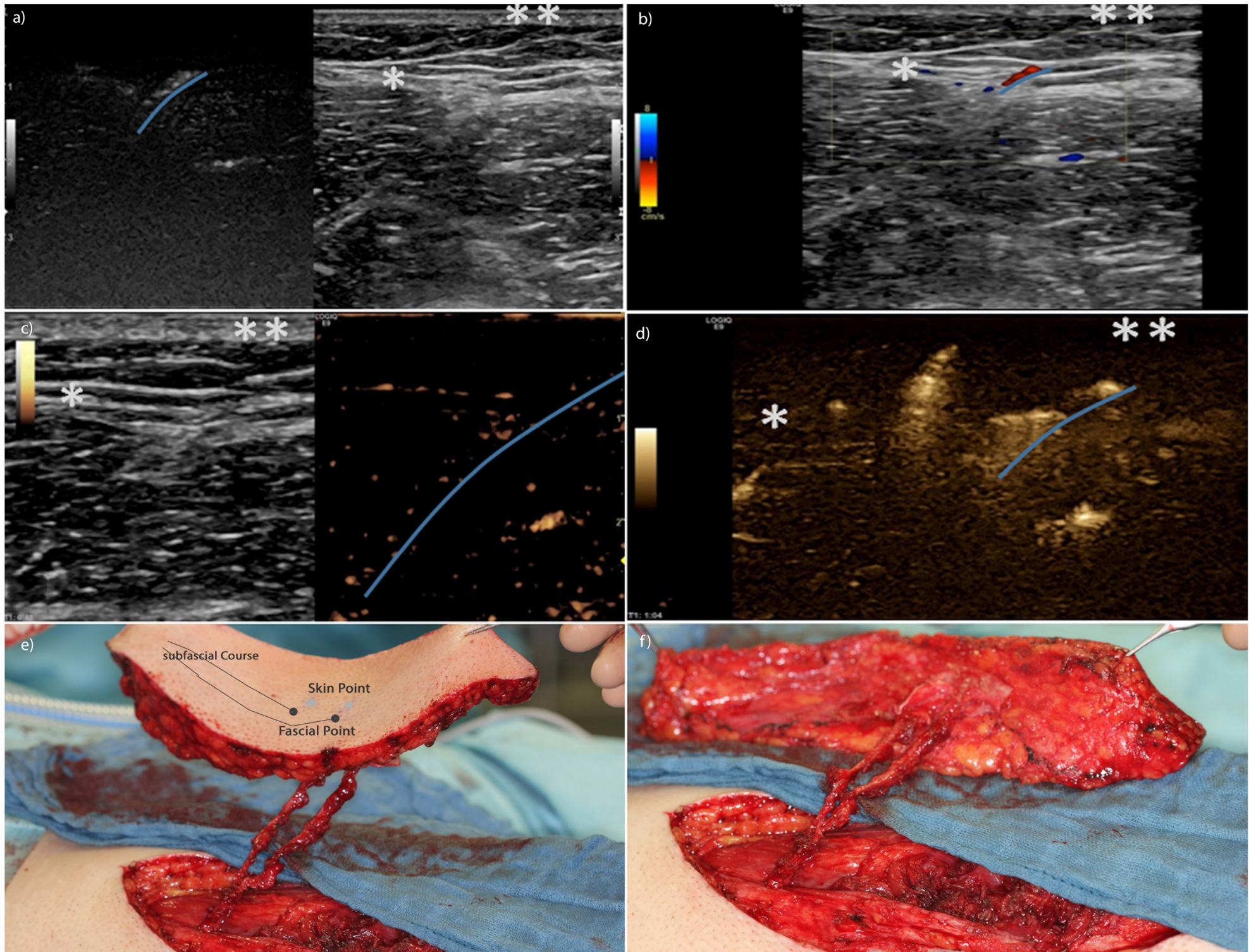


Supplemental Digital Content1:

Figure 2 that illustrates the perforator flaps and the different ultrasound techniques pdf.



Ultrasound images of perforator mapping **a:** Split screen of a non-contrast B-flow image (left) and a morphological B-mode image (right), **b:** Color-coded Doppler imaging displayed as an overlay of a morphological B-mode image, **c:** Split screen of a non-linear contrast-enhanced ultrasound image (right) and a morphological B-mode image (left); **d:** contrast-enhanced B-Flow image: note the optimized visibility of the perforator and its branches, **Blue line:** Delineated course of a sample vessel. \*: fascia, \*\*: cutis  
**e,f:** Intraoperative photograph of an anterior lateral thigh flap with two perforators. The skin point, fascial point, and subfascial course of the perforator are marked.