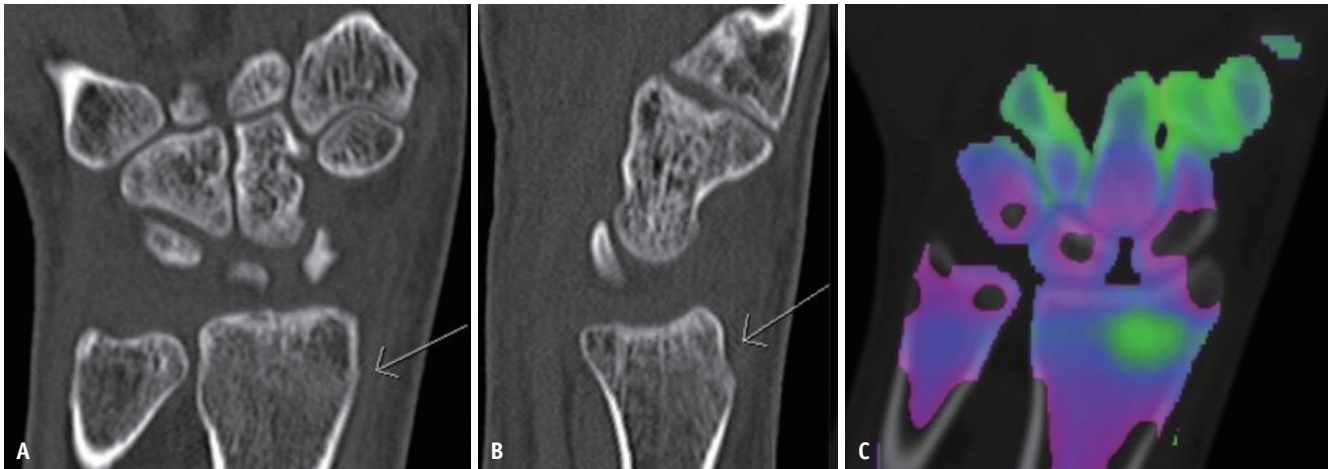


SUPPLEMENT



Supplementary Fig. 1. A 30-year-old female with a history of a fall on an outstretched hand.

A, B. Coronal and sagittal CT images of the wrist show a questionable cortical irregularity (arrows) at the dorsal cortex of the distal radius.
C. Dual-energy CT image with color-coding highlights the marrow edema, with green color-coding corresponding to the area of cortical irregularity, confirming a subtle, nondisplaced buckle fracture of the dorsal aspect of the distal radial metaphysis.