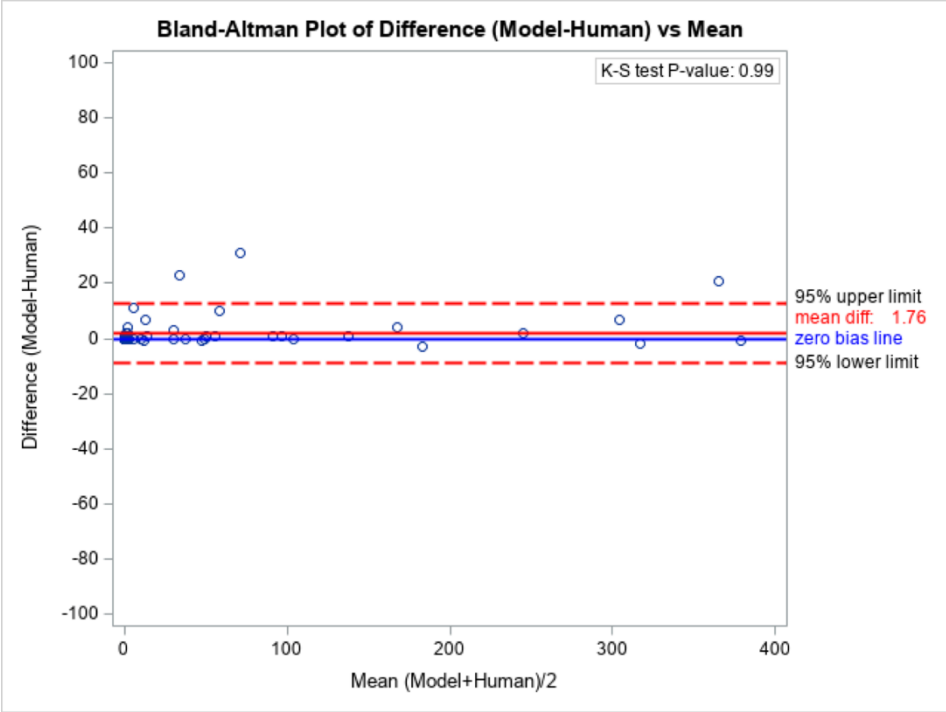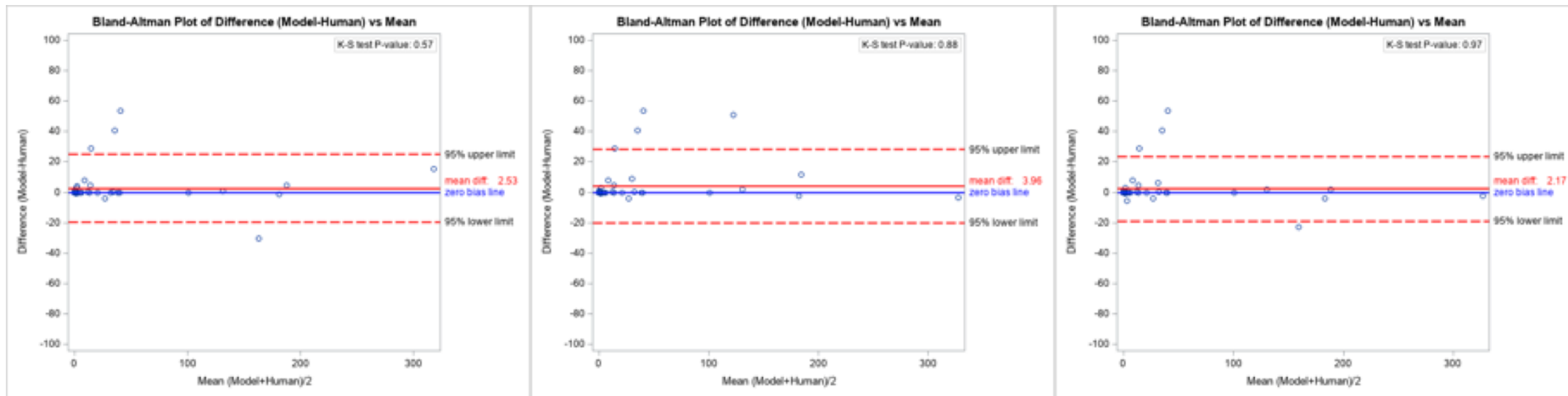
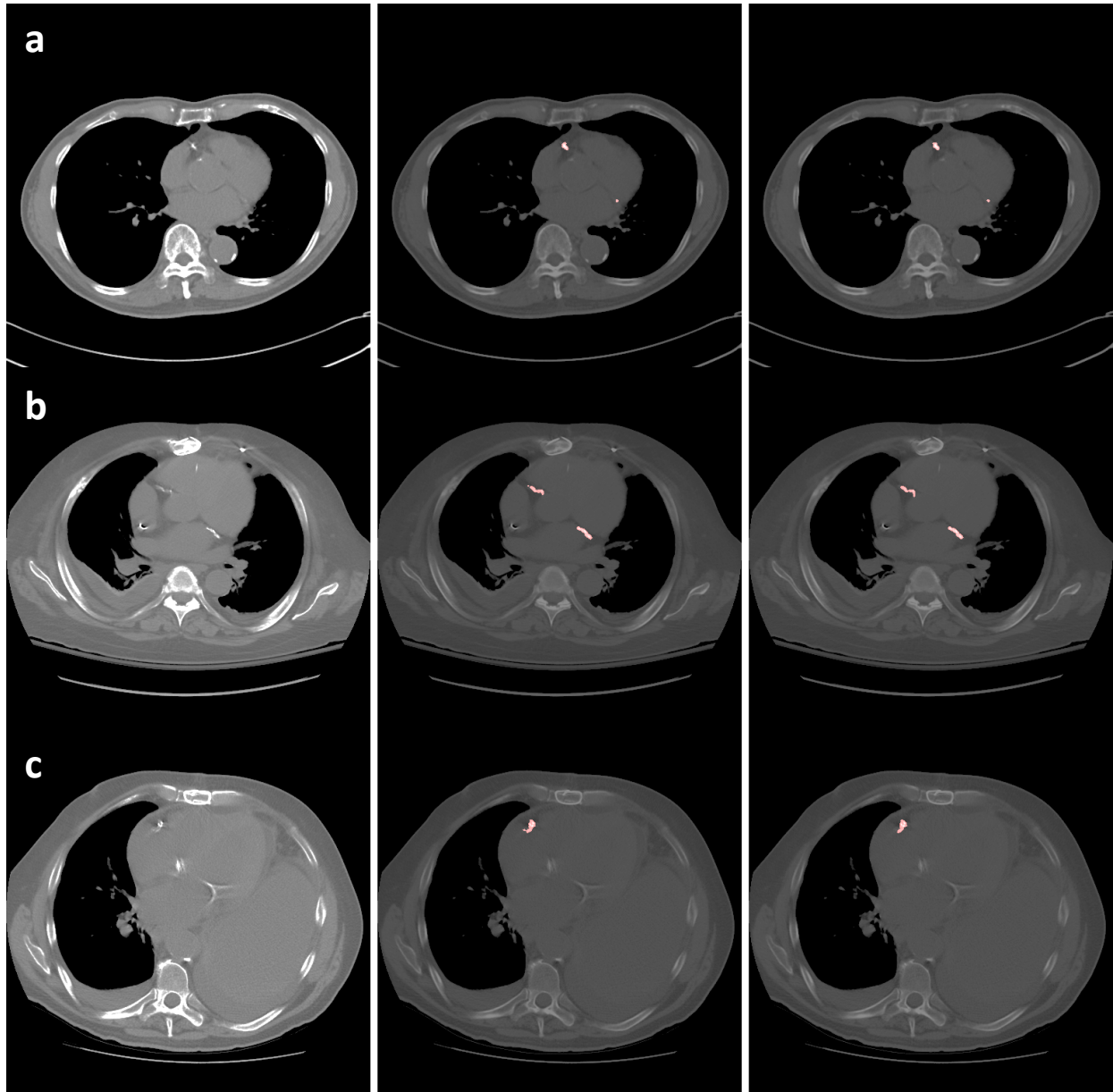


Supplementary Figure 1. Bland-Altman plot comparing automated to manual scoring of CAC on gated coronary CT exams of CAC score ≤ 400 .



Supplementary Figure 2. Bland-Altman plots comparing automated scoring to manual scoring by three different (left, middle, right) technologists on gated coronary CT exams of CAC scores ≤ 400 .



Supplementary Figure 3. Coronary artery segmentation (reference image on left, manual in middle; automated on right) in three different patients (rows). Row a shows aortic root calcification (short arrow) and descending aortic calcification (long arrow) that are not inadvertently picked up by the model as coronary calcium. Row b shows the caudal tip of a central venous line (arrow) that is not mistakenly picked up by the model as CAC. Row c is an example of mitral valve calcification (arrow) not inadvertently picked up by the model as CAC.