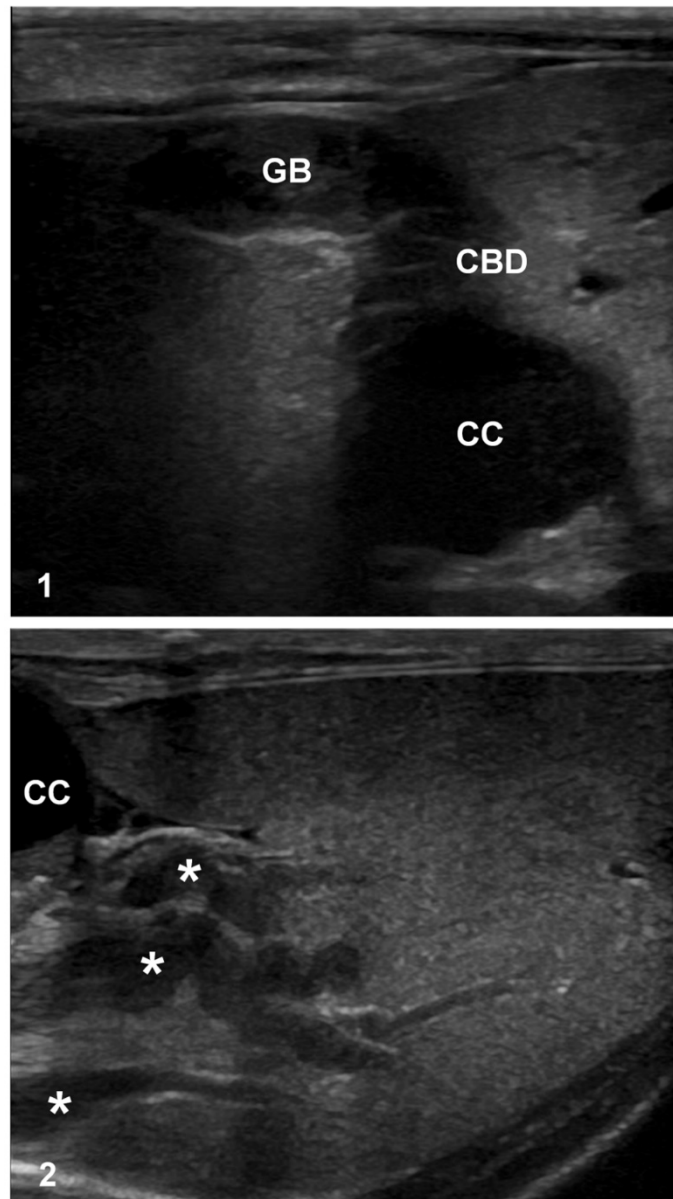


JVDI: Supplementary material

Schreeg ME, et al. Choledochal cyst with secondary cholangitis, choledochitis, duodenal papillitis, and pancreatitis in a young domestic shorthair cat



**Supplementary Figures 1, 2.** Abdominal ultrasound of feline choledochal cyst (CC).

**Supplementary Figure 1.** The gallbladder (GB) is distended and filled with abundant gravity-dependent echogenic debris. The common bile duct (CBD) extends from the gallbladder and merges with a large, cystic, anechoic structure (CC). **Supplementary Figure 2.** Extending from the CC into the liver are several markedly dilated and tortuous intrahepatic bile ducts (asterisks).