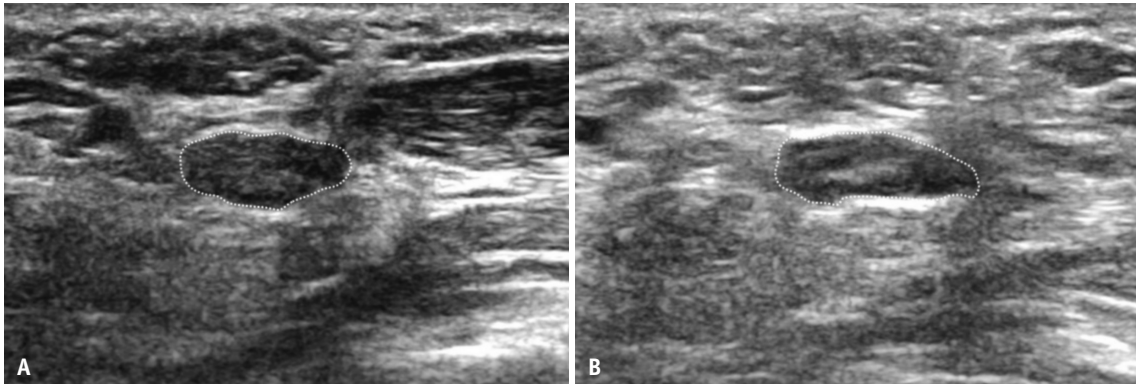


SUPPLEMENT



Supplementary Fig. 1. Transverse ultrasound of the same patient as figure 1 shows the median nerve distal to the carpal tunnel at baseline (A) and 12 months (B) post-endoscopic carpal tunnel release. Median nerve cross sectional areas (dotted lines) at baseline (25.3 mm²) and 12 months (27.0 mm²) are similar.