

1
2
3
4
5
6
7
8
9
10
11
12
13
14
15

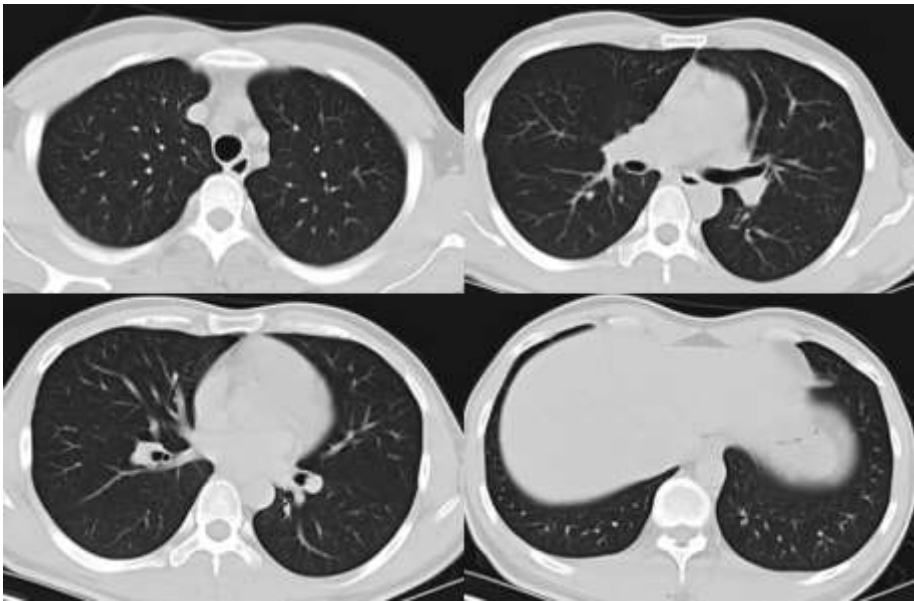


Figure 1. Chest CT on the day the patient orally took diquat.

16
17
18
19
20
21
22
23
24
25
26
27
28
29
30
31
32
33
34
35
36

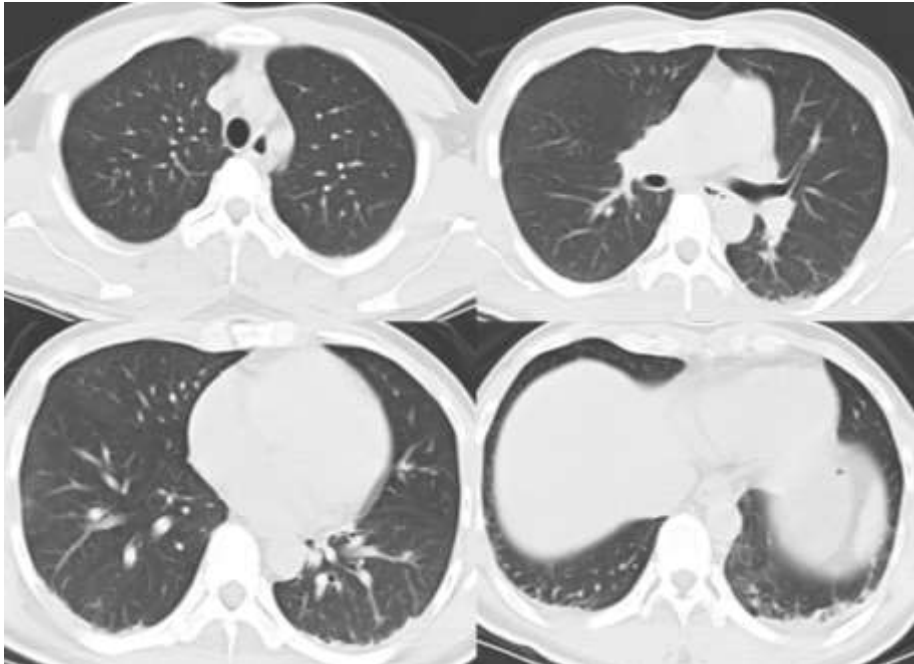


Figure 2. Chest CT on third day after the patient orally took diquat. The first day when the patient came to ICU (Day 1)

37
38
39

40
41
42
43
44
45
46
47
48
49
50
51
52
53
54
55
56
57
58
59
60
61
62
63
64
65
66
67
68
69
70
71
72
73
74
75
76
77
78
79
80
81
82
83

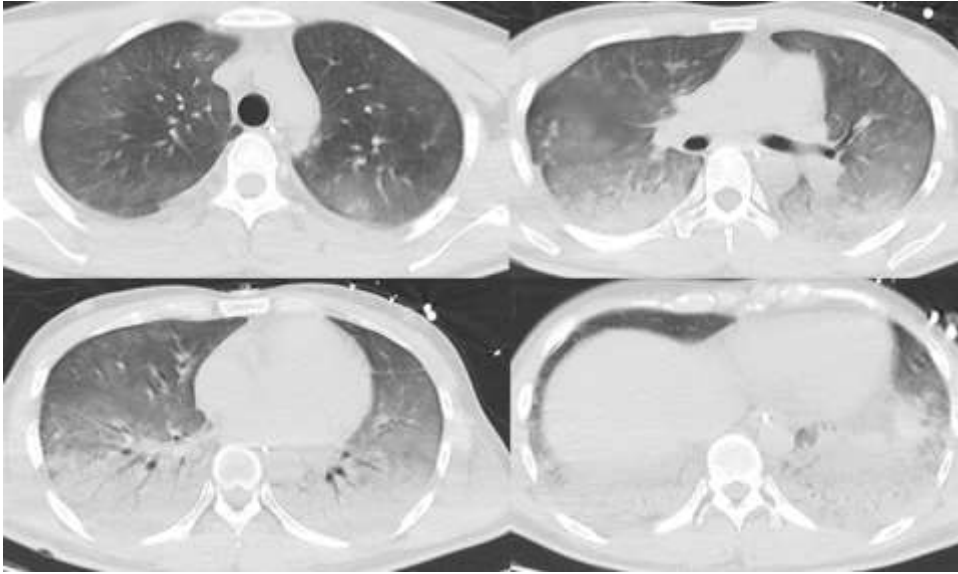


Figure 3. Chest CT on the third day after the patient came to ICU (Day 3)

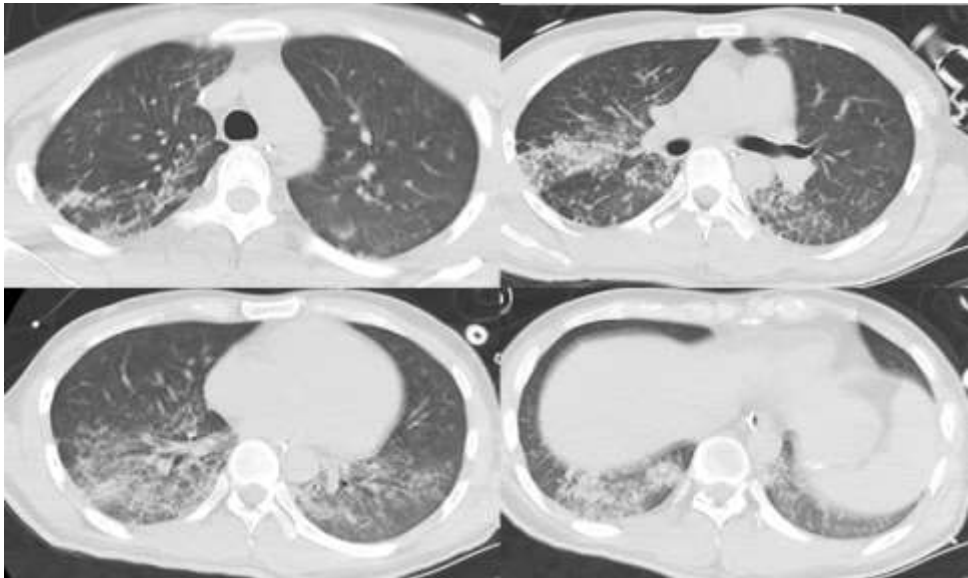


Figure 4. Chest CT on the sixth day after the patient came to ICU (Day 6)

84
85
86
87
88
89
90
91
92
93
94
95
96
97
98
99
100
101
102
103
104
105
106

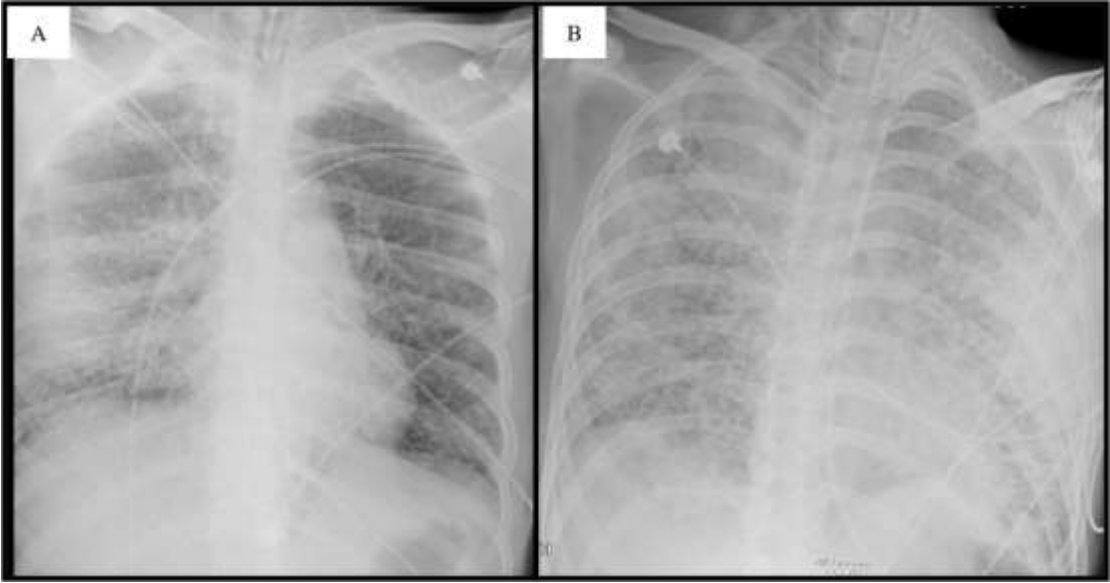


Figure 5. Chest radiograph on the tenth day (A) and eleventh day (B) after the patient came to ICU