

Supplemental Figure for:  
Histiocytic and dendritic cell sarcomas of hematopoietic origin share targetable genomic alterations distinct from follicular dendritic cell sarcoma Lucas R Massoth et al.

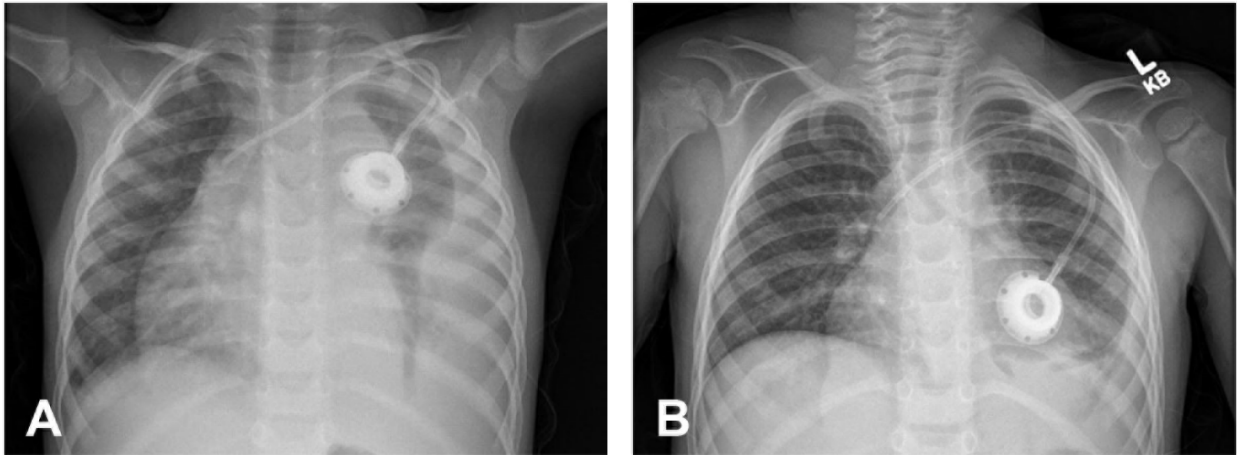


Figure S1. Illustrative patient case radiologic studies prior to and one month after temsirolimus treatment. Chest X-ray at second relapse, prior to initiation of temsirolimus, with consolidation of the left pleural cavity (A). After one month of targeted therapy, a sequential chest X-ray shows marked improvement (B).