

MR Demonstration of Spinal Cord Sarcoidosis: Report of a Case

Richard B. Kelly,¹ Patrick D. Mahoney,¹ and Kevin M. Cawley²

Sarcoidosis is an idiopathic, multisystem, granulomatous disease characterized microscopically by the presence of noncaseating granulomas and, in the majority of cases, supportive laboratory and clinical findings. The CNS is clinically involved in approximately 5% of cases [1], although autopsy findings suggest an overall involvement of closer to 15% [2]. The CNS is the sole site of involvement in 1.5% of cases [3]. The most frequently affected portions of the CNS are the basal leptomeninges, cranial nerves (particularly VII and II), hypothalamus, and pituitary gland; the brainstem and spinal cord are rarely involved [1]. Hydrocephalus secondary to basal arachnoiditis is the most common CNS abnormality detected radiographically, although contrast-enhancing mass lesions produced by coalescent granulomata have occasionally been demonstrated with CT [2-7].

Only one previous report [8] has described MR findings in a case of suspected neurosarcoidosis. We report a second case with MR findings in which histologically confirmed neurosarcoidosis involved the brainstem and spinal cord.

Case Report

A 52-year-old previously healthy woman presented with complaints of a tingling sensation and pain in her neck and all four extremities of several months' duration. Her symptoms had begun in both feet but progressed to involve the upper extremities, shoulders, and neck. The main finding on physical examination was extreme pain and limitation of motion of the cervical spine. Evaluation of the cranial nerves including a funduscopic examination was normal. There were no detectable motor or sensory deficits. Deep tendon reflexes were unremarkable. No pathologic reflexes were elicited. An electromyogram and initial laboratory studies were normal. Clinically, a mass lesion of the posterior fossa or craniocervical junction was suspected.

CT examination of the head was normal. A cervical myelogram revealed a fusiform intramedullary enlargement of the cervical spinal cord extending from C4 to C7, with the maximum width reaching approximately 3 cm (Fig. 1). Examination of the CSF obtained during myelography revealed a mild pleocytosis of predominantly lymphocytes and monocytes. Protein was elevated at 159 mg/dl (N = 15-45 mg/dl). Glucose was somewhat low at 47 mg/dl, although a simultaneous glucose was not obtained. A VDRL was negative.

MR imaging was performed with a 1.5-T superconducting magnet system operating at 0.5 T. Images of the cervical spine were obtained at 5-mm intervals in the sagittal plane using both spine and body coils. T1-weighted images demonstrated only widening of the cervical cord. T2-weighted images, however, revealed a diffuse increase in signal intensity extending from the lower medulla to approximately D3 (Figs. 2 and 3). This was thought to most likely represent infiltrating glioma.

Because of the MR findings only a limited operative procedure was attempted. A decompressive laminectomy was performed from C3 through C6. The dura appeared normal. The spinal cord was grayish, gritty, and widened from C3 through C6. The cord was biopsied in this area with a frozen-section diagnosis of astrocytoma. As no tissue planes could be established for resection, the procedure was terminated.

Subsequent pathologic examination of the biopsy specimens revealed areas of perivascular fibrosis with a chronic inflammatory response and multiple noncaseating granulomas consistent with sarcoidosis. There was no evidence of neoplasm. Stains and cultures for bacteria, acid-fast bacilli, and fungi were negative. Serum fungal antibody titers and CSF examination for fungal antigens were negative.

Further evaluation for supportive systemic evidence of sarcoidosis was unsuccessful. The chest X-ray was normal except for several small calcified left suprahilar lymph nodes. Serum levels of calcium and angiotensin-converting enzyme were normal. Liver and renal function studies were unremarkable. The patient was anergic to tuberculin but did respond to mumps. The Kveim test was not done.

Postoperatively, the patient did well with resolution of most of her symptoms although she did continue to complain of some residual stiffness in her shoulders. Because of the diagnosis of sarcoidosis she was treated with a short course of high-dose corticosteroids. In the 6 months since her surgery and steroid therapy she has had no return of her previous symptoms.

Discussion

Although the CNS is affected in up to 15% of patients with sarcoidosis at autopsy, involvement of the brainstem or spinal cord is rare. A recent review of the literature by Hitchon et al. [9] revealed only 24 previous histologically confirmed cases of spinal cord sarcoidosis. An intramedullary mass lesion is

Received December 27, 1985; accepted after revision April 6, 1986.

¹ Department of Radiology, Creighton University School of Medicine, 601 N. 30th St., Omaha, NE 68131. Address reprint requests to P. D. Mahoney.

² Magnetic Imaging Center, 7911 W. Center Rd., Omaha, NE 68124.

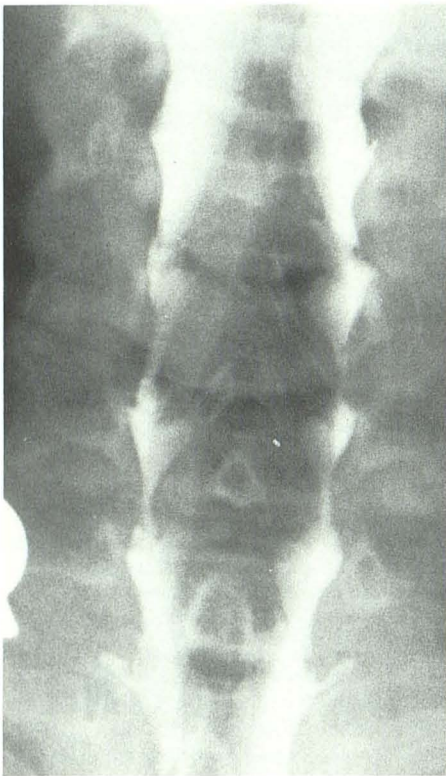

Fig. 1.—Cervical myelogram shows enlargement of spinal cord extending from C4 to C7.

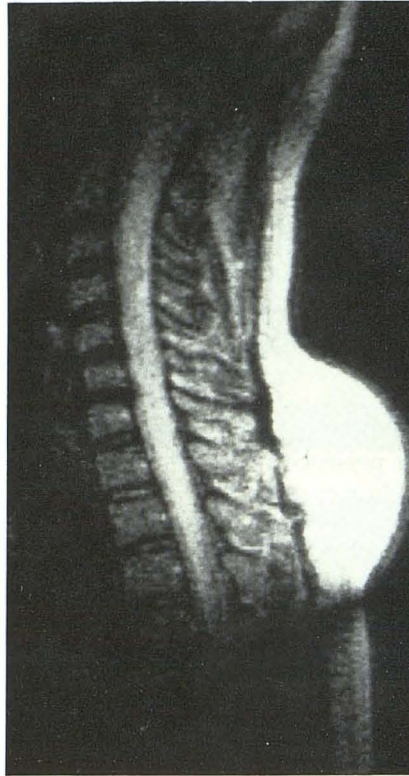

Fig. 2.—Spin-echo T2-weighted MR image (TE 100, TR 1700) using a spine coil shows diffuse increase in signal throughout enlarged spinal cord. Spin-echo T1-weighted images (TE 35, TR 600) revealed only cord enlargement.

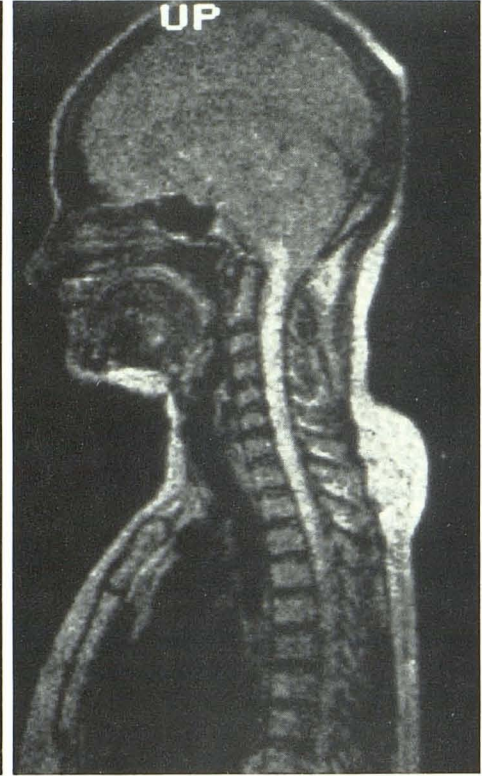


Fig. 3.—T2-weighted MR image (TE 70, TR 1700) with body coil shows lower extent of lesion more accurately. Prominent posterior fat collection was positional. The patient had not previously received exogenous steroids.

the most common presentation; however, the entire spectrum of cord involvement has been described, including arachnoiditis, intradural-extramedullary, and extradural lesions [2, 9–15]. Diagnosis is dependent on biopsy but the possibility of neurosarcoidosis should be considered in a patient with known sarcoidosis or in a patient with other signs of the disease. Response to steroids, the treatment of choice, is variable. Intramedullary lesions have a less favorable prognosis than do the other forms of cord involvement.

Our search of the literature failed to reveal any previous report of MR findings in a histologically proved case of neurosarcoidosis. In a case reported by Poole [8] with MR findings attributed to neurosarcoidosis, a normal CT scan of the head with a high-resolution CT preceded MR demonstration of high T2-signal lesions in the cerebral periaqueductal region in a patient with known systemic sarcoidosis and Argyll Robertson pupils. These lesions were thought to be secondary to neurosarcoidosis but were not biopsied. The finding in our case of a diffuse, increased T2 signal in an expansile intramedullary lesion of the brainstem and spinal cord is of course nonspecific, and differentiation from a glioma or other soft-tissue process would not be possible on the basis of MR findings alone. However, MR did allow accurate differentiation from several other considerations, including syrinx, arteriovenous malformation, and lipoma. In addition, MR more ac-

curately defined the extent of the lesion than did myelography. The finding that a diffuse infiltrating process extended from the lower medulla to the upper thoracic cord led to the decision to only biopsy the lesion rather than attempt a resection. This was perhaps fortunate, since previous reports suggest that attempts to resect spinal cord sarcoidosis are associated with greater morbidity and mortality than is treatment with steroids alone.

Since its introduction MR has established itself as the imaging method of choice in evaluating the spinal cord and certain diseases, such as multiple sclerosis, that also affect the brain. The findings in these two preliminary case reports of neurosarcoidosis suggest that in the future MR may play an important role in the evaluation of patients with sarcoidosis and neurologic complaints. MR is probably more sensitive—and in some areas more specific—than conventional techniques, and it also offers the advantages of noninvasiveness, absence of ionizing radiation and use of contrast media, and the potential to follow the patient's response to therapy.

REFERENCES

1. Delaney P. Neurologic manifestations in sarcoidosis. *Ann Intern Med* 1977;87:336–345
2. Brooks BS, El Gammal T, Hungerford GD, Acker J, Trevor RP, Russel W.

- Radiologic evaluation of neurosarcoidosis: role of computed tomography. *AJNR* **1982**;3:513-521
3. Kumpe DA, Krishna Rao CVG, Garcia JH, Heck AF. Intracranial neurosarcoidosis. *J Comput Assist Tomogr* **1979**;3:324-330
 4. Brooks J Jr, Strickland MC, Williams JP, Vulpe M, Fowler HL. Computed tomography changes in neurosarcoidosis clearing with steroid treatment. *J Comput Assist Tomogr* **1979**;3:398-399
 5. Bahr AL, Krumholz A, Kristd D, Hodges FJ. Neuroradiological manifestations of intracranial sarcoidosis. *Radiology* **1978**;127:713-717
 6. Babu VS, Eisen H, Pataki K. Sarcoidosis of the central nervous system. *J Comput Assist Tomogr* **1979**;3:396-397
 7. Post MJD, Quencer RM, Rabei SZ. CT demonstration of sarcoidosis of the optic nerve, frontal lobes, and falx cerebri: case report and literature review. *AJNR* **1982**;3:523-526
 8. Poole CJM. Argyll Robertson pupils due to neurosarcoidosis: evidence for site of lesion. *Br Med J [Clin Res]* **1984**;289:356
 9. Hitchon PW, Ul Haque A, Olson JJ, Jacobs SK, Olson SP. Sarcoidosis presenting as an intramedullary spinal cord mass. *Neurosurgery* **1984**;15:86-90
 10. Bernstein J, Rival J. Sarcoidosis of the spinal cord as the presenting manifestation of the disease. *South Med J* **1978**;71:1571-1573
 11. Snyder R, Towfigh J, Gonatas NK. Sarcoidosis of the spinal cord. *J Neurosurg* **1976**;44:740-743
 12. Kirks DR, Newton TH. Sarcoidosis; a rare cause of spinal cord widening. *Radiology* **1972**;102:643
 13. Semins H, Nugent GR, Chou SM. Intramedullary spinal cord sarcoidosis. *J Neurosurg* **1972**;37:233-236
 14. Wood EH, Brea CA. Spinal sarcoidosis. *Radiology* **1959**;73:226-233
 15. Banarjee T, Hunt WE. Spinal cord sarcoidosis. *J Neurosurg* **1972**;36:490-493