

Ectopia of the Posterior Pituitary Gland as a Normal Variant: Assessment with MR Imaging

Ericha R. Benschoff¹ and Barry H. Katz

Ectopia of the posterior lobe of the pituitary gland as demonstrated by MR imaging has been described previously in patients with pituitary dwarfism [1], transection of the pituitary infundibulum [2], and compression or destruction of the posterior lobe of the pituitary [3]. We report two patients in whom MR imaging revealed ectopic posterior pituitary glands, even though both patients had normal pituitary function and otherwise normal MR imaging studies. The studies were performed on a GE Signa 1.5-T unit, and multiplanar spin-echo pulse sequences were utilized. We propose that the demonstration of posterior pituitary ectopia on MR may be a normal variant.

Case Reports

Case 1

A 22-year-old woman was referred to our institution for evaluation of migraine headaches. MR studies from an outside institution 13 and 20 months prior to presentation had shown a "stable lesion" in the region of the median eminence of the hypothalamus. Physical examination at presentation was unremarkable. A baseline endocrinologic evaluation, including TSH, T4, prolactin, and plasma cortisol levels was normal. There were no signs or symptoms of posterior pituitary dysfunction, and further evaluation was not indicated clinically. A repeat MR scan of the brain was performed. The study included T1-weighted images (600/20/2, TR/TE/excitations) in the sagittal plane, proton-density-weighted (2500/40/1) and T2-weighted (2500/80/1) images in the axial plane, and T1-weighted images (600/20/4) in the coronal plane. Slice thickness was 3 mm in the latter series and 5 mm in the other series. T1-weighted images showed two areas of high signal intensity, one in the superior portion of the infundibulum and one in the tuber cinereum (Figs. 1A and 1B). These findings were unchanged from the patient's prior MR results. On proton-density-weighted images, signal in these regions diminished but remained bright (Fig. 1C). On T2-weighted images, the high signal of the CSF in the suprasellar cistern obscured visualization of the ectopic pituitary tissue. However, we feel that chemical shift artifact was probably seen in the region of the hypothalamus on the T2-weighted image (Fig. 1D). The high signal commonly present in the normal position of the posterior lobe of the pituitary gland was absent. No other abnormalities were demonstrated.

Case 2

A 15-year-old boy presented for evaluation of intermittent headache and one episode of temporary left-sided visual loss. He had no other complaints, and his history was one of normal growth and development. Physical examination at the time of presentation was normal: there were no signs or symptoms of endocrinologic dysfunction. Although further evaluation was not clinically indicated, to further evaluate the patient's headaches, an MR scan of the brain was obtained. The study included T1-weighted images (600/20/4) in the sagittal plane and proton-density-weighted (2500/30/1) and T2-weighted (2500/80/1) images in the axial plane. Slice thickness was 5 mm for all scans. The T1-weighted images demonstrated a focus of high signal intensity in the region of the median eminence (Fig. 2A). On the proton-density-weighted image this signal diminished in intensity but remained brighter than the signal from fat within the marrow of the dorsum and clivus (Fig. 2B). High signal was not present in the normal location of the posterior lobe of the pituitary gland. No other abnormalities were seen.

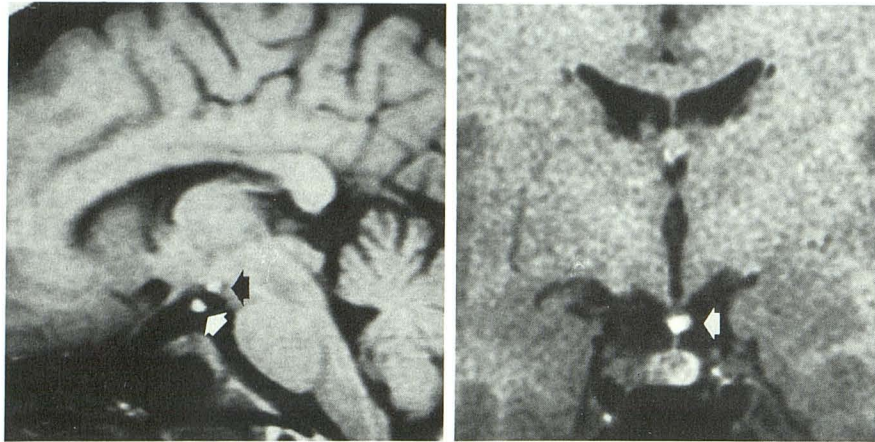
Discussion

With the evolution of MR imaging, the ability to image the pituitary gland has improved dramatically. The appearance of the normal pituitary on various MR sequences has been well defined [4-6]. Nishimura et al. [4], Fujisawa et al. [5], and Colombo et al. [6] found the posterior lobe to be a round or oval area of high signal intensity in the posterior aspect of the sella on T1-weighted images. This could usually be distinguished readily from the bright signal of fat within the marrow of the dorsum and clivus. On proton-density-weighted images the signal of the posterior lobe remained bright and was higher than the signal of the fatty marrow of the dorsum and clivus [5]. On T2-weighted images the signal of the posterior lobe was less intense but still higher than the signal of the dorsum and clivus [5].

The normal pituitary gland develops from the fusion of an upgrowth from the ectoderm of the stomodeum and a downgrowth from the neuroectoderm of the diencephalon. These tissues respectively form the anterior and posterior lobes of the gland [7]. The supraoptic and paraventricular nuclei of the hypothalamus secrete the hormones ADH and oxytocin. These hormones are bound to neurophysin, a carrier protein,

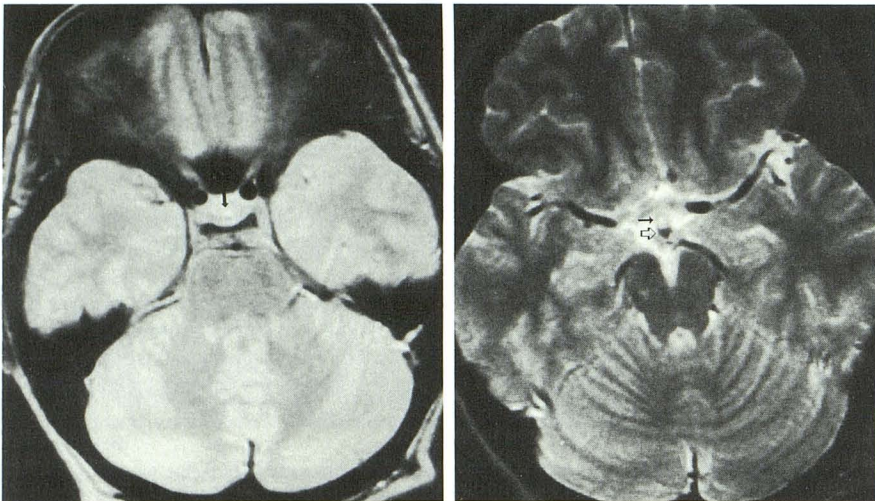
Received June 5, 1989; revision requested August 2, 1989; revision received August 21, 1989; accepted August 29, 1989.

¹ Both authors: Department of Radiology, The Reading Hospital and Medical Center, Reading, PA 19603. Address reprint requests to E. R. Benschoff.



A

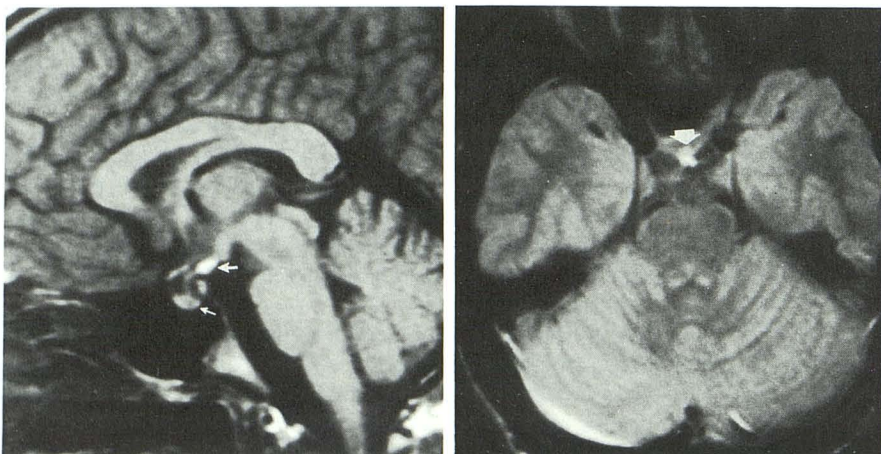
B



C

D

Fig. 1.—Case 1: Ectopic posterior pituitary.
A, Sagittal T1-weighted image shows two areas of high signal intensity, one in superior aspect of infundibulum (*white arrow*) and one in tuber cinereum, just anterior to mamillary bodies (*black arrow*).
B, Coronal T1-weighted image shows high signal intensity in superior aspect of infundibulum (*arrow*).
C, Axial proton-density-weighted image shows area of high signal in hypothalamus (*arrow*).
D, Axial T2-weighted image shows probable chemical shift artifact in region of hypothalamus, with the water signal (*closed arrow*) being displaced anteriorly with respect to the fat signal (*open arrow*).



A

B

Fig. 2.—Case 2: Ectopic posterior pituitary.
A, Sagittal T1-weighted image shows high signal intensity in region of median eminence of hypothalamus (*large arrow*). Note absence of high signal normally present in posterior aspect of pituitary gland (*small arrow*).
B, Axial proton-density-weighted image shows high signal in region of hypothalamus (*arrow*).

and travel via the hypothalamohypophyseal tract to the neurohypophysis, where they are released [8]. Although still controversial, it is believed that the bright signal from the posterior lobe of the pituitary is intimately related to the

presence of these hormones. Some have attributed this signal directly to the ADH/neurophysin complex [5, 9]. Kelly et al. [1] proposed that the bright signal arose from the intracellular lipid of pituicytes. Kucharczyk et al. [10] used lipid-specific

markers to demonstrate that the posterior lobe in dogs had a high lipid content, and using pharmacologic manipulations known to increase plasma ADH levels, they demonstrated an increase in lipid droplets in the posterior lobe pituicytes of cats. It may be the nature and/or amount of this lipid content that gives the posterior lobe of the pituitary signal characteristics similar although not identical to those of fat within the marrow of the dorsum and clivus. The presence of cellular red marrow as well as fatty yellow marrow probably also contributes to the slight difference in signal characteristics between the fat in marrow and the lipid-rich posterior pituitary tissue.

MR signal intensities in the region of the median eminence characteristic of the posterior lobe of the pituitary and absence of normal signal in the usual position of the posterior pituitary lobe have been reported previously in a variety of pathologic conditions. Kelly et al. [1] described a series of pituitary dwarfs who demonstrated solitary nodules at the median eminence with MR signal characteristics of the posterior lobe of the pituitary gland; these patients also had absence of the normal bright signal expected in the normal location of the posterior lobe of the pituitary. They proposed that a perinatal event, possibly vascular in nature, interrupted normal development of both anterior and posterior pituitary pathways. Fujisawa et al. [9] failed to detect the normal high signal of the posterior lobe of the pituitary gland in five adult patients with diabetes insipidus, and Gudinchet et al. [11] failed to detect this high signal in 13 children with diabetes insipidus. These authors suggested that the characteristic signal of the posterior lobe of the pituitary may be related to its functional integrity. El Gammal et al. [3] described an aberrant location of the posterior pituitary bright signal in a series of patients with sellar or parasellar tumors; the native posterior pituitary in this group was compressed or destroyed by tumor, surgery, or hemorrhage. These findings suggest that an ectopic posterior pituitary may form in response to an insult to the hypothalamohypophyseal tract. In the rat, Billenstein and Leveque [12] demonstrated formation of ectopic posterior pituitary tissue in the proximal end of the severed infundibulum following hypophysectomy. An autopsy series demonstrated similar findings in humans after transection of the infundibulum [13]. Fujisawa et al. [2] reported the MR findings in a group of patients who had previously undergone transection of the pituitary infundibulum. In all patients, the bright signal normally seen in the posterior lobe of the pituitary was absent, while in most of these patients a bright region with signal characteristics of the posterior lobe of the pituitary was demonstrated in the proximal end of the transected stalk.

Adequate posterior pituitary function has been demonstrated in some patients after an insult to the hypothalamohypophyseal tract and the development on MR of what is thought to be an ectopic posterior pituitary [2]. In both our patients, MR imaging demonstrated areas in the region of the median eminence that had signal intensities characteristic of the posterior lobe of the pituitary (Figs. 1 and 2). Both patients also had absence of the increased signal intensity normally seen in the posterior aspect of the sella turcica. Our experience supports the contention that the signal in the region of the median eminence represents ectopic posterior pituitary

tissue that functions normally. Both patients demonstrated the characteristic MR findings of ectopic posterior pituitary, while neither had clinical evidence of posterior pituitary dysfunction. In our first case, the presence of two areas of abnormal signal could represent two sites of ectopic gland in the hypothalamohypophyseal pathway. A less likely possibility would include a midline lipoma or dermoid in the hypothalamus in conjunction with ectopic posterior pituitary in the infundibulum.

The likely presence of chemical shift artifact in our first case (Fig. 1D) is interesting. This artifact has not, to our knowledge, been previously described with either ectopic or normally located posterior pituitary tissue. Using a sellar phantom, Nishimura et al. [4] concluded that chemical shift artifact is not seen with normally located posterior pituitary tissue. However, the close apposition of ectopic posterior pituitary tissue within the hypothalamus to the suprasellar cistern could provide a better fat-fluid interface than is present in the sella and could result in prominent chemical shift artifact. Furthermore, the in vitro environment studies by Nishimura et al. [4] may not closely approximate the rather complex in vivo environment of the sellar region, where fat in posterior pituicytes is juxtaposed with soft tissue in the anterior lobe, cortical bone, medullary bone, and CSF.

While our patients had no known insult to the infundibulum, it is possible that a subclinical ischemic event occurred, perhaps in utero, that disrupted the hypothalamohypophyseal tract. We suggest that this resulted in the formation of an ectopic posterior pituitary gland that maintains normal posterior pituitary function. Alternatively, we propose that ectopic posterior pituitary tissue may represent a normal variant, without any underlying pathologic basis.

Although most ectopic posterior pituitary glands demonstrated by MR reported to date have had an underlying anatomic or physiologic origin, we suspect that an increasing number of endocrinologically normal patients will have this finding as the number of MR studies continues to proliferate. We believe that this is a normal variant that does not require any further followup. The true frequency of ectopic posterior pituitary in otherwise normal patients is unknown and requires further study.

REFERENCES

1. Kelly WM, Kucharczyk W, Kucharczyk J, et al. Posterior pituitary ectopia: an MR feature of pituitary dwarfism. *AJNR* 1988;9:453-460
2. Fujisawa I, Kikuchi K, Nishimura K, et al. Transection of the pituitary stalk: development of an ectopic posterior lobe assessed with MR imaging. *Radiology* 1987;165:487-489
3. El Gammal T, Brooks BS, Hoffman WH. MR imaging of the ectopic bright signal of posterior pituitary regeneration. *AJNR* 1989;10:323-328
4. Nishimura K, Fujisawa I, Togashi K, et al. Posterior lobe of the pituitary: identification by lack of chemical shift artifact. *J Comput Assist Tomogr* 1986;10:899-902
5. Fujisawa I, Asato R, Nishimura K, et al. Anterior and posterior lobes of the pituitary gland: assessment by 1.5 T MR imaging. *J Comput Assist Tomogr* 1987;11:214-220
6. Colombo N, Berry I, Kucharczyk J, et al. Posterior pituitary gland: appearance on MR images in normal and pathologic states. *Radiology* 1987;165:481-485
7. Moore KL. *The developing human*. Philadelphia: Saunders, 1982:

- 396-398
8. Nolte J. *The human brain*. St. Louis: Mosby, 1981:180-186
 9. Fujisawa I, Nishimura K, Asato R, et al. Posterior lobe of the pituitary in diabetes insipidus: MR findings. *J Comput Assist Tomogr* 1987;11:221-225
 10. Kucharczyk J, Kucharczyk W, Berry I, et al. Histochemical characterization and functional significance of the hyperintense signal on MR images of the posterior pituitary. *AJNR* 1988;9:1079-1083
 11. Gudinchet F, Brunelle F, Barth MO, et al. MR imaging of the posterior hypophysis in children. *AJNR* 1989;10:511-514
 12. Billenstein DC, Leveque TF. The reorganization of the neurohypophyseal stalk following hypophysectomy in the rat. *Endocrinology* 1955;56:704-717
 13. Sloper JC, Adams CWN. The hypothalamic elaboration of posterior pituitary principle in man. Evidence derived from hypophysectomy. *J Pathol* 1956;72:587-602
-

Books Received

Receipt of books is acknowledged as a courtesy to the sender. Books considered to be of sufficient interest will be reviewed as space permits.

MRI Atlas of the Brain. By William G. Bradley and Graeme Bydder. New York: Raven, 363 pp., 1990. \$125

The Pain Clinic Manual. Edited by Stephen E. Abram. Philadelphia: Lippincott, 256 pp., 1990. \$29.50

Management of Facial, Head and Neck Pain. By Barry C. Cooper and Frank E. Lucente. Philadelphia: Saunders, 368 pp., 1990. \$75

Coronary and Cerebral Vascular Disease. A Practical Guide. By Loren A. Rolak and Roxann Rokey. New York: Futura, 377 pp., 1990. \$52

Intraoperative Ultrasound Imaging in Neurosurgery. Comparison with CT and MR. By Ludwig M. Auer and Vera Van Velthoven. New York: Springer-Verlag, 171 pp., 1990. \$98

Interventional Ultrasound. Edited by John P. McGahan. Baltimore: Williams & Wilkins, 274 pp., 1990. \$59.50

Myotonic Dystrophy, 2nd ed, vol. 21. By Peter S. Harper. Philadelphia: Saunders, 400 pp., 1990. \$80