

# Radiation Effects on Cerebral White Matter: MR Evaluation

Jay S. Tsuruda<sup>1,2</sup>  
 Keith E. Kortman<sup>1,3</sup>  
 William G. Bradley<sup>1,3</sup>  
 Donald C. Wheeler<sup>1</sup>  
 William Van Dalsem<sup>1</sup>  
 Thomas P. Bradley<sup>1</sup>

The purpose of this study was to evaluate the white-matter changes associated with cranial radiation by MR imaging. The MR scans of 95 patients receiving conventional external beam radiation for a wide variety of central nervous system tumors were reviewed. Moderately T2-weighted spin-echo images with a 2000-msec repetition time and 56-msec-echo time were analyzed for white-matter abnormalities without knowledge of the patient's history. These were correlated with radiation dose, port, and time interval since completion of therapy, and then compared with an age-matched control group of 180 patients with nonirradiated, space-occupying, intracranial lesions. Radiation-related lesions were characterized as symmetric, high-signal foci in the periventricular white matter. Relative sparing of the posterior fossa, basal ganglia, and internal capsules was noted. In patients older than 20 years, these changes paralleled those seen in ischemia but were more prevalent ( $p < .005$ ). In 25 patients with sequential MR scans, these findings remained stable. In those patients with limited treatment fields, for example, pituitary adenomas, no statistical differences were seen between radiation-treated and nontreated groups. Cerebral white-matter changes that mimic deep white-matter infarction are frequently seen in response to therapeutic radiation. There is a variable incidence of radiation effects, becoming more marked in older patients. MR interpretation must consider the neuropathologic consequences of therapeutic radiation, which include demyelination, microvascular occlusion, and blood-brain barrier breakdown.

The goal of therapeutic radiology is to provide a sufficient dose to treat central nervous system (CNS) tumors without affecting adjacent healthy tissue. As more therapeutic regimens have been implemented, long-term effects of neurotoxicity in the surviving patients have been recognized [1-3]. A spectrum of CNS changes has been noted on CT including atrophy, decreased attenuation of the deep cerebral white matter, and rarely focal, enhancing radionecrosis [4-7]. The findings of neurotoxicity have been correlated with clinical findings in both patients and clinical experiments [1]. More recently, similar findings of radiotherapy-related lesions of the brain have been described with MR [8-10]. Of interest, is the formation of deep white-matter periventricular foci characterized by prolonged T1 and T2 relaxation times compared with normal white matter [10] in a pattern suggestive of either demyelination or ischemia. Both can be identified readily by MR [11]. Since the natural prevalence and severity of focal periventricular abnormalities (e.g., deep white-matter infarction) increase with age [11, 12], these abnormalities must be considered before ascribing changes to radiotherapy. For this reason, a retrospective review of a large patient population was undertaken; MR was used to further characterize the effects of radiation on cerebral white matter with respect to age, prevalence, time of onset, and both the temporal and spatial stability of these lesions.

## Materials and Methods

MR imaging was performed using a Diasonics MT/S system operating at 0.35 T. Multiple-

This article appears in the May/June 1987 issue of *AJNR* and the July 1987 issue of *AJR*.

Received August 20, 1986; accepted after revision December 16, 1986.

Presented at the annual meeting of the American Roentgen Ray Society, Washington, DC, April 1986.

<sup>1</sup> NMR Imaging Laboratory, Huntington Medical Research Institutes, 10 Pico St., Pasadena, CA 91105. Address reprint requests to W. G. Bradley.

<sup>2</sup> Present address: Department of Radiology, University of California, San Francisco, CA 94143.

<sup>3</sup> Department of Radiology, Huntington Memorial Hospital, Pasadena, CA 91105.

*AJNR* 8:431-437, May/June 1987

0195-6108/87/0803-0431

© American Society of Neuroradiology

slice spin-echo scans were performed with a repetition time (TR) of 2000 msec and an echo time (TE) of 28 and 56 msec. Four excitations were used. Axial images were obtained in the majority of patients (90%) in both the therapeutic and control groups. The remainder had coronal studies only. In selected patients, additional images were obtained with a TR of 500 and/or 1000 msec in either the axial, sagittal, or coronal plane; however, these images were not included in this study. The acquisition matrix was 128 × 128, corresponding to a spatial resolution of 1.7 mm. Slice thickness was 7 mm with a 3-mm gap between sections. In two patients, an axial study was performed with a 256 × 256 matrix (0.95-mm spatial resolution) and 10-mm contiguous sections having a TR of 2000 msec and a TE of 30 and 60 msec. The images were graded for white-matter abnormalities as described below.

**Radiation Therapy Group**

We reviewed retrospectively 95 patients imaged between May 1983 and April 1986 who had received external beam-radiation therapy. All patients received conventional therapy except for five patients who were treated with charged-particle radiation or iridium brachytherapy. Patients who received only interstitial implant therapy were not included in this study. In each case, the estimated radiation dose, fractionation schedule, and prior systemic chemotherapy were noted. A wide variety of CNS tumors was represented, including gliomas of all grades, meningiomas, pituitary adenomas, lymphoproliferative disorders, and metastases (Fig. 1).

The therapeutic group was subdivided into six different age subgroups (Fig. 2). The average time interval between the MR scan and the completion of radiation therapy in the age subgroups between 20 and 59 years was 38 months. This time interval was less in the <20-year subgroup (18 months) and greater in the >60-year subgroup (71 months).

The estimated radiation dose and percentage of patients in each age subgroup with a history of previous chemotherapy are shown in Figures 3 and 4, respectively. In six of the 95 patients, the history of prior systemic chemotherapy was not known; however, they were included in this study. This radiation therapy group (n = 95) excluded patients with other suspected causes of deep white-matter abnormalities such as intrathecal chemotherapy, obstructive hydrocephalus, periventricular extension of tumor, or evidence of prior or present shunt-tube placement.

**Control Group**

One hundred-eighty age-matched patients (30 in each age subgroup) with no history of radiation therapy were randomly selected

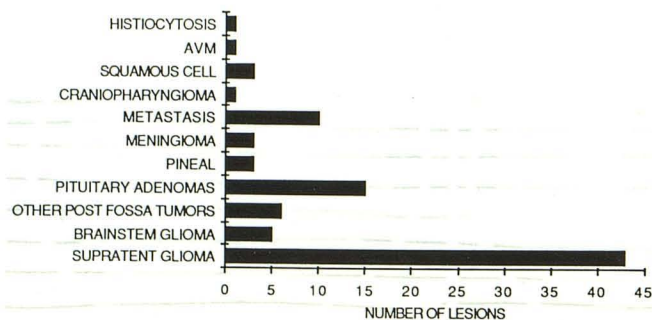


Fig. 1.—Lesion type and number treated in therapeutic group. AVM = arteriovenous malformation; post = posterior; supratent = supratentorial.

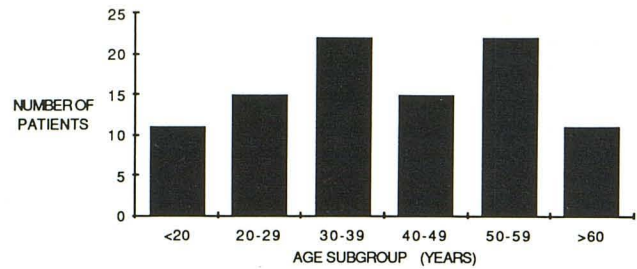


Fig. 2.—Distribution of therapeutic group into age subgroups.

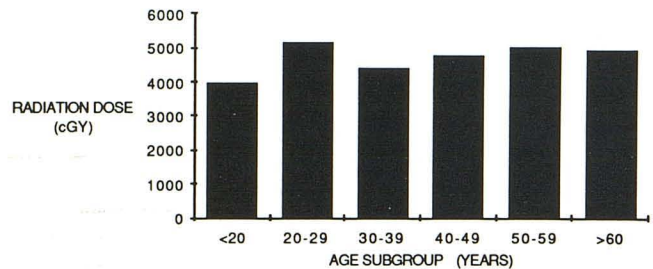


Fig. 3.—Estimated radiation dose in each age subgroup.

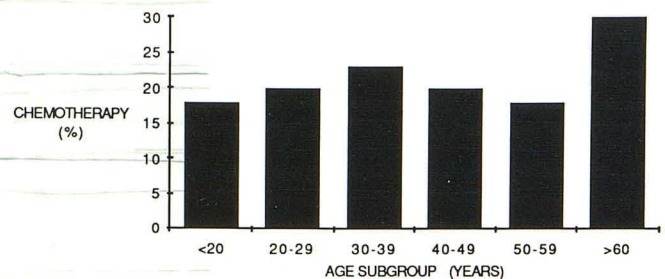


Fig. 4.—Percentage of patients who received systemic chemotherapy in each age subgroup. Patients treated with intrathecal chemotherapy were not included in this study.

as the control group. All patients had either benign or malignant intracranial lesions, which included gliomas of all grades (37%), neurinomas (10%), pituitary adenomas (9%), metastases (9%), arachnoid cysts (8%), arteriovenous malformations (6%), meningiomas (5%), empty sellae (3%), abscess (1%), miscellaneous tumors (9%) (including tuberous sclerosis, pineal region tumor, osteoma, cranio-pharyngioma, glomus jugulare, hemangioblastoma, epidermoid, lipoma), and unknown (3%). As with the radiation therapy group, patients with other possible causes of deep white-matter changes were excluded from the study.

**MR Review**

The MR studies from both groups were reviewed retrospectively by two observers without knowledge of age, gender, or prior radiation therapy. The images were then graded on a 0-4 scale for high-intensity changes involving the white matter in nine separate areas: frontal horn tip, occipital horn tip, lateral aspect of ventricular body, lateral aspect of occipital/temporal horns, centrum semiovale, basal

ganglia, internal capsules, brainstem, and cerebellum. Zero indicated the absence of intensity change compared with normal white matter, and 4 indicated extensive, confluent white-matter abnormalities. Both hemispheres were graded. The actual site of tumor involvement, the immediately surrounding edema, and postoperative gliosis were not included.

The patient's scores including mean, standard deviation, and standard error for each area were then tabulated into either the control or radiotherapy group and respective age subgroups. Statistical significance between similar age subgroups of the control vs radiotherapy groups was determined by an unpaired, two-sample Student's *t* test. The relationship between each age subgroup within either the control or radiotherapy group was determined from second-order polynomial regression analysis and resulting correlation coefficients.

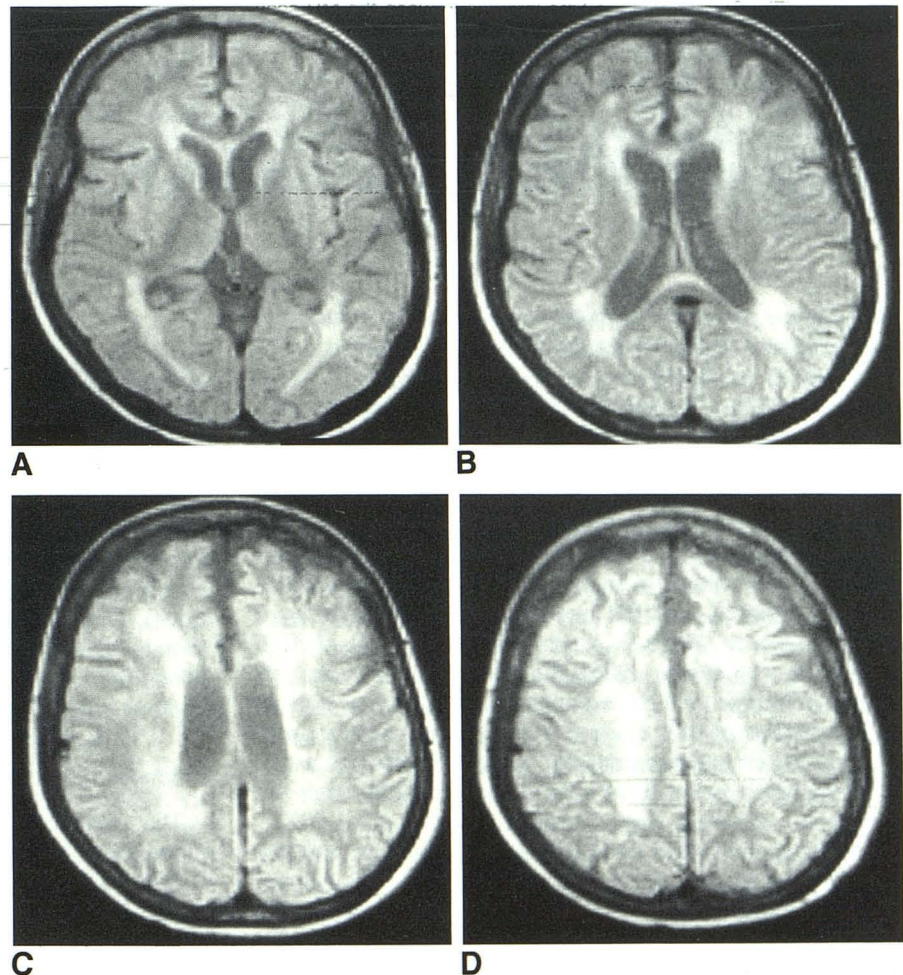
## Results

Radiation-related lesions were characterized as high-signal foci in the periventricular, supratentorial white matter. The areas most often involved were adjacent to the frontal horn tip, occipital horn tip, lateral aspect of the ventricular body, lateral aspect of the occipital and temporal horns, and centrum semiovale. Relative sparing of the brainstem, cerebellum,

internal capsules, and basal ganglia was noted (Fig. 5). This involvement tended to be symmetric and equally severe in the contralateral hemisphere and was remote from either the tumor or the operative site. There was no mass effect associated with even the highest grade (4) lesions (Fig. 6).

From a qualitative standpoint, any patient in the radiation therapy group with a score of one or greater in two separately graded areas of the periventricular white matter was suspected of having radiation-related changes. No patients under 20 years old were considered to have radiation-related changes. However, in the remainder of the age subgroups the number of suspected patients was as follows: 20–29 years, three patients (20%); 30–39 years, nine patients (41%); 40–49 years, five patients (33%); 50–59 years, 10 patients (45%); and older than 60 years, nine patients (82%). When these supratentorial periventricular white-matter changes were compared in each age subgroup, statistically significant ( $p < .005$ ) differences were noted between the radiotherapy and control groups except in patients younger than 20 years old (Table 1). Areas of the brainstem, cerebellum, internal capsule, and basal ganglia showed no significant difference between the radiotherapy and control-age subgroups.

The severity of deep white-matter changes in both the



**Fig. 5.**—Series of T2-weighted (SE 2000/28) axial images in 61-year-old woman who, 11 months before this study, was treated with 5000 cGy by using 14- by 17-cm bilateral ports fractionated over 38 days. Bilateral and symmetric distribution of periventricular white-matter foci without mass effect. Sparing of basal ganglia, internal capsules, and posterior fossa (not shown) was noted.

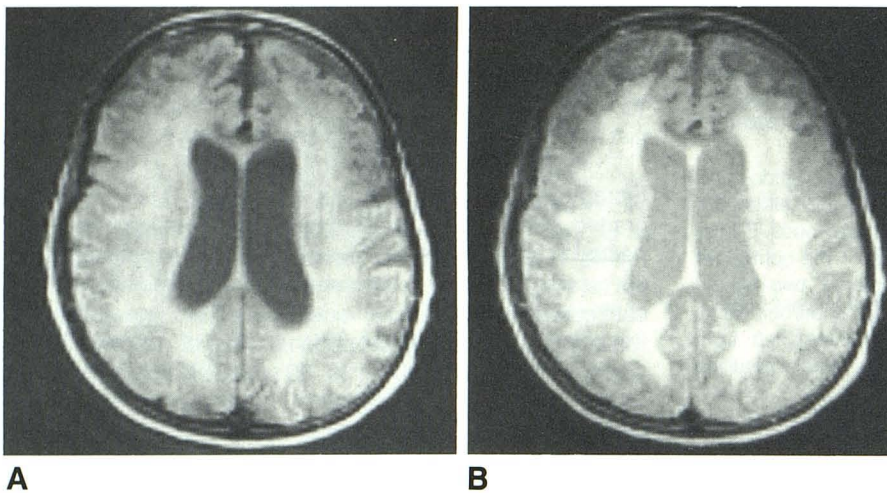


Fig. 6.—SE 2000/28 (A) and SE 2000/56 (B) images in 70-year-old woman treated for metastatic lung carcinoma with whole-brain radiation, 3000 cGy, 2 years 8 months before this study. There are extensive (grade 4) periventricular white-matter changes and associated atrophy.

TABLE 1: Supratentorial Periventricular White-Matter Changes: Radiation vs Control Groups

Age Subgroup	Mean Score ± SEM		Significance
	Radiotherapy Group	Control Group	
<20	0.09 ± 0.02	0.03 ± 0.01	NS
20-29	0.20 ± 0.05	0.02 ± 0.007	<i>p</i> < .005
30-39	0.41 ± 0.05	0.06 ± 0.01	<i>p</i> < .005
40-49	0.60 ± 0.09	0.06 ± 0.01	<i>p</i> < .005
50-59	0.87 ± 0.10	0.12 ± 0.02	<i>p</i> < .005
>60	1.64 ± 0.16	0.23 ± 0.03	<i>p</i> < .005

Note.—Scores are based on a 0-4 scale: 0 = no intensity change relative to normal white matter; 4 = extensive, confluent white-matter abnormalities. NS = not significant.

radiotherapy and control groups was found to increase with advancing age (Table 1). Nonlinear regression analysis of the data (Fig. 7) resulted in the second-order polynomial equations:  $y = 0.23 - 0.158x + 0.063x^2$  ( $r = .94$ ) for the radiotherapy group and  $y = 0.07 - 0.049x + 0.012x^2$  ( $r = .88$ ) for the controls, where  $x$  represents age and  $y$  is the degree of white-matter changes.

Within the radiotherapy group, 29 of 95 had two or more sequential scans. Nine patients (31%) had sequential studies that were interpreted to have positive findings attributed to radiation therapy. In all but two patients, the findings were noted to remain stable over an average interval of 10.5 months. In 15 patients, (52%) the first MR study was performed before or during the course of radiotherapy with an average follow-up MR study 6 months after completion of therapy. In two of these patients, definite new lesions within the deep white matter were noted 7 and 9 months after the completion of therapy (Figs. 8 and 9).

Sixteen patients had limited treatment fields for pituitary tumors. The mean age was 40.5 years and the average interval between completion of radiotherapy and the MR study was 4.6 years. The estimated average radiation dose to the sella was 4234 cGy (4234 rad). From the 180 control patients,

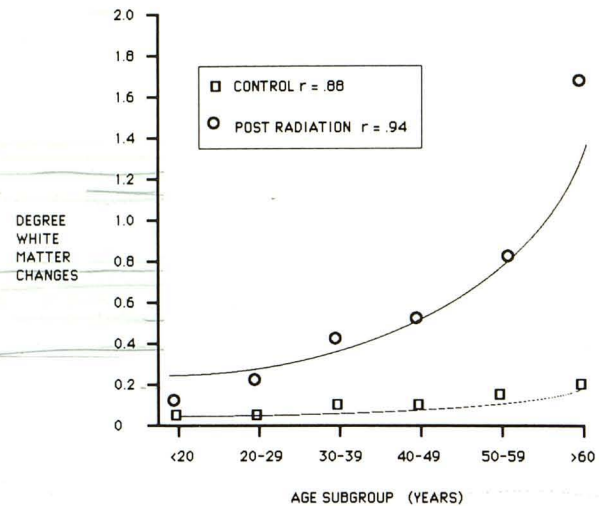


Fig. 7.—Comparison between average degree of supratentorial white-matter changes with advancing age for both therapeutic and control groups obtained from data in Table 1. Connecting curves and correlation values were computed from second-order polynomial regression analysis (see text).

22 (mean age, 48.6 years) had sellar region abnormalities including newly diagnosed adenomas (60%), empty sellae (27%), and adenomas treated by surgery or bromocriptine therapy (13%). When all graded areas were compared between the radiotherapy and control groups for patients with pituitary lesions, no statistical differences were seen.

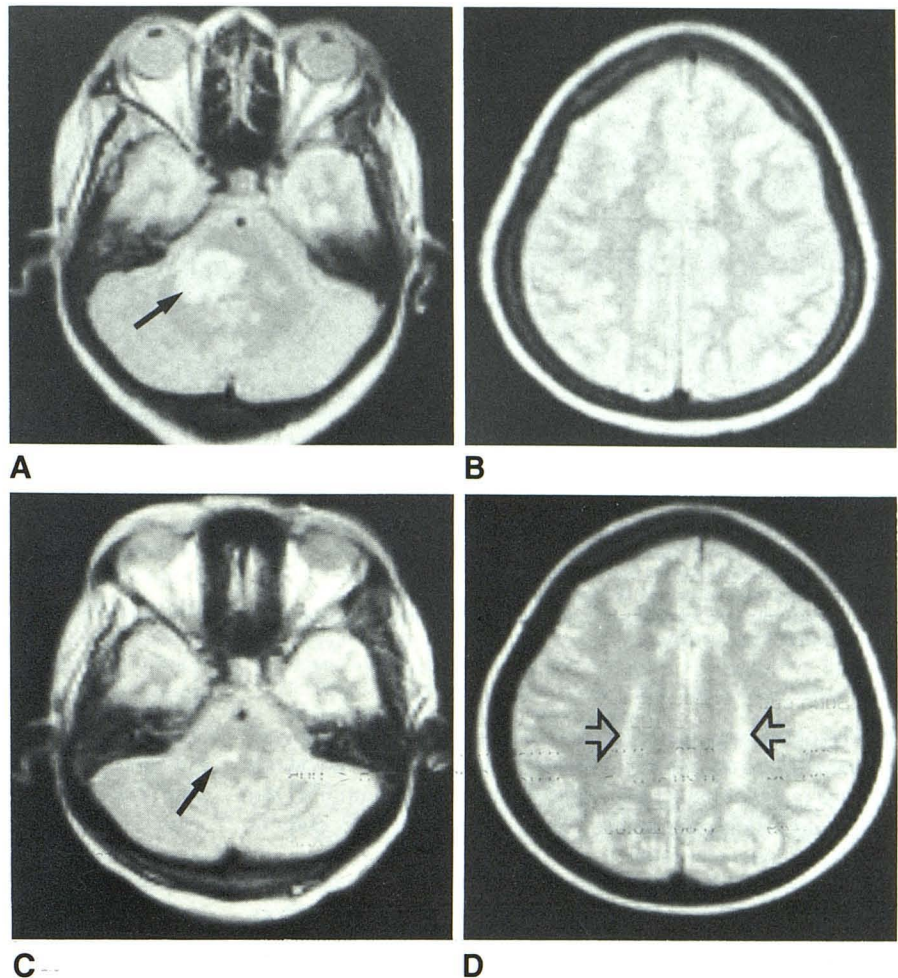
**Discussion**

The delayed pathophysiologic changes encountered in brain tissue as a response to radiotherapy have been investigated thoroughly, and several target sites have been implicated. First, delayed capillary endothelial cell damage may occur leading to breakdown of the blood-brain barrier with resulting vasogenic edema [13]. This edema has been de-

Fig. 8.—SE 2000/56 images. Evolving radiation-related white-matter changes in 55-year-old woman.

A and B, Before radiotherapy. Posterior fossa glioma (arrow) and normal white matter in centrum semiovale.

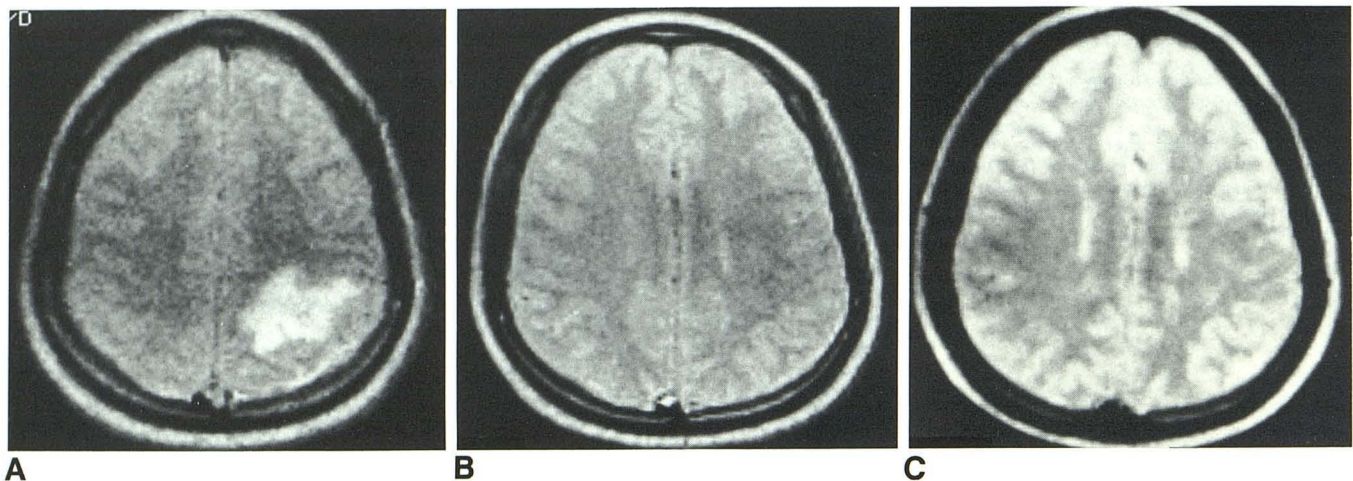
C and D, 7 months after completion of radiotherapy. Interval tumor response (solid arrow) and formation of additional supratentorial white-matter changes (open arrows) remote from tumor site.



scribed after necropsy as occurring remote from the site of primary radiation exposure and results in impaired CSF circulation due to elevated CSF pressures. Cerebral blood flow may also be reduced [13]. Heterogeneous endothelial hyperplasia [14], fibrinoid necrosis of penetrating arterioles within the white matter [4, 9], and morphologic changes suggestive of atherosclerosis involving large-sized arteries have been noted [13]. Animal studies have shown that focal demyelination occurs, with associated proliferation of glial elements and mononuclear cells weeks or months after completion of radiotherapy [13]. In addition, white matter may develop small necrotic foci [13], vacuolation [3, 9], and petechial hemorrhage [15] months to several years after radiotherapy. Ventriculomegaly and widening of the sulci due to atrophy is commonly noted on both CT and gross pathology [7, 9, 13]. Depending on the severity of these changes, patient age, and total radiation dose, these lesions may partially resolve, stabilize, or progress over a protracted course of several months to several years, leading to widespread, potentially fatal brain destruction characterized by coagulation necrosis [7, 16]. When this stage is reached, clinical symptoms may suggest a recurrent intracranial mass, and CT may show an enhancing mass [5–7], which is difficult to distinguish from recurrent or

residual cancer. This latter form of extensive coagulation necrosis has been called "radiation necrosis" or "late delayed reaction" [15]. To our knowledge, none of the patients in the radiotherapy group had biopsy-proven or clinically suspected radiation necrosis; however, this distinction cannot be made on the basis of MR findings alone [10].

Our MR findings agree with previous studies [8–10]. The pattern of involvement is symmetric, with involvement of the deep white matter. These abnormalities are often remote from the tumor site (which presumably received the highest radiation dose). Since the majority of the patients were alive, histologic correlation was not performed; however, our MR findings concur with the expected pathophysiologic changes previously described. Prolongation of T1 and T2 relaxation values were noted, with resulting MR intensity and distribution similar to either multiple sclerosis plaques or deep white-matter infarcts. This is understandable since the known histologic findings of white-matter radiation changes are demyelination, microvascular occlusion, and vasogenic edema. These white-matter changes have a variable delay of onset [13] measured in weeks to months. In two of 15 patients with sequential scans obtained during and after radiotherapy, radiation-related lesions appeared 7 and 9 months after com-



**Fig. 9.**—Sequential SE 2000/56-images in 28-year-old man with left parietal testicular carcinoma metastasis.  
**A,** Before combined systemic chemotherapy and radiotherapy. Radiotherapy consisted of opposed 18- by 12-cm whole-brain ports for 4000 cGy and opposed lateral coned-down ports for an additional 1000 cGy.  
**B,** 4 weeks later, MR study is essentially normal.  
**C,** Follow-up study 8 months later shows new, faint periventricular high-intensity lesions that can be regarded as definite new findings when compared with previous examination.

pletion of therapy. The remainder of these 15 patients showed no new white-matter abnormalities; however, the follow-up interval may not have been sufficiently long (6 months). In the future, additional prospective studies are needed to document these changes accurately.

In our experience, the pattern of involvement mimics the changes seen in older patients and in patients with risk factors for cerebral vascular disease. There is a greater tendency for these periventricular lesions to be more confluent, as seen with deep white-matter infarction, than more focal, as seen with multiple sclerosis (Kortman KE, Bradley WG, Rauch RA, et al., unpublished data). Morphologically, the deep white-matter changes in both the radiation and control groups had similar MR patterns. Both groups showed an increase in changes with advancing age, but these occurred at a greater rate in the radiotherapy group. This raises the possibility that treating "at-risk" middle-aged and elderly patients with radiotherapy tends to accelerate the normal, involutinal white-matter changes expected with advancing age, which are presumably caused by small, often clinically silent infarcts. In Table 1, it should be noted that the mean changes of the entire age group, based on a 0- to 4-point scale, is quite low even with advancing age. This directly reflects the variable incidence of radiation-related changes in patients who are close in age. Even in the advanced age groups, there are patients who will have minimal or no-white matter changes after therapy. This variable incidence of radiation changes has also been experimentally demonstrated on monkeys of similar ages [13].

Although no attempt was made to correlate the degree of white-matter changes with the presence of adverse clinical effects, we did note anecdotally that the majority of patients, without evidence of tumor recurrence or extension, showed variable clinical expression. Patients ranged from being

asymptomatic to having signs of neurotoxicity "characterized by varied degrees of irreversible dementia, confusion, ataxia, and psychomotor retardation" [1]. This lack of correlation has also been described in elderly individuals with leukoencephalopathy as a response to normal and pathologic aging [17-19]. In addition, extensive radiation changes of the deep white matter may potentiate the effects of an underlying disorder such as Alzheimer's disease or multiinfarct dementia [17, 19].

We are unable to explain the lack of statistical increase in deep white-matter changes in the youngest age group. It has been reported previously that the age of the recipient at the time of radiotherapy may determine the severity of parenchymal damage, with the most significant changes seen in younger patients [13]. A follow-up interval of less than 2 years and a higher percentage (45%) of posterior fossa tumors may have biased the results in the under-20 subgroup.

The stability of the MR findings confirms the histologic results in experimental models [13]. Although it has been postulated that remyelination and reversal of microvascular changes may occur [4], we were unable to document this by MR over the time interval covered by this study.

Since cerebral edema has been reported to lower brain resistance to radiation injury [4, 13, 20], it could be predicted that peritumoral edema would be the most sensitive site. Unfortunately, this could not be verified with MR since MR signal alterations cannot discriminate between tumor edema and white-matter radiation changes. As a result, these regions were excluded from the grading process.

We are uncertain of the influence of systemic chemotherapy, either alone or in combination with radiotherapy, on the MR appearance of the deep white matter compared with radiotherapy alone. A significant percentage of these patients in all age subgroups received combined therapy, and this may

have influenced our conclusions. This is especially true in the subgroup older than 60 and may partially account for the greater degree of white-matter changes shown in Figure 7. In a recent study, the MR findings of leukoencephalopathy were noted in five patients with clinical signs of neurotoxicity treated with combined therapy [1]; however, no comparison was made with patients who were treated by radiation alone. In another study of brain radiation lesions evaluated by MR in 55 patients [10], there was no mention of chemotherapy being administered to patients with positive findings.

In the pituitary tumor subgroup, we were able to select a large population with limited treatment fields for statistical analysis. Although, radiation necrosis has been described in the temporal and frontal lobes, hypothalamus, thalamus, basal ganglia, cerebral white matter, and brainstem in patients with pituitary adenomas [5, 15], these findings were not present in any of our cases and no statistical differences were seen compared with the age-matched controls.

In conclusion, cerebral white-matter changes are often seen as a delayed response to therapeutic radiation. The pattern of involvement is symmetric and mimics deep white-matter infarction. There is a variable incidence of radiation effects that become more marked in older patients. MR interpretation must consider the neuropathologic consequences of therapeutic radiation including demyelination, microvascular occlusion, and blood-brain barrier breakdown and may serve as a useful adjunct in assessing neurotoxicity in these long-term survivors.

#### ACKNOWLEDGMENTS

We thank Gail Thompson for help in manuscript preparation; Terry Andruess, Jay Mericle, and Leslee Watson for technical help; and Richard A. Yadley, Irwin Grossman, and Michael R. Kadin for comments.

#### REFERENCES

- Frytak S, Earnest F, O'Neill BP, Lee RE, Creagan ET, Trautman JC. Magnetic resonance imaging for neurotoxicity in long-term survivors of carcinoma. *May Clin Proc* 1985;60:803-812
- Rottenberg DA, Horten B, Kim J, Posner JB. Progressive white matter destruction following irradiation of an extracranial neoplasm. *Ann Neurol* 1980;8:76-78
- Wang A, Skias DD, Rumbaugh CL, Schoene WC, Zamani A. Central nervous system changes after radiation therapy and/or chemotherapy: correlation of CT and autopsy findings. *AJNR* 1983;4:466-471
- Groothuis DR, Vick N. Radionecrosis of the central nervous system: the perspective of the clinical neurologist and neuropathologist. In: Gilbert HA, Kagan AR, eds. *Radiation damage to the nervous system*. New York: Raven, 1980:93-106.
- Fukamachi A, Wakao T, Akai J. Brain stem necrosis after irradiation of pituitary adenoma. *Surg Neurol* 1982;8:343-350
- Safadari GH, Fuentes J-M, Dubois J-B, Alirezai M, Castan P, Vlahovitch B. Radiation necrosis of the brain: time of onset and incidence related to total dose and fractionation of radiation. *Neuroradiology* 1985;27:44-47
- Safadari GH, Boluix B, Gros C. Multifocal brain radionecrosis masquerading as tumor dissemination. *Surg Neurol* 1984;21:35-41
- Bydder GM, Penneck JM, Steiner RE, Orr JS, Bailes DR, Young IR. The NMR diagnosis of cerebral tumors. *Magnetic Resonance Med* 1984;1:5-29
- Curnes JT, Laster DW, Ball MR, Moody DM, Witcowski RL. Magnetic resonance imaging of radiation injury to the brain. *AJNR* 1986;7:389-394
- Dooms GC, Hecht S, Brant-Zawadzki M, Berthiaume Y, Norman D, Newton TH. Brain radiation lesions: MR imaging. *Radiology* 1986;158:149-155
- Bradley WG, Waluch V, Brant-Zawadzki M, Yadley RA, Wycoff RR. Patchy, periventricular white matter lesions in the elderly: a common observation during NMR imaging. *Noninvas Med Imag* 1984;1:35-41
- Brant-Zawadzki M, Fein F, Van Dyke C, Kiernan R, Davenport L, de Groot J. Magnetic resonance imaging of the aging brain: patchy white matter lesions and dementia. *AJNR* 1985;6:675-682
- Cavenes WF. Experimental observations: delayed necrosis in normal monkey brain. In: Gilbert HA, Kagan AR, eds. *Radiation damage to the nervous system*. New York: Raven, 1980:1-38
- Denekamp J, Folwer JF. Cell proliferation kinetics and radiation therapy. In: Becker FE, ed. *Cancer—a comprehensive treatise*. New York: Plenum, 1977:101-137
- Sheline GE. Irradiation injury of the human brain: a review of clinical experience. In: Gilbert HA, Kagan AR, eds. *Radiation damage to the nervous system*. New York: Raven, 1980:39-58
- Rizzoli HU, Pagnanelli DM. Treatment of delayed radiation necrosis of the brain. *J Neurosurg* 1984;60:5589-5594
- George AE, de Leon MJ, Gentes CI, et al. Leukoencephalopathy in normal and pathologic aging: 1. CT of brain lucencies. *AJNR* 1986;7:561-566
- George AE, de Leon MJ, Kalnin A, Rosner L, Goodgold A, Chase N. Leukoencephalopathy in normal and pathologic aging: 1. MRI of brain lucencies. *AJNR* 1986;7:567-570
- Lotz PR, Ballinger WE, Quisling RG. Subcortical arteriosclerotic encephalopathy: CT spectrum and pathologic correlation. *AJNR* 1986;7:817-822
- Burger PC, Mahaley MS, Dudka L, Vogel FS. The morphologic effects of radiation administered therapeutically for intracranial gliomas. A postmortem study of 25 cases. *Cancer* 1979;44:1256-1272